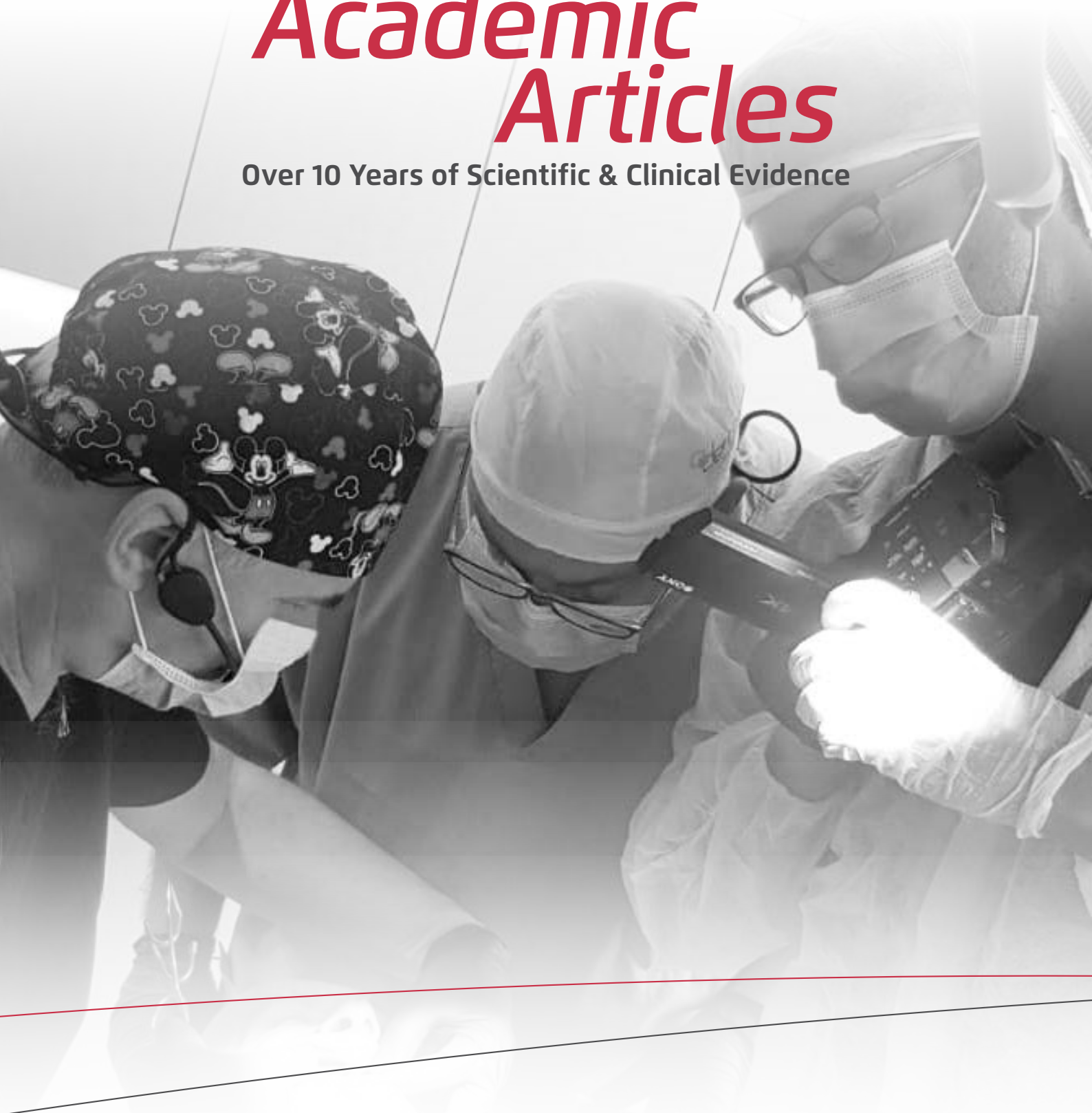



Academic Articles

Over 10 Years of Scientific & Clinical Evidence



norismedical.com

Noris Academy

A PLATFORM FOR LEARNING AND SHARING KNOWLEDGE

Hands-On Models Courses • Cadaver & Live Patient Courses

Webinars & On-Line Sessions • Mentoring Program

Cases Studies • Academic Articles




Table of Contents

Zygomatic Implants

Maxillary resection for cancer, zygomatic implants insertion, and palatal repair as single-stage procedure: report of three cases	3-11
A new surgical and technical approach in zygomatic implantology	12-21
Treatment of severe atrophic maxilla with zygomatic implants	22-26
A Novel Guided Zygomatic and Pterygoid Implant Surgery System: A Human Cadaver Study on Accuracy	27-46
Three-Dimensional Technology Applications in Maxillofacial Reconstructive Surgery: Current Surgical Implications	47-64
Platform switch hybrid zygoma implants improve prosthetics and marginal bone protection after extra-sinus placement	65-71
Clinical outcome of 302 zygomatic implants in 110 patients with a follow-up between 6 months and 7 years	72-80
Zygomatic implant survival in 9 ectodermal dysplasia patients with -3.5 to -7year follow-up	81-87
Insertion of Zygomatic Implants with a Technical Modification of the Extrasinus Protocol: A Retrospective Case Series	88-95
Accuracy of Zygomatic Implant Placement Using a Full Digital Planning and Custom-Made Bone-Supported Guide: A Retrospective Observational Cohort Study	96-107

Surface treatment of Dental Implants

Comparison of Implant Stability Quotient of sand blasted large-grit acid etched (SLA) & biological calcium phosphate surface treated (RBM) dental implants using Resonance Frequency Analysis - A Parallel Arm Double Blinded Randomized Controlled Trial	110-118
--	---------

Prevention of Peri Implantitis

A new system of implant abutment connection: how to improve a two piece implant system sealing	120-125
A Comparative Evaluation of Height of Interdental Papilla around Noris Tuff TT and Nobel Active Dental Implants placed in Maxillary Anterior Region	126-130

Clinical challenges

A new spiral dental implant: a tool for oral rehabilitation of difficult cases	132-137
Evaluation of patient satisfaction and masticatory performance in mandiblesingle implant-assisted overdenture	138-143

Zygomatic Implants

YOUR FUTURE
IN DENTAL HEALTHCARE



Maxillary resection for cancer, zygomatic implants insertion, and palatal repair as single-stage procedure: report of three cases

Pietro Salvatori^{1*}, Antonio Mincione², Lucio Rizzi², Fabrizio Costantini¹, Alessandro Bianchi¹, Emma Grecchi³, Umberto Garagiola⁴ and Francesco Grecchi⁵

Abstract

Background: Oronasal/antral communication, loss of teeth and/or tooth-supporting bone, and facial contour deformity may occur as a consequence of maxillectomy for cancer. As a result, speaking, chewing, swallowing, and appearance are variably affected. The restoration is focused on rebuilding the oronasal wall, using either flaps (local or free) for primary closure, either prosthetic obturator. Postoperative radiotherapy surely postpones every dental procedure aimed to set fixed devices, often makes it difficult and risky, even unfeasible. Regular prosthesis, tooth-bearing obturator, and endosseous implants (in native and/or transplanted bone) are used in order to complete dental rehabilitation. Zygomatic implantology (ZI) is a valid, usually delayed, multi-staged procedure, either after having primarily closed the oronasal/antral communication or after left it untreated or amended with obturator.

The present paper is an early report of a relatively new, one-stage approach for rehabilitation of patients after tumour resection, with palatal repair with loco-regional flaps and zygomatic implant insertion: supposed advantages are concentration of surgical procedures, reduced time of rehabilitation, and lowered patient discomfort.

Cases presentation: We report three patients who underwent alveolo-maxillary resection for cancer and had the resulting oroantral communication directly closed with loco-regional flaps. Simultaneous zygomatic implant insertion was added, in view of granting the optimal dental rehabilitation.

Conclusions: All surgical procedures were successful in terms of oroantral separation and implant survival. One patient had the fixed dental restoration just after 3 months, and the others had to receive postoperative radiotherapy; thus, rehabilitation timing was longer, as expected. We think this approach could improve the outcome in selected patients.

Key words: Maxillectomy, Zygomatic implant, Tumour resection, Maxillofacial, Carcinoma, Maxillary reconstruction.

Backgrounds

Major defects following maxillectomy for cancer include oronasal/antral communication, loss of teeth and/or tooth-supporting bone, and facial contour deformity.

As a result, speaking, chewing, swallowing, and appearance are variably affected. Priority of restoration is focused on rebuilding the oronasal wall, by means either of flaps (local or free), either prosthetic obturator.

Dental rehabilitation might follow by means of regular prosthesis, toothbearing obturator, and endosseous implants (in native and/or transplanted bone). Zygomatic implantology (ZI) has been first mentioned by Aparicio et al. in 1993 [1], then proposed by Brånemark [2] in order to overcome bone availability after maxillectomy.

Commonly, this option is offered as delayed procedure after tumour resection. Later, ZI has been employed in non-neoplastic, severely atrophic maxilla [3–11].

The present paper is an early report of a relatively new, one-stage approach providing for tumour resection, palatal repair with loco-regional flaps, and zygomatic implant insertion in three patients. Advantages are concentration of surgical procedures, reduced time of rehabilitation, and patient discomfort.

* Correspondence: pietro.salvatori@fastwebnet.it

¹Department of Otorhinolaryngology-H&N Surgery, Humanitas San Pio X Hospital, Via F. Nava 31, 20159 Milan, Italy

Full list of author information is available at the end of the article

Case presentation

Three patients have been operated on for malignant neoplasms affecting the maxilla at the Legnano Hospital, Italy, and at the Humanitas San Pio X, Italy. Written informed consent was obtained from each patient, and the study protocol conformed to the ethical guidelines of the World Medical Association Declaration of Helsinki—Ethical Principles for Medical Research Involving Human Subjects. Surgical plan was based on tumour resection, palatal repair, and zygomatic implant insertion in view of fixed dental rehabilitation. CT scan for zygomatic bone evaluation was part of working up. No virtual planning of resection or of implant insertion was considered, and fixture placement was performed under direct vision, enhanced by simple resin guide simulating the resected dental arch. All patients were dentate (natively or after fixed restoration) and resulted partially dentate after tumour resection, so fitting class IIA defect classification, according to Pellegrino et al. [12]. Osteotomies were achieved with saw, burs, and piezosurgery. Frozen sections were obtained in order to demonstrate clean margins.

The zygomatic bone was adequately exposed. Implants from Noris Medical Ltd. (Nesher, Israel) were chosen. The working, threaded part of the implant is 13 mm long, while the remaining, fully smooth shaft has 4-mm diameter and variable length. In all, length ranges from 35 to 57.5 mm. Implant drilling was performed using both straight and angled handpieces. The fixtures were placed at 35 rpm for the 2/3 of the apical and manually for the most coronal 1/3 working part. Palatal-alveolar repair was attained with soft tissue, local flaps: these were also wrapped around the implants. In order to obtain a durable watertight seal between oral and nasal antral cavities, implant uncovering and loading were planned to be deferred by 3 months.

CT scans and/or panoramic radiograph were taken to monitor implant healing. Screw-retained fixed prosthesis was considered for teeth replacement.

Patient no. 1

A 76-year-old gentleman suffering from lichenoid mucositis was operated on for verrucous carcinoma of the vestibular attached gingiva in the areas of 22 and 23, in 2013. The tooth 24 was missing, having been extracted elsewhere years before. Clear margins were obtained, and healing was uneventful. Then, the patient regularly attended follow-up examinations: on April 2015, a white, creamy discharge was noted from the gingiva covering the 24 socket. The gingiva was opened and the socket debrided. Histologic examination of the removed material was consistent with verrucous carcinoma. CT scan showed a radiolucent area involving the socket of 24 and the surrounding bone (Fig. 1). The neoplasm was staged T4 N0. The patient underwent partial maxillectomy involving the antral floor, the alveolar bone, and teeth 23 to 25. The tooth 26 had abnormal mobility, hence was extracted.

Two zygomatic implants (40 and 42.5 mm, respectively) were placed into the malar bone.

The buccal fat pad was harvested and moved to both repair the oroantral communication and wrap the implants (Fig. 2). The buccal mucosa was advanced over the buccal fat pad and implants and closed with single sutures. CT scan was taken after surgery (Fig. 3). Time was allowed for soft tissue healing, and after 3 months implants were uncovered, 45° abutments placed and a fixed, screw-retained prosthesis ended the rehabilitation (Fig. 4). To reduce direct loading on zygomatic fixtures, the prosthetic device was splinted mesially to 22 and distally to 27. After 1 year, the dental prosthetic restoration was unscrewed and zygomatic implant stability successfully checked (Fig. 5).

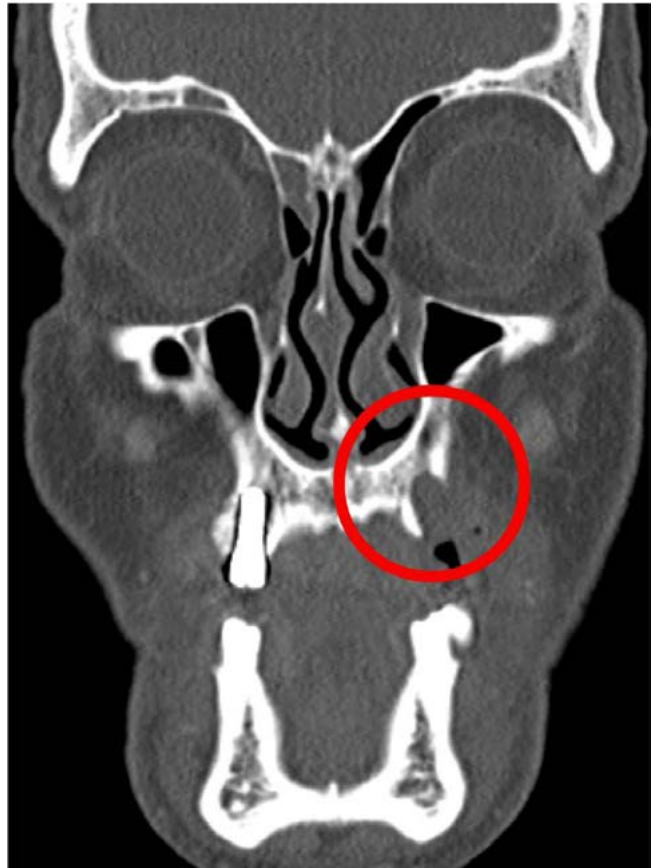


Figure 1

Pt no. 1. CT scan showing a radiolucent area involving the socket of tooth 24 and the surrounding bone.

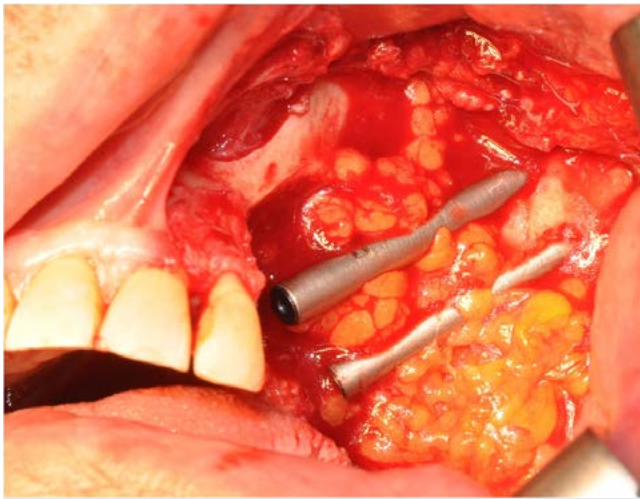


Figure 2

Pt no. 1. The buccal fat pad harvested and moved in order to repair the oroantral communication and to wrap the zygomatic implants

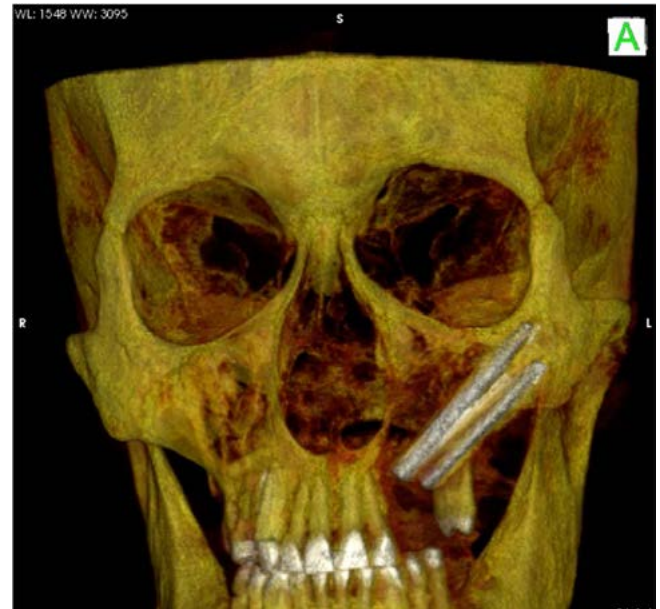

Figure 3

Pt no. 1. CT scan reconstruction showing zygomatic implant placement after maxillectomy

Patient no. 2

A 43-year-old lady bearing an adenoid cystic carcinoma of the left maxilla was referred for treatment. Clinical and radiologic examination led us to stage the tumour T4 N0 (Figs. 6 and 7). The patient underwent left extended maxillectomy (Fig. 8).

A prefabricated occlusal replica (Fig. 9) allowed the most correct insertion of two zygomatic implants (40 and 42.5 mm, respectively). Then, the left temporalis muscle flap was entirely raised and rotated to fill the defect and to wrap the implants (Fig. 10). The fascial side was stitched to the mucosal margins in order to separate the sino-nasal cavity from the oral one (Fig. 11). The postoperative period was uneventful, and care had been taken in order to contrast trismus since the surgery.

The final pathologic report alerted against perineural invasion, and some spotted margins close to the tumour. These data, together with the tumour nature and extension at presentation, led to address the patient to receive a full course of adrotherapy. Regrettably, the latter treatment carried some important sequelae (radionecrosis in the pterygoid region and trismus, mostly antalgic) that forced to delay dental rehabilitation. However, hyperbaric oxygen therapy and sequestrectomy granted the complete healing of radionecrosis and trismus improvement: implant stability was checked during this in-office surgery and appeared fully satisfactory, so did CT scan imaging. Pathologic examination did not reveal any relapsing disease.

Patient no. 3

A 65-year-old gentleman suffering from squamous cell carcinoma of the upper gingiva underwent right partial maxillectomy (Fig. 12). The lesion showed have arisen around three endosseous implants placed years before in the teeth 13, 14, and 15 areas. The CT scan did not demonstrate frank bone involvement, neither neck node extension (Fig. 13) nor distant metastases. Consequently, a large oroantral communication derived

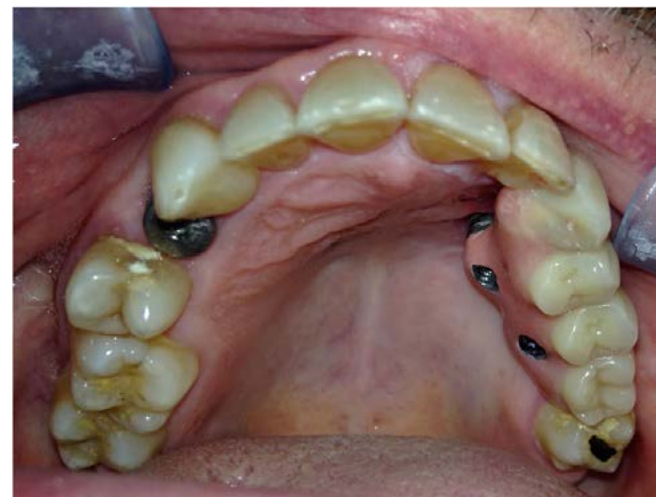

Figure 4

Pt no. 1. The final screw-retained prosthesis placed after 3 months

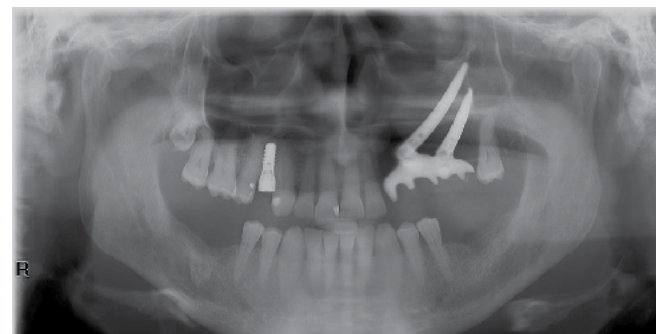

Figure 5

Pt no. 1. X-ray follow-up examination showing the final dental prosthetic rehabilitation

from tumour ablation (that had to include the three implants); the fat pad flap preoperatively planned was judged adequate after harvesting and actually used to close the defect. Compromised teeth 11 and 21 were also extracted and immediately replaced by two standard implants. A third standard, tilted implant was posed in the 13 area.

Finally, one zygomatic implant was inserted in order to emerge in the 16 area (Fig. 14).

Postoperative course was complicated by limited suture dehiscence, without oroantral fistula, and spontaneous healing was then reached adopting a conservative treatment (Figs. 15 and 16). Pathologic examination demonstrated clear margins in the sinus mucosa, but bone invasion upstaged the patient from cT2 to pT4, and then, adjuvant radiotherapy was advised. Soft tissues were allowed to recover from radiation upshots and the prosthetic timing was subsequently scheduled.

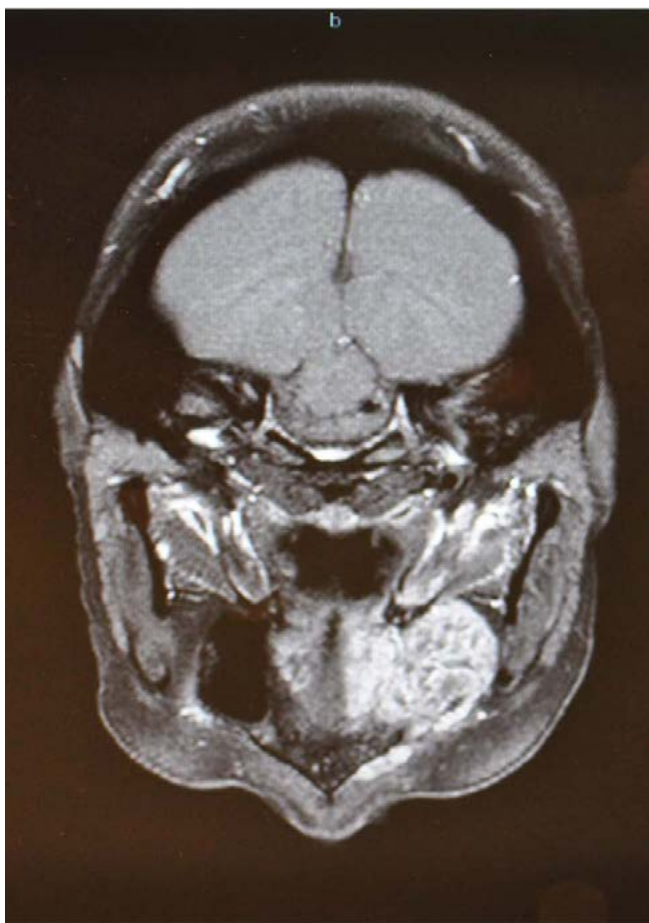

Figure 6
Pt no. 2. Transverse plane of the preoperative CT scan showing a radiopaque mass of the left maxilla

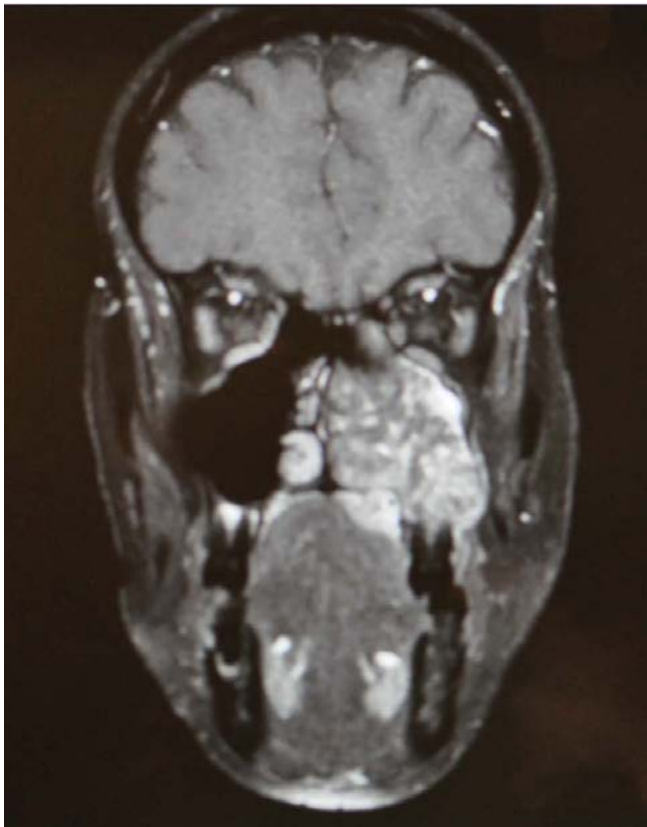


Figure 7
Pt no. 2. Coronal plane of the preoperative CT scan showing a radiopaque mass of the left maxilla

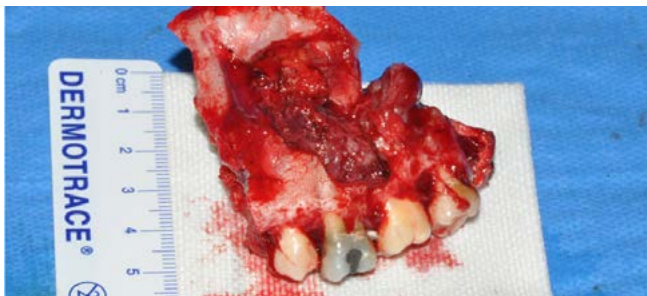


Figure 8
Pt no. 2. The extended portion of the left maxilla removed after maxillectomy

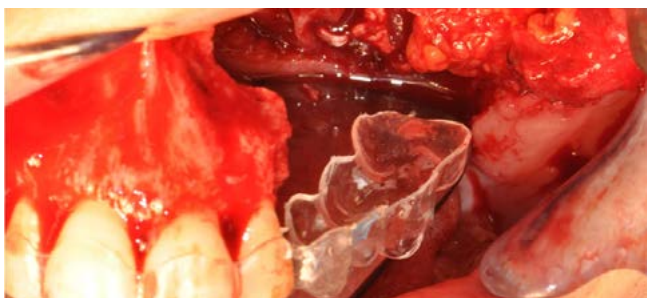


Figure 9
Pt no. 2. The prefabricated occlusal replica used for correct zygomatic implant emergence planning

Discussion

Neoplasms of the maxilla often require extensive surgery and adjuvant treatments: as a consequence, quality of life might result as heavily impaired.

Reconstructive surgery (immediate or delayed) allows anatomic and basic functionality restoration following maxillary tumour resection. Actually, the most important goal has to be achieved—as earlier as possible—is the repair of the natural barrier between oral and nasal/ antral cavities: options include free or local flaps and obturator.

Free flaps may either be harvested as single component, or as soft tissue and bone complex. Among the latter, fibula, iliac crest, and scapula are the most popular, with personal preference for the fibula flap. These composite auto-transplants allow both restoration of the oronasal/antral barrier and bone support for implants. Disease-related indications for composite free flaps include repair of large defects (2/3 of the palato-alveolar complex) and 3-D maxillary reconstruction. Their use implies large consumption of resources, yet patients' survival is quite rewarding [13]. In contrast, local and regional flaps are less demanding, but their use is restricted to more limited palato-alveolar defects (up to the midline). The temporalis muscle is the workhorse for repairing such defects, while buccal fat pad has room in case of minor oronasal/antral communications [14]. When needed, adequate bone support may be set by secondary bone grafting.

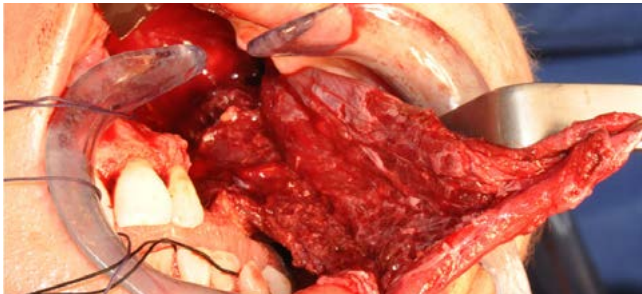


Figure 10

Pt no. 2. The left temporalis muscle raised and rotated in order to fill the defect and to wrap the zygomatic implants

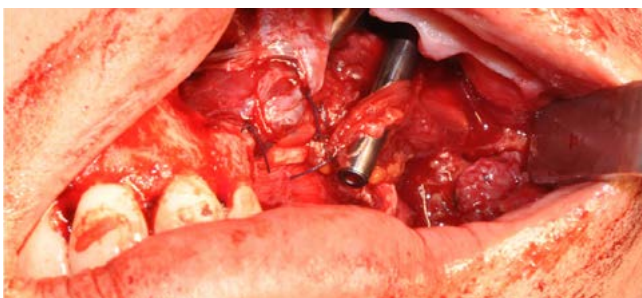


Figure 11

Pt no. 2. The fascial side of the left temporalis muscle stitched to the mucosal margin to separate the sino-nasal cavity from the oral one

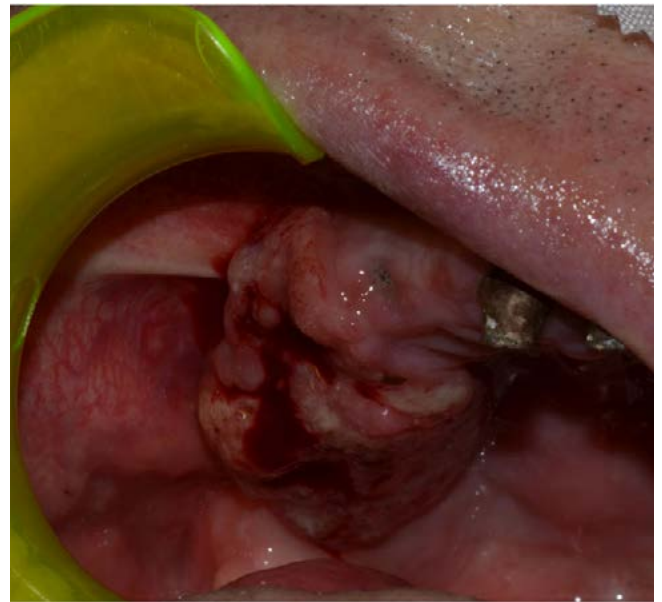


Figure 12

Pt no. 2. Coronal plane of the preoperative CT scan showing a radiopaque mass of the left maxilla

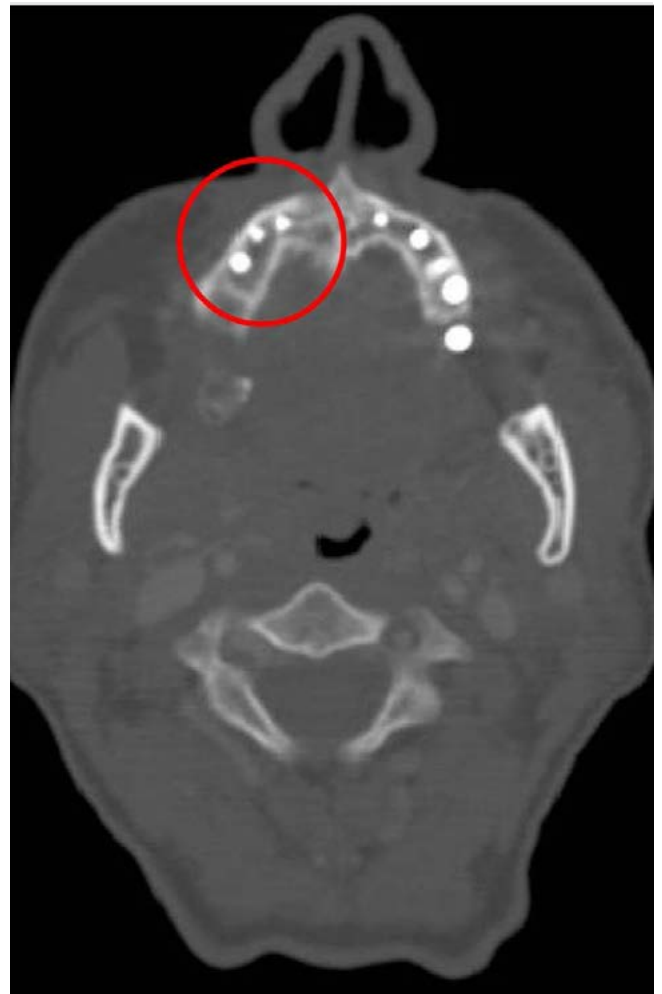

Figure 13

Pt no. 3. Preoperative CT scan

Finally, prosthetic obturator is recommended when the above solutions cannot be available or are contraindicated: it requires adequate anchoring (residual dentition, standard implants, deep vestibular sulcus) and continuous servicing.

In our opinion, primary closure by flaps should be preferred over prosthetic obturator, as this approach makes the patients more comfortable and prosthesisfree, immediately and during his/her daily activity. Indeed, in all three patients, local flaps have performed well and led to successful immediate closure of the oroantral communication following tumour ablation. Seok et al. [14] advocate the application of 4-hexylresorcinol in order to accelerate and improve re-epithelialization.

Common belief stresses that follow-up in patients wearing obturator would be easier and safer than that in patients having surgical closure of the palate. In fact, possible local recurrence of the tumour could be detected early, yet benefit in survival of such a policy has not definitively proved. Moreover, modern imaging techniques could be at least as effective as inspection in revealing possible relapse at an early stage.

Nevertheless, some patients are or become more demanding about full or maximum recovery of the finest activities linked to chewing, phonation, deglutition, and aesthetics: in these cases, dental rehabilitation through implant-supported prosthesis might greatly help, the fixture(s) being usually inserted in native or grafted bone. Zygomatic implants could overcome the possible problem of lacking or poor-quality bone [2, 5, 12, 15–22]. In such patients, ZI is usually a delayed, multi-staged procedure, either after having primarily closed the oronasal/ antral communication [12, 17, 19], either after left it untreated or amended with obturator [5, 16, 18]: the overall time from tumour treatment and final dental rehabilitation might require 1 year or more. Intuitively, interest has arisen in shortening this gap and we planned to move toward this direction.

The relatively innovative aspect of the present paper deals with the idea of challenging three different tasks in a single-stage procedure: resection of the tumour, closure of the oronasal/antral communication, and insertion of the zygomatic implants finalized to a fixed restoration.

In few words, we tried to reach the best cost/benefit ratio.

Indeed, Pellegrino et al. [12] should be credited for the first reported case, even if not clearly evident from their paper (personal communication from Prof. C. Marchetti). The authors also proposed a new classification of rehabilitation-orientated maxillary defects: in our opinion, it deserves attention because of its clarity and effectiveness in orientating therapeutic options.

We were able to complete the above plan within the expected period of 3 months in patient no. 1, whose outcome is optimal after 1 year.

Supplementary advantage of ZI at the time of tumour resection is to give implants sufficient time to become osseointegrated before prospective radiotherapy course,

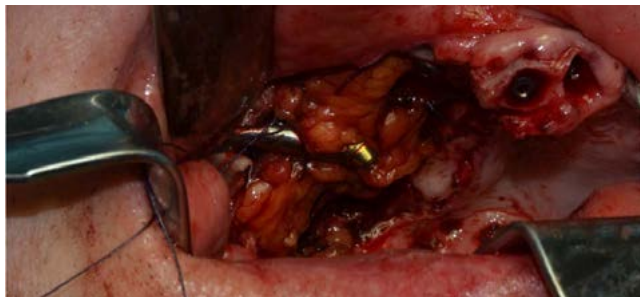

Figure 14

Pt no. 3. The zygomatic implant emerging in area of tooth 16 and surrounded by the buccal fat pad

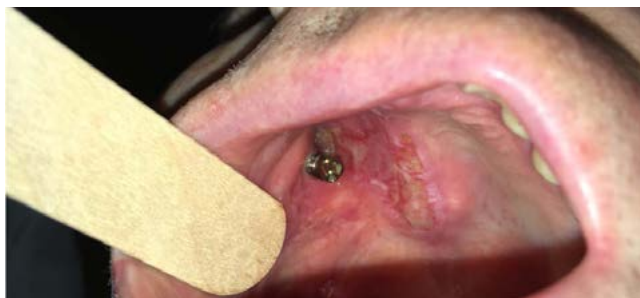

Figure 15

Pt no. 3. Intraoral view after 1 month

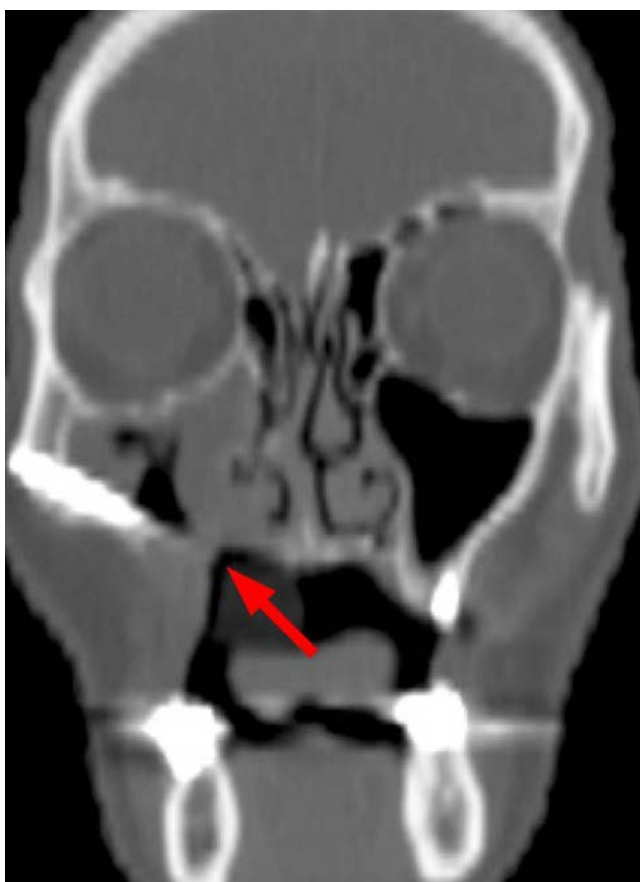

Figure 16

Pt no. 3. CT scan showing the optimal ZI insertion and the newly formed oroantral barrier

then avoiding or minimizing its well-known negative impact on healing [23]. Actually, patient nos. 2 and 3 took some benefits from this policy.

In addition, applying a maxillary prosthesis in the early stages minimizes contraction of facial soft tissues [16].

We performed ZI under direct vision, enhanced by resin guide pointing landmarks. The procedure was somewhat easier than ZI in simply atrophic patients, as the resected bone allowed more room to vision and manipulation. On the other hand, the prepared flaps and the residual dentition could make things a bit more difficult than usual situations. Some authors advocate either general [24] or specific computer-aided surgery [12, 25], or surgical navigation [15, 26], for accurate, safe zygomatic implant installation. Undoubtedly, these are effective apparatuses, whose limitations are availability and operating costs. The pilot hole technique [27] and piezosurgery could offer similar advantages—at least in terms of safety—with lower costs.

Zygomatic implants are most suitable for immediate loading in reason of the high torque usually necessary for their insertion and consequent outstanding primary stability. However, we privileged the delayed loading to achieve and maintain an adequate seal between oral and nasal/antral cavities.

Long-term results of ZI are quite satisfactory. Brånemark [2] reported a 97% success rate in a series of 184 zygomatic implants inserted in 81 patients.

Aparicio et al. [10] conducted a large review of zygomatic implant survival: success rates ranged 94.4 to 100%. Recently, Chrcanovic et al. [11] extended the analysis over 4556 zygomatic implants in 2161 patients: they found a noteworthy 12-year cumulative survival rate of 95.21%.

Despite the prosthetic aspects of the proposed technique are somewhat beyond the paper scope, some considerations appear obliged. Screw-retained, metal-core dental prostheses are popular, manageable devices allowing easy removal for fixture inspection and cleaning. An interesting point is that in patient no. 1, the interdental and inter-arch obligations lead to a double-cantilevered dental restoration, entailing a possible overload: to mitigate it prudently, mesial (to 23) and distal (to 27) splinting were conceived. Indeed, implant stability was preserved, as checked at regular clinical and X-ray follow-up examinations (Fig. 5).

Within reason, delayed ZI insertion in regard of radiotherapy and/or primary ablative surgery would have been more hazardous and difficult, if not impossible. In turn, fixed dental restoration would have been more demanding, more lasting, suboptimal, even not feasible. Concisely, immediate insertion of ZI at the ablative tumour time could be considered as a biological investment.

Conclusions

In selected cases, maxillary resection, zygomatic implant(s) placement, and palato-alveolar repair through local flaps can be conducted as same-stage procedure. Advantages would include the following:

- Immediate closure of the oronasal communication
- Quick return to normal or near-normal feeding and phonation
- Wide access to bony segment receiving zygomatic implants
- Unnecessary bone grafting Short surgery time
- Reduced number of substantial interventions
- Short time-to-rehabilitation
- Reduced financial impact
- Valid functional results
- Excellent long-term performance of ZI

We intend to propose this approach and wish the results will be confirmed in large series.

Abbreviations

Pt: Patient; ZI: Zygomatic implantology

Acknowledgements

The authors wish to warmly thank Mr Walter Quaglia, a dental technician, for his enthusiastic lab support.

Funding

This research did not receive any specific grant from funding agencies in the public, commercial, or not-for-profit sectors.

Availability of data and materials

Not applicable.

Authors' contributions

PS ideated the approach, performed the surgery, took care of the patients, collected the data, and wrote the manuscript. FG planned and performed or assisted with the implant surgery.

AM, LR, FC, and AB assisted with the surgery and took care of the patients. EG helped in the data collection, documentation, and editorial assistance. UG did the critical review. All authors read and approved the final manuscript.

Competing interests

The authors declare that they have no competing interests.

Consent for publication

All patients have agreed and signed the consent for publication.

Ethics approval and consent to participate

Written informed consent was obtained from each patient, and the study protocol conformed to the ethical guidelines of the World Medical Association Declaration of Helsinki—Ethical Principles for Medical Research Involving Human Subjects.

Author details

1Department of Otorhinolaryngology-H&N Surgery, Humanitas San Pio X Hospital, Via F. Nava 31, 20159 Milan, Italy. 2Department of Otorhinolaryngology, Ospedale Civile, Via Papa Giovanni Paolo II, 20025 Legnano, MI, Italy. 3Department of Oral Surgery, IRCCS Fondazione Cà' Granda, Ospedale Maggiore Policlinico, Via F. Sforza 35, 20122 Milan, Italy. 4Biomedical Surgical and Dental Sciences Department, Maxillo-Facial and Odontostomatology Unit, Fondazione Cà Granda IRCCS Ospedale Maggiore Policlinico, University of Milan, Milan, Italy. 5Department of Maxillo-Facial Surgery, Istituto Ortopedico Galeazzi, Via R. Galeazzi 4, 20161 Milan, Italy.

References

1. Aparicio C, Brånemark PI, Keller EE, Olive J (1993) Reconstruction of the premaxilla with autogenous iliac bone in combination with osseointegrated implants. *Int J Oral Maxillofac Implants* 8:61–67
2. Brånemark P-I (1998) Surgery and fixture installation. *Zygomaticus fixture clinical procedures* (ed. 1). Nobel Biocare AB, Göteborg, p 1
3. Malevez C, Daelemans P, Adriaenssens P, Durdu F (2003) Use of zygomatic implants to deal with resorbed posterior maxillae. *Periodontol* 2000(33):82–89
4. Kahnberg KE, Henry PJ, Hirsch JM, Ohnell LO, Andreasson L, Brånemark PI et al (2007) Clinical evaluation of the zygoma implant: 3-year follow-up at 16 clinics. *J Oral Maxillofac Surg* 65(10):2033–2038
5. Boyes-Varley JG, Howes DG, Davidge-Pitts KD, Brånemark I, McAlpine JA (2007) A protocol for maxillary reconstruction following oncology resection using zygomatic implants. *Int J Prosthodont* 20(5):521–531
6. O'Connell JE, Cotter J, Kearns GJ (2011) Maxillary reconstruction using zygomatic implants: a report of two cases. *J Ir Dent Assoc* 57(3):146–155
7. de Moraes EJ (2012) The buccal fat pad flap: an option to prevent and treat complications regarding complex zygomatic implant surgery. Preliminary report. *Int J Oral Maxillofac Implants* 27(4):905–910
8. Nocini PF, D'Agostino A, Chiarini L, Trevisiol L, Procacci P (2014) Simultaneous Le Fort I osteotomy and zygomatic implants placement with delayed prosthetic rehabilitation. *J Craniofac Surg* 25(3):1021–1024
9. Bacchi A, Santos MB, Pimentel MJ, Nóbilo MA, Consani RL (2014) Prosthetic improvement of pronounced buccally positioned zygomatic implants: a clinical report. *J Prosthodont* Aug 23(6):504–508
10. Aparicio C, Manresa C, Francisco K, Claros P, Alánde J, González-Martín O et al (2000) Zygomatic implants: indications, techniques and outcomes, and the zygomatic success code. *Periodontol* 66(1):41–58
11. Chrcanovic BR, Albrektsson T, Wennerberg A (2016) Survival and complications of zygomatic implants: an updated systematic review. *J Oral Maxillofac Surg* 74(10):1949–1964
12. Pellegrino G, Tarsitano A, Basile F, Pizzigallo A, Marchetti C (2015) Computer-aided rehabilitation of maxillary oncological defects using zygomatic implants: a defect-based classification. *J Oral Maxillofac Surg* 12:2446
13. Salvatori P, Paradisi S, Calabrese L, Zani A, Cantù G, Cappiello J et al (2014) Patients' survival after free flap reconstructive surgery of head and neck squamous cell carcinoma: a retrospective multicentre study. *Acta Otorhinolaryngol Ital* 34(2):99–104
14. Seok H, Kim MK, Kim SG (2016) Reconstruction of partial maxillectomy defect with a buccal fat pad flap and application of 4-hexylresorcinol: a case report. *J Korean Assoc Oral Maxillofac Surg* 42(6):370–374
15. Schramm A, Gellrich NC, Schimming R, Schmelzeisen R (2000) Computer-assisted insertion of zygomatic implants (Brånemark system) after extensive tumor surgery. *Mund Kiefer Gesichtschir* 4(5):292–295
16. Tamura H, Sasaki K, Watahiki R (2000) Primary insertion of implants in the zygomatic bone following subtotal maxillectomy. *Bull Tokyo Dent Coll* 41(1):21–24
17. Pia F, Aluffi P, Crespi MC, Arcuri F, Brucoli M, Benech A (2012) Intraoral transposition of pedicled temporalis muscle flap followed by zygomatic implant placement. *J Craniofac Surg* 23(5):e463–e465
18. Huang W, Wu Y, Zou D, Zhang Z, Zhang C, Sun J et al (2014) Long-term results for maxillary rehabilitation with dental implants after tumor resection. *Clin Implant Dent Relat Res* 16(2):282–291
19. D'Agostino A, Procacci P, Ferrari F, Trevisiol L, Nocini PF (2013) Zygoma implant-supported prosthetic rehabilitation of a patient after subtotal bilateral maxillectomy. *J Craniofac Surg* 24(2):159–162
20. Ugurlu F, Yıldız C, Sener BC, Sertgoz A (2013) Rehabilitation of posterior maxilla with zygomatic and dental implant after tumor resection: a case report. *Case Rep Dent* 2013:930345
21. El-Sayed WM, Gad MA, Medra AM (2014) Prosthodontic management of maxillectomy patients with dental implants in residual zygomatic bone: a preliminary report. *Int J Prosthodont* 27(6):534–540

22. Ozaki H, Ishikawa S, Kitabatake K, Yusa K, Sakurai H, Iino M (2016) Functional and aesthetic rehabilitation with maxillary prosthesis supported by two zygomatic implants for maxillary defect resulting from cancer ablative surgery: a case report/technique article. *Odontology* 104(2):233–238
23. Salvatori P, Podrecca S, Cantù G, Bosco R, Fallahdar D, Molinari R (2001) Prosthetic rehabilitation with endosseous implants in fibular free flaps reconstructed mandibles. *Acta Otorhinolaryngol Ital* 21(5):300–305
24. Garagiola U, Grigolato R, Soldo R, Bacchini M, Bassi G, De Nardi S et al (2016) Computer-aided design/computer-aided manufacturing of hydroxyapatite scaffolds for bone reconstruction in jawbone atrophy: a systematic review and case report. *Maxillofac Plast Reconstr Surg* 38:2
25. Noh K, Pae A, Lee JW, Kwon YD (2016) Fabricating a tooth- and implant-supported maxillary obturator for a patient after maxillectomy with computer-guided surgery and CAD/CAM technology: a clinical report. *J Prosthet Dent* 115(5):637–642
26. Chen X, Wu Y, Wang C (2011) Application of a surgical navigation system in the rehabilitation of maxillary defects using zygoma implants: report of one case. *Int J Oral Maxillofac Implants* 26(5):e29–e34
27. Takamaru N, Nagai H, Ohe G, Tamatani T, Sumida K, Kitamura S, Miyamoto Y (2016) Measurement of the zygomatic bone and pilot hole technique for safer insertion of zygomaticus implants. *Int J Oral Maxillofac Surg* 45(1):104–109

A New Surgical And Technical Approach In Zygomatic Implantology

F. GRECCHI¹, A.E. BIANCHI², S. SIERVO², E. GRECCHI¹, D. LAURITANO³, F. CARINCI⁴

¹Department of Maxillofacial Surgery, Galeazzi Hospital, Milan, Italy

² Department of Maxillofacial Surgery, "Istituto Stomatologico Italiano", Milan, Italy

³ Department of Medicine and Surgery, University of Milano Bicocca, Monza, Italy

⁴ Department of Morphology, Surgery and Experimental Medicine, University of Ferrara, Ferrara, Italy

SUMMARY

Purpose: Different surgical approaches for zygomatic implantology using new designed implants are reported. Material and methods. The surgical technique is described and two cases reported. The zygomatic fixture has a complete extrasinus path in order to preserve the sinus membrane and to avoid any post-surgical sinus sequelae. Results. The surgical procedure allows an optimal position of the implant and consequently an ideal emergence of the fixture on the alveolar crest.

Conclusion: The surgical procedures and the zygomatic implant design reduce remarkably the serious post-operative sequelae due to the intrasinus path of the zygomatic fixtures.

Key words: zygomatic implantology, atrophic maxilla, immediate loading.

Introduction

During the last two decades, the placement of zygomatic implants, usually inserted through the maxillary sinus and apically stabilized in the zygomatic bone, has proven to be an effective option in the management of severe atrophic edentulous maxilla (1-4). Zygomatic implants are an useful option in atrophic jaws to avoid bone grafting plus standard implants insertion (5-52, 112-114).

The installation of zygomatic implants was firstly introduced by Brånemark et al. in 1998 in order to rehabilitate the masticatory and the aesthetic functions in severe atrophied maxilla caused by trauma, congenital conditions, tumour resections or increased sinus pneumatization (53). Given the high success rate reported in literature for ZIs placement, this surgical technique can be considered as a valid alternative to bone augmentation and invasive surgery to restore function and improve the aesthetic result for patients with atrophic edentulous maxilla (2, 53- 57). Zygomatic implants, in fact, were subsequently used to rehabilitate severe atrophic upper jaws, classes V and VI, according to Cawood and Howell classification of edentulous jaws (58). At the beginning 1970 Linkow presented a surgical technique to rehabilitate extremely atrophic maxillae placing smooth implant (diameter 2 mm) apically inserted in the zygomatic bone (59).

New procedures and improvements have been developed since the description of the classical surgical technique

in 1998 (53). Stella and Warner introduced the "sinus slot approach" in 2000, a zygomatic implantation method that minimize the presence of the zygomatic implant through the sinus, improving the emergence orientation of the implant, because it allows a more vertical angle of the fixtures than the original technique (60, 115). In 2013 Aparicio (61) et al. proposed a surgical technique based on the relationship between the zygomatic/alveolar crest complex and the various anatomy guided zygomatic implants pathways (ZAGA) (61).

Extremely absolute contraindications to the placement of zygomatic implants are acute sinus infections, maxillary or zygomatic bone pathologies and underlying uncontrolled or malignant systemic disorders. Relative contraindications are chronic infections of the maxillary sinus and smoking more than 20 cigarettes a day. Zygomatic implants placement in patients that use bisphosphonates is to this day debated. A maxillary sinus with any pathology should preferably be treated before or during surgical procedures (56).

The surgical intervention for zygomatic implant placement, with currently systematic devices offered on the market, results to be remarkably challenging and arduous and it frequently requires the use of general anesthesia. The post surgical sequelae described in the literature (61, 62, 116), such as rhinosinusitis, sinusitis, paresthesia, oroantral fistula, mucositis and perimplant soft tissue dehiscences, represent to this day a critical and significant limit to the implementation of the zygomatic implant surgery and the extensive regular practice of this procedure. The surgical

system we present below was firstly introduced and described by Dr. Balan Igal D.M.D (ISR) and produced by Noris Medical, and it represents an important evolution and improvement of the previous techniques and systems both in the technical-operative procedures and in the eradication of the critical post operative sequelae due to the intrasinus path of the zygomatic fixtures.

Materials and methods

The surgical technique used for zygomatic implants placement considers the use of implant with a specific design: Noris Medical Zygomatic implant has an unthreaded long body ending with a particularly aggressive thread at the apical part of the implant. The zygomatic implant is anchored in the zygomatic bone with the conical threaded apical segment: the resulting torque, by virtue of the apically threaded 12.5 millimetres, is extremely high. The implant is placed following the procedures of the extramaxillary protocol, which is a successive modification of the traditional Brånemark technique. In the extramaxillary approach a bypass of the maxillary sinus is made in order to prevent any damage to the sinus membrane and to avoid post surgical sinus sequelae. The implant prosthetic platform is therefore shifted buccally to a more appropriate position of the emergence close to the alveolar crest, a less bulky restoration and a better designed prosthesis. A special design of the drills have been made in order to allow the clinician to create a clean and safe tunnel preparation with minimal risk of damaging the membrane. An angled Multi-Unit abutment from 17° to 60° will then provide the correction of the emerging angle needed.

The operative technique we are now describing has the purpose to decrease and avoid post surgical possible complications derived from the sinus path of the zygomatic implant, as rhinitis and sinusitis, difficult and uncomfortable prosthetic restorations consequent to the palatal emergence of the abutments, and extensive problems with the intraoral perimplant soft tissue, as mucositis.

For the surgical approach a slightly incision is made in the maxillary alveolar crest extending from the first molar right region to the left one, paying attention not to injure the emergence of the descending palatine artery that, due to anatomical evolution of the atrophic maxilla, may arise in the alveolar crest.

Two posterior vestibular releasing incisions are made bilaterally considering the emergence of Stensen's duct not to produce any accidental injuries, and a median releasing incision is made below the nasal spine.

Afterward a mucoperiosteal flap is raised simultaneously bilaterally along the whole incision or in two separate stages, according to the different anesthetic approach chosen for the intervention (general anesthesia or deep narcosis).

The mucoperiosteal flap reflection can be performed in two different ways depending on the surgical procedure implicated: the placement of only two zygomatic implants, or a quad-zygomatic surgery.

In the surgical case of two zygomatic implants placement, the mucoperiosteal flap is raised in order to expose the alveolar crest, the anterolateral wall of the maxillary sinus, and the origin of the zygomatic arch where the masseter muscle tendon is inserted; the mucoperiosteal flap of the paranasal region is raised medially to the emergence of the infraorbital nerve.

The infraorbital foramen is the posterior limit of the mucoperiosteal reflection and of the visible bone and it is exceeded only in case of special needs to reach the zygomatic notch and totally expose the outer surface of the malar region, area dedicated to the implant site preparation. In fact, normally the perception of the bone cutter spill is acquired from the fingertips through the thickness of the overlying skin on the malar bone.

In case of quad-zygoma surgery, the bone region exposed after the mucoperiosteal flap reflection is wider, and it reaches the lower orbital rim. The infraorbital foramen is localized and isolated both medially and distally, the emergence of the infraorbital nerve is meticulously ensured and protected during the entire surgical phases as the anterior zygomatic implant should be positioned at a safe distance from the aforementioned nerve.

The implant site preparation is performed with drills and burs mounted on a contro-angled handpiece. This expedient allows the posterior zygomatic implant positioning distal to the region of the maxillary second premolar easier. The end point of the anterior zygomatic implant will be close to the maxillary canine region bilaterally on the lowermost point of the alveolar crest.

After the mucoperiosteal flap is reflected, the surgical procedure minimum provides one or two corticotomies of the anterolateral wall of the sinus performed with a round diamond bur (4mm in diameter) in order to determine one or two marking points (Figures 1, 2).

The holes made through the bone with the round diamond bur, in order to set the correct place of the zygomatic implant, are then connected to the intraoral emergence of the zygomatic implant earlier determined using zygomatic burs for groove preparation. These burs have a not working tip and a diamond cilindric body of three different levels of grit (fine, medium, coarse) (Figure 3).

The conical not working tip of the bur is inserted in the marking point which provides a valid point of support and fulcrum for the subsequent bone preparation in the premolar and in the distal canine region, passing from the coarser to the finer bur.

The bur will be further deepen with a tangential movement of go and come for two-thirds of its diameter.

This procedure correctly performed respects the integrity of the Schneiderian membrane.

In order not to lacerate the sinus mucosa during following actions, a gentle inward shift of the Small Schneiderian membrane with a sinus periosteal should be carried out (Figure 4).

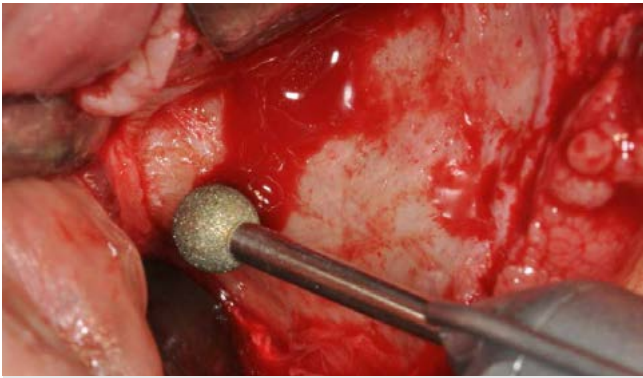


Figure 1

The 4 mm diameter round bur used to determine the initial marking point.

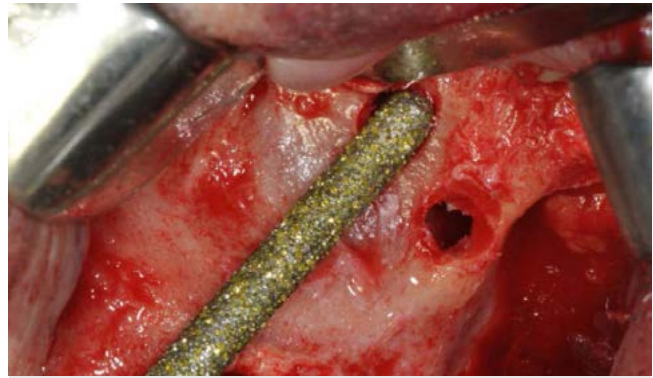


Figure 3

The anterolateral sinus wall is prepared with the coarse zygomatic bur: the not working tip is inserted in the marking point and the working diamond cylindrical body prepares the bone.

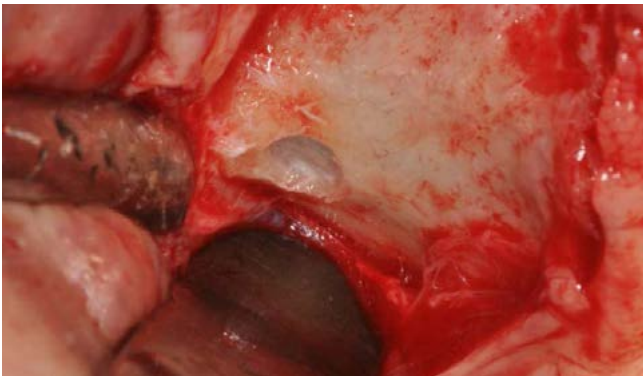


Figure 2

The marking point performed on the sinus wall.

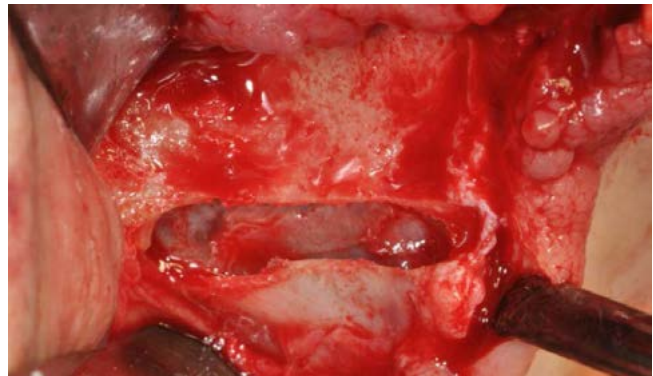


Figure 4

The sinus slot is performed and a gentle inward shift of the Schneiderian membrane is made.

Small accidental injuries and lacerations of the sinus mucosa in the region of the zygomatic recess are easily fixed and not significant in terms of sinusitis sequelae; on the contrary, those produced in the region of the alveolar crest, where the end of the zygomatic implant should be, must be solved also using resorbable membranes

The zygomatic bone preparation, where the apex of the zygomatic implant will be placed and anchored, is performed with a sequence of drills with the final conical cutting tip 2.5 cm long and 2-3.2mm in diameter in apex (Figure 5).

The smooth body of the drill has the same diameter of the antrostomy previously carried out. This slot in the sinus wall reproduces a true apical surgical preparation guide for the drills and it prevents dangerous and unsafe errors due to the excessive movements caused by the length of the drills used. It avoids the deviation of the drill from the planned direction.

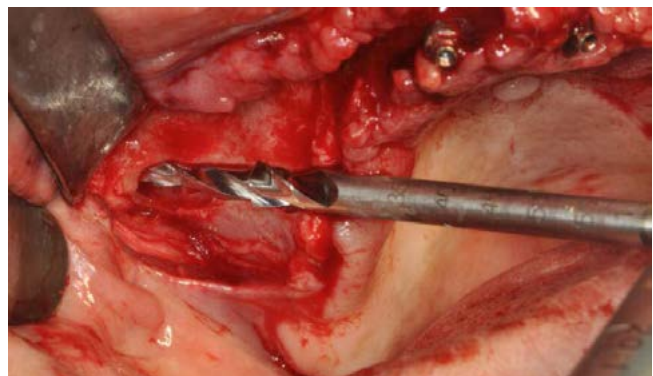


Figure 5

A sequence of drills with the final cutting tip 2.5 cm long and 2-3.2, mm in diameter in apex is used for the zygomatic bone preparation.

The first drill must totally penetrate the zygomatic bone and come out through the external cortical layer. It's important to feel with a finger through the skin of the periorbital region the cutting apex of the drill coming out from the zygomatic arch, laterally on the malar bone.

The preparation of the zygomatic implant site continues with the sequence of drills.

A depth indicator is then used to decide the correct length of the zygomatic fixture. The tip of the depth gauge is located on the external cortical zygomatic bone.

The diameter of the final hole on the zygomatic arch carried out by the drills is approximately 2.2 mm in diameter, much lower than the final circumferential size of the implant (3.2 mm). This difference avoids the risk of emergence of the end of the zygoma fixture from the bone during malar screwing when searching primary stability.

Generally we firstly perform the preparation of the anterior zygomatic implant, which is the more complicated and dangerous one, and subsequently we complete the preparation of the distal fixture tilting the drills in relation to the residual bone available, the most posterior and vertical as possible, so that the apexes are convergent, but do not interfere between them.

The implant is positioned with an extraoral screwdriver, if the anatomy is favourable, or with the usual operations of screwing that we use in all types of endosseous implants (Figure 6).

The emergence of the fixture must be in the optimal site from a prosthetic point of view, on the alveolar crest. The angled abutment position is checked in order to obtain an ideal emergence of the prosthetic abutment, and it's screwed.

The coverage of the region with Bichat fat pad or resorbable membranes is performed in those cases that present particular conditions of vestibular maxillary concavity and therefore it is not usually and frequently carried out (Figure 7).

The resorbable suture completes the surgical intervention.

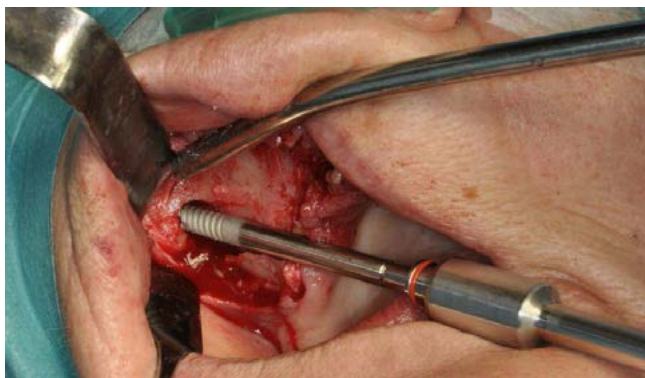


Figure 6

The zygomatic implant is positioned with an extraoral screwdriver.

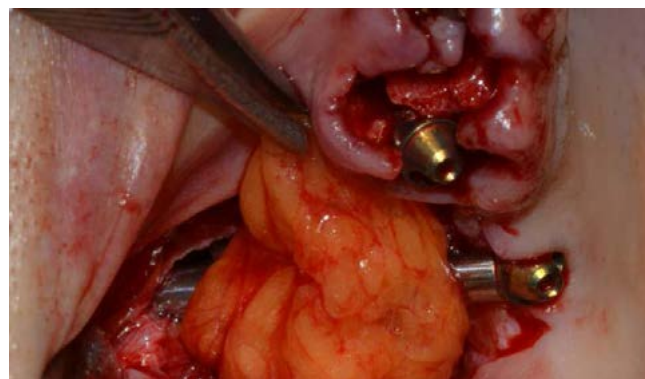


Figure 7

The Bichat fat pad used to cover the zygomatic implant.

Clinical case 1

A 59-year-old Caucasian male patient with partial edentulous maxilla required a fixed prosthetic rehabilitation with zygomatic implants. He had no history of pathologies that could contraindicate surgery.

Panoramic radiography and CT were examined to evaluate the bone volume of the maxilla and of the zygomas and to eliminate the risk of undiagnosed pathologies.

The surgery procedures were performed under general anesthesia with endotracheal intubation reinforced with local infiltration of anesthesia with vasoconstrictor. Three upper incisors were extracted and two zygomatic implants and four normal implants were placed (Figure 8).

Clinical case 2

A 51-year-old Caucasian female patient with total edentulous maxilla needed prosthetic rehabilitation. The patient refused grafting procedures prior to implant placement, as onlay bone grafting and/or sinus lift. It was decided to perform a quad-zygoma implant rehabilitation.

Pre op. radiographic examination, included orthopantomograms and computed tomography, were evaluated. An advanced vertical and horizontal bone loss of the alveolar ridge was revealed and there was no evidence of other pathologies that could exclude surgery.

The operation was executed under general anesthesia with nasotracheal intubation and local injection of anesthesia with vasoconstrictor. Four zygomatic implants were placed (Figure 9).

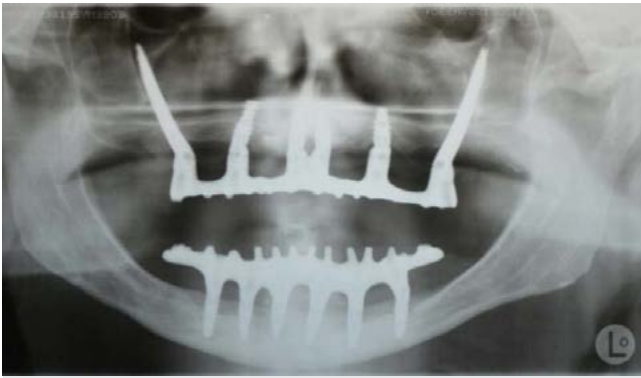

Figure 8

Post surgery orthopantomograms of clinical case 1.

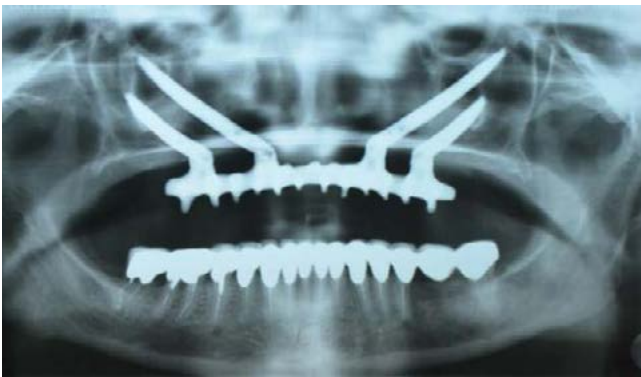


Figure 9

Post surgery radiographic examination of clinical case 2.

Discussion

A functional occlusal prosthetic rehabilitation of severely resorbed edentulous maxilla with conventional implant-supported dental bridges constitutes a difficult therapeutic challenge. Tooth extractions, use of dentures and the presence of extensive maxillary sinus often result in a lack of bone volume. Therefore there are many obstacles and limitations to the final result that can be achieved using bone-anchored fixed prostheses in all those patients with advanced atrophic maxilla. Recurrently the residual alveolar bone is too small for placement and osseointegration of dental implants (63). For more than three decades, bone grafting prior to, or simultaneously with, implant placement, has become routine in oral rehabilitation. Several bone augmentation techniques (maxillary sinus floor augmentation, onlay bone grafting...) have been described in literature with the common goal of increasing the volume of the residual bone in order to place implants and rehabilitate the masticatory function and speech with fixed prosthesis (54, 64-67). However all bone grafting procedures are resource demanding and require long treatment and healing periods, such as Le Fort I osteotomies or revascularized flaps. High risk for morbidity is present because of harvesting of bone grafts, and the failure rates are more than in nongrafted

situations (68). Many efforts have been made to pursue alternatives to major bone grafting procedures and to achieve a valid osseointegrated implant anchorage exploiting the residual native bone. The need of bone grafting may be replaced and bypassed by the use of remaining existing anchorage bone sites in the maxillary tuberosities, pterygoid plates or zygomatic bone. Some Authors suggested the pterigomaxillary suture as an alternative location for implant placement, but the risk of vascular damage is very high because of the path of the descending maxillary artery (69-71). Other Authors proposed the use of tilted implants and/or short implants to use the residual bone and to avoid any sinus lift procedures (64).

Brånemark et al. firstly introduced the use of zygomatic bone for anchorage of zygomatic fixtures (53). This surgical technique was presented for rehabilitating patients with extremely resorbed maxilla and wide-ranging maxillary defects due to tumor resections, congenital defects, traumatic events. The use of zygomatic implants reduced the time of treatment and the number of surgical operations. The surgical approach consists of a similar Le Fort I vestibular incision between the first molar region with vertical releasing incisions. Subsequently a mucoperiosteal flap is raised in order to expose the hard palate and the alveolar crest, the zygomatic complex, the lateral wall of the maxillary sinus, the infraorbital nerve. A bone window is opened at the uppermost lateral aspect of the maxillary sinus wall and the sinus membrane is prudently reflected in the sinus cavity. The site for the implant placement in the maxillary sinus and on the palatal side of the alveolar crest is then prepared with a series of drills. Unfortunately this surgical procedure often causes problems related to the intrasinus path of the zygomatic implant and patient discomfort and difficulties with hygiene procedures and speech due to the bulky dental bridge at the palatal aspect.

Since Brånemark, new procedures and improvements have been made.

In 2000 Stella and Warner (60) introduced “the sinus slot approach”. This operative technique allows a more vertical placement of the zygomatic implant and consequently a better buccal emergence of the implant. The crestal incision is less extensive than that of Brånemark: it's made from one tuberosity to the contralateral one, vertical releasing incisions are made. The raising of the mucoperiosteal flap allows a good visibility of the region and the palatal mucosa is reflected only to expose the alveolar ridge. Two bur holes are made, the first on the superior extent of the contour of the zygomatic buttress, and the second one on the alveolar ridge. Afterward a slot connects the holes and it results in a small antrostomy in order to have a correct orientation of the drills used for zygomatic implants placement. The sinus mucosa is preserved and the implant can be directly seen during all the surgical procedures. A greater bone to implant contact is obtained. The presence of the zygomatic implant through the sinus is minimize and postoperative edema and ecchymosis are reduced. The patient discomfort decreases because of the improvements of the implant emergence, which results more buccally than the original technique.

Aparicio (61) et al. in 2013 proposed a more anatomically and more prosthetically driven approach called “the zygomatic anatomy guided approach” (ZAGA). This surgical technique focuses on interindividual anatomical differences between patients. No initial window or slot is needed to be prepared on the lateral wall of the maxillary sinus because the preparation of the zygomatic implant site is guided by the anatomy of the edentulous maxilla. The procedure, in order to determine the placement of the fixture, is different from the previously described techniques.

Firstly, the correct emergence of the zygomatic implant on the alveolar ridge is established in order to obtain an optimal prosthetic outcome. Then, the apical entrance of the implant in the zygomatic bone is decided according to the number and to the length of implants required, and to the anatomy of the area. Thirdly, the implant pathway is identified after connecting the two points: the direction of the final preparation of the site is guided. The final path of the implant body may definitely depends on the anatomy of the patient, and it may vary from a totally intrasinus placement to a totally extrasinus one.

The surgical technique we have above described introduces new expedients and precautions in order to decrease and avoid post-surgical possible complications. The innovative design of the zygomatic implant is different from the first proposed and used by other Authors: the implant has an unthreaded long body ending with a particularly aggressive threaded apical segment. The risk of peri-implantitis is so decreased that is of paramount importance in two-stage implantology (13, 14, 16, 72-111, 117).

The zygomatic fixture has a complete extrasinus path in order to preserve the sinus membrane and to avoid any post-surgical sinus sequelae.

The surgical procedure allows an optimal position of the implant and consequently an ideal emergence of the fixture on the alveolar crest. The correction of the emerging angle needed is provided thanks to angled Multi Unit Abutments from 17 to 60°.

Those developments and improvements both of the surgical procedures and the zygomatic implant design reduce the serious post-operative sequelae remarkably due to the intrasinus path of the zygomatic fixtures.

Acknowledgments

The Authors thank Dr. Balan Igal D.M.D (ISR) and Noris Medical.

References

1. Malevez C, Daelemans P, Adriaenssens P, et al. Use of zygomatic implants to deal with resorbed posterior maxillae. *Periodontol* 2000. 2003;33:82-89.
2. Branemark PI, Grondahl K, Ohnrell LO, et al. Zygoma fixture in the management of advanced atrophy of the maxilla: technique and long-term results. *Scand J Plast Reconstr Surg Hand Surg*. 2004;38:70-85.
3. Parel SM, Branemark PI, Ohnrell LO, et al. Remote implant anchorage for the rehabilitation of maxillary defects. *J Prosthet Dent*. 2001;86:377-381.
4. Higuchi KW. Minimization in oral implant rehabilitation: a patient-centered ethics-based approach in zygomatic implants. In: eds. Aparicio C. *The anatomy guided approach*. Berlin: Quintessence; 2012:1-6.
5. Lucchese A, Carinci F, Saggese V, et al. Immediate loading versus traditional approach in functional implantology. *European Journal of Inflammation*. 2012; 10:55-58.
6. Traini T, Danza M, Zollino I, et al. Histomorphometric evaluation of an immediately loaded implant retrieved from human mandible after 2 years. *International Journal of Immunopathology and Pharmacology*. 2011;24:31-36.
7. Scarano A, Murmura G, Carinci F, et al. Immediately loaded small-diameter dental implants: evaluation of retention, stability and comfort for the edentulous patient. *European Journal of Inflammation*. 2012;10:19-23.
8. Degidi M, Piattelli A, Carinci F. Clinical outcome of narrow diameter implants: a retrospective study of 510 implants. *J Periodontol*. 2008;79:49-54.
9. Degidi M, Piattelli A, Iezzi G, et al. Do longer implants improve clinical outcome in immediate loading? *Int J Oral Maxillofac Surg*. 2007;36:1172-1176.
10. Degidi M, Piattelli A, Carinci F. Immediate loaded dental implants: comparison between fixtures inserted in postextractive and healed bone sites. *J Craniofac Surg*. 2007;18:965-971.
11. Degidi M, Piattelli A, Iezzi G, et al. Retrospective study of 200 immediately loaded implants retaining 50 mandibular overdentures. *Quintessence Int*. 2007;38: 281-288.
12. Degidi M, Piattelli A, Iezzi G, et al. Immediately loaded short implants: analysis of a case series of 133 implants. *Quintessence Int*. 2007;38:193-201.
13. Degidi M, Piattelli A, Iezzi G, et al. Wide-diameter implants: Analysis of clinical outcome of 304 fixtures. *Journal of Periodontology*. 2007;78:52-58.
14. Degidi M, Piattelli A, Gehrke P, et al. Five-year outcome of 111 immediate nonfunctional single restorations. *J Oral Implantol*. 2006;32:277-285.

15. Degidi M, Piattelli A & Carinci F. Parallel screw cylinder implants: Comparative analysis between immediate loading and two-stage healing of 1005 dental implants with a 2-year follow up. *Clinical Implant Dentistry and Related Research*. 2006;8:151-160.
16. Degidi M, Piattelli A, Gehrke P, et al. Clinical outcome of 802 immediately loaded 2-stage submerged implants with a new grit-blasted and acid-etched surface: 12- month follow-up. *Int J Oral Maxillofac Implants*. 2006;21:763-768.
17. Degidi M, Piattelli A, Felice P, et al. Immediate functional loading of edentulous maxilla: a 5-year retrospective study of 388 titanium implants. *J Periodontol*. 2005;76:1016-1024.
18. Rigo L, Viscioni A, Franco M, et al. Overdentures on implants placed in bone augmented with fresh frozen bone. *Minerva Stomatol*. 2011;60:5-14.
19. Carinci F, Brunelli G, Franco M, et al. A retrospective study on 287 implants installed in resorbed maxillae grafted with fresh frozen allogeneous bone. *Clin Implant Dent Relat Res*. 2010;12:91-98.
20. Viscioni A, Rigo L, Franco M, et al. Reconstruction of severely atrophic jaws using homografts and simultaneous implant placement: a retrospective study. *J Oral Implantol*. 2010;36:131-139.
21. Franco M, Rigo L, Viscione A, et al. CaPO4 blasted implants inserted into iliac crest homologue frozen grafts. *The Journal of oral implantology*. 2009;35:176-180.
22. Viscioni A, Franco M, Rigo L, et al. Implants inserted into homografts bearing fixed restorations. *Int J Prosthodont*. 2009;22:148-154.
23. Franco M, Viscioni A, Rigo L, et al. Clinical outcome of narrow diameter implants inserted into allografts. *J Appl Oral Sci*. 2009;17:301-306.
24. Viscioni A, Franco M, Rigo L, et al. Retrospective study of standard-diameter implants inserted into allografts. *J Oral Maxillofac Surg*. 2009;67:387-393.
25. Baj A, Sollazzo V, Lauritano D, et al. Lights and shadows of bone augmentation in severe resorbed mandible in combination with implant dentistry. *Journal of biological regulators and homeostatic agents*. 2016;30(2Suppl 1):177-182.
26. Carinci F, Brunelli G, Zollino I, et al. Mandibles grafted with fresh-frozen bone: an evaluation of implant outcome. *Implant Dent*. 2009;18:86-95.
27. Franco M, Tropina E, De Santis B, et al. A 2-year follow- up study on standard length implants inserted into alveolar bone sites augmented with homografts. *Stomatologija*. 2008;10:127-132.
28. Danza M, Paracchini L, Carinci F. Tridimensional finite element analysis to detect stress distribution in implants. *Dental Cadmos*. 2012;80:598-602.
29. Danza M, Grecchi F, Zollino I, et al. Spiral implants bearing full-arch rehabilitation: Analysis of clinical outcome. *Journal of Oral Implantology*. 2011;37:447-455.
30. Danza M, Zollino I, Avantaggiato A, et al. Distance between implants has a potential impact of crestal bone resorption. *Saudi Dental Journal*. 2011;23:129-133.
31. Carinci F & Danza M. Clinical outcome of implants inserted in piezo split alveolar ridges: A pilot study. In: *Perspectives on Clinical Dentistry*. 2011:29-30.
32. Danza M, Zollino I, Guidi R, et al. Computer planned implantology: Analysis of a case series. In: *Perspectives on Clinical Dentistry*. 2011:287-300.
33. Danza M, Carinci F. Flapless surgery and immediately loaded implants: a retrospective comparison between implantation with and without computer-assisted planned surgical stent. *Stomatologija*. 2010;12:35-41.
34. Danza M, Quaranta A, Carinci F, et al. Biomechanical evaluation of dental implants in D1 and D4 bone by Finite Element Analysis. *Minerva stomatologica*. 2010;59:305-313.
35. Danza M, Riccardo G, Carinci F. Bone platform switching: a retrospective study on the slope of reverse conical neck. *Quintessence Int*. 2010;41:35-40.
36. Danza M, Fromovich O, Guidi R, et al. The clinical outcomes of 234 spiral family implants. *J Contemp Dent Pract*. 2009;10:E049-056.
37. Calvo-Guirado JL, Ortiz-Ruiz AJ, Lopez-Mari L, et al. Immediate maxillary restoration of single-tooth implants using platform switching for crestal bone preservation: a 12-month study. *Int J Oral Maxillofac Implants*. 2009;24:275-281.
38. Danza M, Guidi R, Carinci F. Comparison Between Implants Inserted Into Piezo Split and Unsplit Alveolar Crests. *Journal of Oral and Maxillofacial Surgery*. 2009;67:2460-2465.
39. Danza M, Scarano A, Zollino I, et al. Evaluation of biological width around implants inserted in native alveolar crest bone. *Journal of Osseointegration*. 2009;1:73- 76.
40. Danza M, Zollino I, Guidi R, et al. A new device for impression transfer for non-parallel endosseous implants. *Saudi Dental Journal*. 2009;21:79-81.
41. Andreasi Bassi M, Lopez MA, Confalone L, et al. Clinical outcome of a two-piece implant system with an internal hexagonal connection: a prospective study. *J Biol Regul Homeost Agents*. 2016;30:7-12.
42. Danza M, Guidi R, Carinci F. Spiral family implants inserted in postextraction bone sites. *Implant Dent*. 2009;18:270-278.
43. Falisi G, Severino M, Rastelli C, et al. The effects of surgical preparation techniques and implant macrogeometry on primary stability: An in vitro study. *Medicina Oral, Patologia Oral y Cirugia Bucal*. 2017;22: e201-e206.

44. Pocaterra A, Caruso S, Bernardi S, et al. Effectiveness of platelet-rich plasma as an adjunctive material to bone graft: a systematic review and meta-analysis of randomized controlled clinical trials. *International Journal of Oral and Maxillofacial Surgery*. 2016;45:1027- 1034.
45. Marrelli M, Pujia A, Palmieri F, et al. Innovative approach for the in vitro research on biomedical scaffolds designed and customized with CAD-CAM technology. *International Journal of Immunopathology and Pharmacology*. 2016;29:778-783.
46. Giuca MR, Pasini M, Giuca G, et al. Investigation of periodontal status in type 1 diabetic adolescents. *European journal of paediatric dentistry : official journal of European Academy of Paediatric Dentistry*. 2015;16:319-323.
47. Giuca MR, Pasini M, Caruso S, et al. Index of orthodontic treatment need in obese adolescents. *International Journal of Dentistry*. 2015;2015:
48. Caruso S, Sgolastra F, Gatto R. Dental pulp regeneration in paediatric dentistry: The role of stem cells. *European Journal of Paediatric Dentistry*. 2014;15:90-94. 49.
49. De Vico G, Ottria L, Bollero P, et al. Aesthetic and functionality in fixed prosthodontic: sperimental and clinical analysis of the CAD-CAM systematic 3Shape. *Oral Implantol (Rome)*. 2008;1:104-115.
50. Moretto D, Gargari M, Nordsjo E, et al. Immediate loading: a new implant technique with immediate loading and aesthetics: Nobel Active. *Oral Implantol (Rome)*. 2008;1:50-55.
51. Spinelli D, De Vico G, Condò R, et al. Transcrestal guided sinus lift without grafting materials: A 36 months clinical prospective study. *ORAL and Implantology*. 2015;8:74-86.
52. Bartuli FN, Luciani F, Caddeo F, et al. Piezosurgery vs High Speed Rotary Handpiece: a comparison between the two techniques in the impacted third molar surgery. *Oral Implantol (Rome)*. 2013;6:5-10.
53. Branemark PI. Surgery and fixture installation: zygomaticus fixture clinical procedures. Place: Nobel Biocare AB,1998.
54. Aparicio C, Manresa C, Francisco K, et al. The longterm use of zygomatic implants: a 10-year clinical and radiographic report. *Clin Implant Dent Relat Res*. 2014;16:447-459.
55. Penarrocha M, Garcia B, Marti E, et al. Rehabilitation of severely atrophic maxillae with fixed implant-supported prostheses using zygomatic implants placed using the sinus slot technique: clinical report on a series of 21 patients. *Int J Oral Maxillofac Implants*. 2007;22:645-650.
56. Chrcanovic BR, Albrektsson T & Wennerberg A. Survival and Complications of Zygomatic Implants: An Updated Systematic Review. *J Oral Maxillofac Surg*. 2016;74:1949-1964.
57. Grecchi F, Busato A, Grecchi E, et al. Surgicallyguided zygomatic and pterygoid implants - a no-grafting rehabilitation approach in severe atrophic maxilla -A case report. 2013;1.
58. Cawood JI, Howell RA. A classification of the edentulous jaws. *Int J Oral Maxillofac Surg*. 1988;17:232- 236.
59. Linkow LI, Cherchève R. Theories and techniques of oral implantology. Place: C. V. Mosby Co, 1970.
60. Stella JP, Warner MR. Sinus slot technique for simplification and improved orientation of zygomaticus dental implants: a technical note. *Int J Oral Maxillofac Implants*. 2000;15:889-893.
61. Aparicio C, Manresa C, Francisco K, et al. Zygomatic implants placed using the zygomatic anatomy-guided approach versus the classical technique: a proposed system to report rhinosinusitis diagnosis. *Clin Implant Dent Relat Res*. 2014;16:627-642.
62. Davo R. Sinus reactions to zygomatic implants. In: (ed.^(eds. Aparicio, C). *The anatomy guided approach*. Berlin: Quintessence; 2012:59-76.
63. Stievenart M, Malevez C. Rehabilitation of totally atrophied maxilla by means of four zygomatic implants and fixed prosthesis: a 6-40-month follow-up. *Int J Oral Maxillofac Surg*. 2010;39:358-363.
64. Aparicio C, Manresa C, Francisco K, et al. Zygomatic implants: indications, techniques and outcomes, and the zygomatic success code. *Periodontol 2000*. 2014;66:41- 58.
65. Becktor JP, Hallstrom H, Isaksson S, et al. The use of particulate bone grafts from the mandible for maxillary sinus floor augmentation before placement of surfacemodified implants: results from bone grafting to delivery of the final fixed prosthesis. *J Oral Maxillofac Surg*. 2008;66:780-786.
66. Nystrom E, Nilson H, Gunne J, et al. Reconstruction of the atrophic maxilla with interpositional bone grafting/ Le Fort I osteotomy and endosteal implants: a 11- 16 year follow-up. *Int J Oral Maxillofac Surg*. 2009;38:1-6.
67. Hallman M, Hedin M, Sennerby L, et al. A prospective 1-year clinical and radiographic study of implants placed after maxillary sinus floor augmentation with bovine hydroxyapatite and autogenous bone. *J Oral Maxillofac Surg*. 2002;60:277-284; discussion 285- 276.
68. Esposito M, Hirsch JM, Lekholm U, et al. Biological factors contributing to failures of osseointegrated oral implants. (I). Success criteria and epidemiology. *Eur J Oral Sci*. 1998;106:527-551.
69. Fernandez Valeron J, Fernandez Velazquez J. Placement of screw-type implants in the pterygomaxillarypyramidal region: surgical procedure and preliminary results. *Int J Oral Maxillofac Implants*. 1997;12:814- 819.

70. Graves SL. The pterygoid plate implant: a solution for restoring the posterior maxilla. *Int J Periodontics Restorative Dent*. 1994;14:512-523.
71. Tulasne JF. Osseointegrated fixtures in the pterygoid region. In: eds. Worthington P, Branemark PL. *An advanced osseointegration surgery: applications in the maxillofacial region*. Chicago, IL: Quintessence; 1992:182-188.
72. Lauritano D, Martinelli M, Mucchi D, et al. Bacterial load of periodontal pathogens among Italian patients with chronic periodontitis: A comparative study of three different areas. *Journal of Biological Regulators and Homeostatic Agents*. 2016;30:149-154.
73. Lauritano D, Scapoli L, Mucchi D, et al. Infectogenomics: Lack of association between vdr, il6, il10 polymorphisms and “red Complex” bacterial load in a group of Italian adults with chronic periodontal disease. *Journal of Biological Regulators and Homeostatic Agents*. 2016;30:155-160.
74. Checchi L, Gatto MR, Checchi V, et al. Bacteria prevalence in a large Italian population sample: A clinical and microbiological study. *Journal of Biological Regulators and Homeostatic Agents*. 2016;30:199-208.
75. Meynardi F, Pasqualini ME, Rossi F, et al. Correlation between dysfunctional occlusion and periodontal bacterial profile. *J Biol Regul Homeost Agents*. 2016;30: 115-121.
76. Lombardo L, Carinci F, Martini M, et al. Quantitative evaluation of dentin sialoprotein (DSP) using microbeads - A potential early marker of root resorption. *ORAL and Implantology*. 2016;9:132-142.
77. Lauritano D, Cura F, Candotto V, et al. Evaluation of the Efficacy of Titanium Dioxide with Monovalent Silver Ions Covalently Linked (Tiab) as an Adjunct to Scaling and Root Planing in the Management of Chronic Periodontitis Using Pcr Analysis: A Microbiological Study. *J Biol Regul Homeost Agents*. 2015; 29:127-130.
78. Scapoli L, Girardi A, Palmieri A, et al. Quantitative Analysis of Periodontal Pathogens in Periodontitis and Gingivitis. *J Biol Regul Homeost Agents*. 2015;29:101- 110.
79. Lauritano D, Cura F, Candotto V, et al. Periodontal Pockets as a Reservoir of Helicobacter Pylori Causing Relapse of Gastric Ulcer: A Review of the Literature. *J Biol Regul Homeost Agents*. 2015;29:123-126.
80. Scapoli L, Girardi A, Palmieri A, et al. Interleukin-6 Gene Polymorphism Modulates the Risk of Periodontal Diseases. *J Biol Regul Homeost Agents*. 2015;29: 111-116.
81. Carinci F, Girardi A, Palmieri A, et al. LAB®-Test 1: Peri-Implantitis and bacteriological analysis. *European Journal of Inflammation*. 2012;10:91-93.
82. Carinci F, Girardi A, Palmieri A, et al. LAB®-test 2: Microflora and periodontal disease. *European Journal of Inflammation*. 2012;10:95-98.
83. Carinci F, Girardi A, Palmieri A, et al. Lab®-test 3: Genetic susceptibility in periodontal disease. *European Journal of Inflammation*. 2012;10:99-101.
84. Scapoli L, Girardi A, Palmieri A, et al. IL6 and IL10 are genetic susceptibility factors of periodontal disease. *Dent Res J (Isfahan)*. 2012;9:S197-201.
85. Carinci F, Girardi A, Palmieri A, et al. Lab-test 2: microflora and periodontal disease. *European Journal of Inflammation*. 2012;10:95-98.
86. Cura F, Palmieri A, Girardi A, et al. Lab-Test (R) 4: Dental caries and bacteriological analysis. *Dent Res J (Isfahan)*. 2012;9:S139-141.
87. Roncati M, Lauritano D, Cura F, et al. Evaluation of light-emitting diode (led-835 nm) application over human gingival fibroblast: An in vitro study. *Journal of Biological Regulators and Homeostatic Agents*. 2016;30:161-167.
88. Caccianiga G, Rey G, Paiusco A, et al. Oxygen high level laser therapy is efficient in treatment of chronic periodontitis: A clinical and microbiological study using PCR analysis. *Journal of Biological Regulators and Homeostatic Agents*. 2016;30:87-97.
89. Lauritano D, Bignozzi CA, Pazzi D, et al. Evaluation of the efficacy of a new oral gel as an adjunct to home oral hygiene in the management of chronic periodontitis. A microbiological study using PCR analysis. *J Biol Regul Homeost Agents*. 2016;30:123-128.
90. Carinci F, Palmieri A, Girardi A, et al. Aquolab® ozone-therapy is an efficient adjuvant in the treatment of chronic periodontitis: A case-control study. *Journal of Orofacial Sciences*. 2015;7:27-32.
91. Lauritano D, Cura F, Gaudio RM, et al. Polymerase Chain Reaction to Evaluate the Efficacy of Silica Dioxide Colloidal Solutions in the Treatment of Chronic Periodontitis: A Case Control Study. *J Biol Regul Homeost Agents*. 2015;29:131-135.
92. Lauritano D, Petrucci M, Nardi GM, et al. Single Application of a Dessicating Agent in the Treatment of Recurrent Aphthous Stomatitis. *J Biol Regul Homeost Agents*. 2015;29:59-66.
93. Carinci F, Lauritano D, Cura F, et al. Prevention of bacterial leakage at implant-Abutment connection level: An in vitro study of the efficacy of three different implant systems. *Journal of Biological Regulators and Homeostatic Agents*. 2016;30:69-73.
94. El Haddad E, Gianni AB, Mancini GE, et al. Implantabutment leaking of replace conical connection nobel biocare® implant system. An in vitro study of the microbiological penetration from external environment to implant-abutment space. *ORAL and Implantology*. 2016;9:76-82.
95. Mancini GE, Gianni AB, Cura F, et al. Efficacy of a new implant-abutment connection to minimize microbial contamination: An in vitro study. *ORAL and Implantology*. 2016;9:99-105.

96. Roncati M, Lucchese A, Carinci F. Non-Surgical treatment of peri-Implantitis with the adjunctive use of an 810-nm diode laser. *Journal of Indian Society of Periodontology*. 2013;17:812-815.
97. Scarano A, Tripodi D, Carinci F, et al. Biofilm formation on titanium alloy and anatase-Bactercline® coated titanium healing screws: An in vivo human study. *Journal of Osseointegration*. 2013;5:8-12.
98. Brunelli G, Carinci F, Zollino I, et al. Sem evaluation of 10 infected implants retrieved from man. *European Journal of Inflammation*. 2012;10:7-12.
99. Scarano A, Sinjari B, Di Orio D, et al. Surface analysis of failed oral titanium implants after irradiated with ErCr:ysgg 2780 laser. *European Journal of Inflammation*. 2012;10:49-54.
100. Brunelli G, Carinci F, Zollino I, et al. Peri-implantitis. A case report and literature review. *European Journal of Inflammation*. 2012;10:1-5.
101. Scarano A, Piattelli A, Polimeni A, et al. Bacterial adhesion on commercially pure titanium and anatasecoated titanium healing screws: An in vivo human study. *Journal of Periodontology*. 2010;81:1466-1471.
102. Grecchi F, Zollino I, Candotto V, et al. A case of mandible osteonecrosis after a severe periimplant infection. *Dent Res J (Isfahan)*. 2012;9:S233-236.
103. Carinci F, Farina A, Zanetti U, et al. Alveolar ridge augmentation: a comparative longitudinal study between calvaria and iliac crest bone grafts. *J Oral Implantol*. 2005;31:39-45.
104. Carinci F, Pezzetti F, Volinia S, et al. Analysis of MG63 osteoblastic-cell response to a new nanoporous implant surface by means of a microarray technology. *Clinical Oral Implants Research*. 2004;15:180-186.
105. Oliveira DP, Palmieri A, Carinci F, et al. Osteoblasts behavior on chemically treated commercially pure titanium surfaces. *J Biomed Mater Res A*. 2014;102:1816- 1822.
106. Andreasi Bassi M, Lopez MA, Confalone L, et al. Hydraulic sinus lift technique in future site development: clinical and histomorphometric analysis of human biopsies. *Implant Dent*. 2015;24:117-124.
107. El Haddad E, Lauritano D, Carinci F. Interradicular septum as guide for pilot drill in postextractive implantology: a technical note. *J Contemp Dent Pract*. 2015;16:81-84.
108. Azzi L, Carinci F, Gabaglio S, et al. *Helicobacter pylori* in periodontal pockets and saliva: A possible role in gastric infection relapses. *Journal of Biological Regulators and Homeostatic Agents*. 2017;31:257-262.
109. Tettamanti L, Gaudio RM, Iapichino A, et al. Genetic susceptibility and periodontal disease: A retrospective study on a large italian sample. *ORAL and Implantology*. 2017;10:20-27.
110. Tettamanti L, Gaudio RM, Cura F, et al. Prevalence of periodontal pathogens among Italian patients with chronic periodontitis: A retrospective study on 2992 patients. *ORAL and Implantology*. 2017;10:28-36.
111. Gargari M, Comuzzi L, Bazzato MF, et al. Treatment of peri-implantitis: Description of a technique of surgical 2 detoxification of the implant. A prospective clinical case series with 3-year follow-up. *ORAL and Implantology*. 2015;8:1-11.
112. Grecchi F, Perale G, Candotto V, et al. Reconstruction of the zygomatic bone with Smartbone®: case report. *Journal of biological regulators and homeostatic agents*. 2015;29(3 Suppl 1):42-7.
113. Lauritano D, Avantaggiato A, Candotto V, et al. Insulin activity on dental pulp stem cell differentiation: an in vitro study. *Journal of biological regulators and homeostatic agents*. 2015;29 (3 Suppl 1):48-53.
114. Baj A, Trapella G, Lauritano D, Candotto V, et al. An overview on bone reconstruction of atrophic maxilla: success parameters and critical issues. *Journal of biological regulators and homeostatic agents*. 2016;30(2 Suppl 1):209-215.
115. Baj A, Lo Muzio L, Lauritano D, et al. Success of immediate versus standard loaded implants: a short literature review. *Journal of biological regulators and homeostatic agents*. 2016;30(2 Suppl 1):183-188.
116. Lauritano D, Avantaggiato A, Candotto V, et al. Effect of somatostatin on dental pulp stem cells. *Journal of biological regulators and homeostatic agents*. 2015;29(3 Suppl 1):54-58.
117. Tettamanti L, Bassi MA, Trapella G, et al. Applications of biomaterials for bone augmentation of jaws: clinical outcomes and in vitro studies. *Oral Implantol (Rome)*. 2017 Apr 10;10(1):37-44. eCollection 2017 Jan-Mar.

Correspondence to:

Francesco Carinci

Department of Morphology,
Surgery and Experimental Medicine
University of Ferrara
Via Luigi Borsari 46
44100 Ferrara, Italy

Phone: +39.0532.455874; **Fax:** +39.0532.455876

E-mail: crc@unife.it

Treatment of severe atrophic maxilla with zygomatic implants: a case series

I. BALAN¹, M. DI GIROLAMO², D. LAURITANO³, F. CARINCI⁴

¹ Private practice in Israel

² Department of Clinical Sciences and Translational Medicine, University of Rome "Tor Vergata", Rome, Italy

³ Department of Medicine and Surgery, University of Milan-Bicocca, Milan, Italy

⁴ Department of Morphology, Surgery and Experimental Medicine, University of Ferrara, Ferrara, Italy

SUMMARY

Treatment of severe maxillary atrophy with implants has achieved important successes in recent years. The limit of implant insertion is related to inadequate bone quantity (i.e. height and width). Alveolar bone grafting, sinus lifting and major grafting via Le Fort I osteotomy have been used in the past to restore bone volume prior to implant insertion. However, successes do not always occur and a second stage surgery is necessary in most cases. Immediate loading cannot be performed in all grafted bone. In recent years, a new treatment approach has been proposed by using zygomatic implants. This new technique can provide a better stability to the prosthesis and less morbidity for the patient. Here, a case series of eighteen patients rehabilitated with zygomatic together with standard implants and immediate loading is reported.

Key words: zygomatic implants, bone atrophy, severe resorbed maxilla, implant dentistry, bone.

Introduction

Treatment of severe maxillary atrophy with implants has achieved important successes in recent years (1, 2). The limit of implant rehabilitation is represented by inadequate bone height and width for which the treatment of severe atrophy shows still difficulties from the surgical and functional point of view (3-11). The severe atrophy of both maxilla and mandible causes further difficulties related to an inverse relationship between two jaws. Therefore, the correction of improper relationship of the bony bases is more complicated than a simple alveolar atrophy. When an edentulous maxilla is reabsorbed, the retention area of the total denture becomes narrower and shorter, since the anterior surface moves superiorly and dorsally, creating a form of the alveolar bone crest similar to a knife blade. The resorption of the edentulous maxilla determines a progressive loss of bone height, thus reducing the volume of bone available for fixture placement and decreasing the bone quality, consequently increasing the risk of implant failure. When these phenomena happen, the vertical resorption of alveolar bone increases the inter-arch space. As the projection of the maxilla decreases in the sagittal plane, the spatial relationship between the maxilla and mandible changes, thus creating a pseudo-prognathism. This discrepancy between the two jaws creates problems both in the rehabilitation with removable or fixed prostheses. The jaws are resorbed till the muscle insertion causes a dislocation of the prosthesis and inhibits an adequate insertion of the implants. The combination of the loss

of sagittal projection of the maxilla and a decrease in vertical height, results in a collapse of the soft tissues of the lower third of the face, therefore the patient experiences an aged expression, and the quantity of residual bone is unfavourable to the retention of the denture. Various processes have been designed to increase the volume of the alveolar ridges and allow an adequate reconstruction of the dentition. Orthodontic surgical techniques have just been developed to restore the jaws in a correct skeletal position when a malocclusion occurs in dentate patients. The same procedures, such as the maxillary Le Fort I osteotomy, can be used in edentulous patients to correct the discrepancies between the jaws and restore an implant-supported dentition. Bone grafting procedures are frequently used to increase bone volume and place the implants in the same surgical time (12, 13). Sinus lifting and alveolar bone grafting are minor and well-known techniques in oral surgery.

In recent years, a new treatment has been proposed with zygomatic implants. This new technique can provide a better stability to the prosthesis and less morbidity for the patient. Here, a series of 18 patients treated with zygomatic implant in combination with standard fixture (Noris Medical, Israel) are reported and clinical outcome discussed.

Materials and methods

A series of eighteen patients with severe atrophy of maxilla were admitted at the Balan Clinic (Kiryat Yam, Israel) in the period between August and December 2013. There were 10 females and 8 males with a median age of 62 (min-max 36-86) all with general advanced periodontitis, most with complete edentulness. Half of patients had good general health and none was pregnant. Three patients had hypothyroidism, five have diabetes, one was affected by prostate cancer and one by cervical cancer. The protocol is similar to that previously reported (14).

The surgery was performed under local anaesthesia with intravenous conscious sedation after antibiotic prophylaxis with amoxicillin and clavulanic acid (2 g) two hours before surgery.

Pre-operative medication protocol

One hour prior to dental surgery: 1 g Augmentin (amoxicillin and clavulanate potassium) for patients who are allergic to penicillin - 600 mg Dalacin (clindamycin); 12 mg dexamethasone (not for diabetics); 20 mg vaben (oxazepam); 100 mg Otarex (hydroxyzine hydrochloride); 2 tab narocin 275 mg (naproxen); 1 cap Losec 20 mg (omeprazole); probiotic.

Surgical protocol (Figures 1-6)

A palatal incision is made in the maxillary crest with a bilateral vertical posterior releasing incisions (like Le Fort I exposure). A muco-periosteal flap was reflected to expose the alveolar crest, the piriform opening, the central and posterior part of the zygomatic complex, the infraorbital nerve emergence and the lateral wall of the maxillary sinus. The retractor was then placed to separate the cheek, to guide the osteotomy and to protect the soft tissue from drilling. The compression of the infraorbital nerve with retractor must be avoided as well as the invasion of the orbit. Implant sites were prepared and guided positioning of the pterygoid and standard implants.

Corticotomy of the anterolateral wall of the maxillary sinus was done. The antrostomy was performed with a diamond ball drill with a progressive diameter preserving and slightly detaching the sinus membrane.

Following the inclination predisposed by the slot, the zygomatic implant beds were prepared under visual control using progressive-diameter drills with extra-oral access and alveolar zygomatic arch direction.

Then zygomatic implants (Noris Medical, Israel) were then screwed manually. Afterwards standard implants were inserted in premaxilla.

The definitive prosthesis was screwed using preformed abutments. Haemostasis control was followed by suturing of the surgical field.

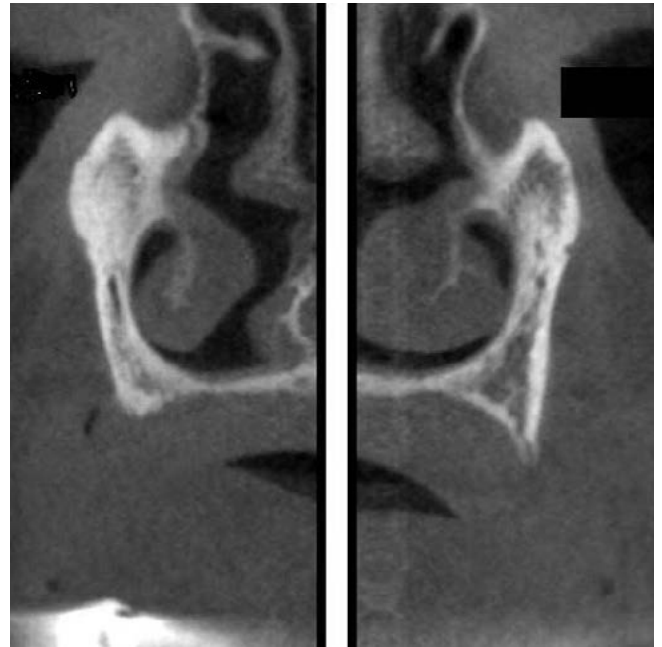


Figure 1

Right and left CT showing the pre-surgical maxillary atrophy.

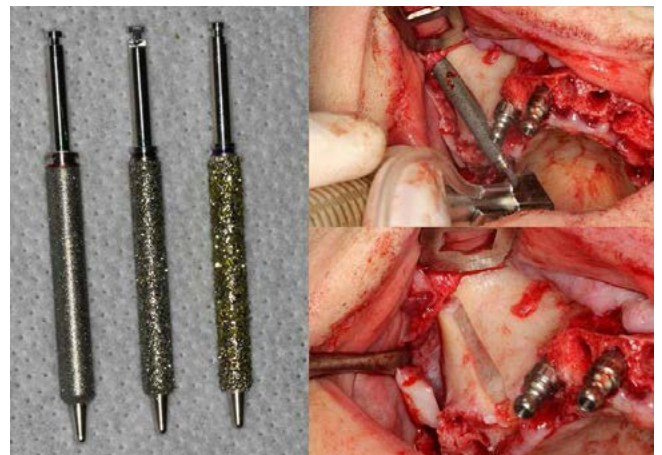

Figure 2

Drills and surgical preparation of the grooves for implant placement in the lateral wall of maxillary sinus.

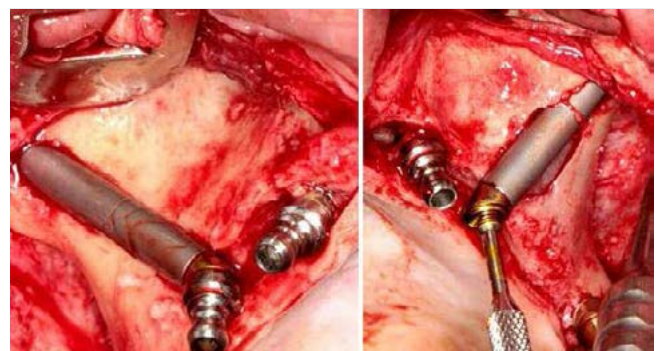


Figure 3

Right and left zygomatic implants inserted.

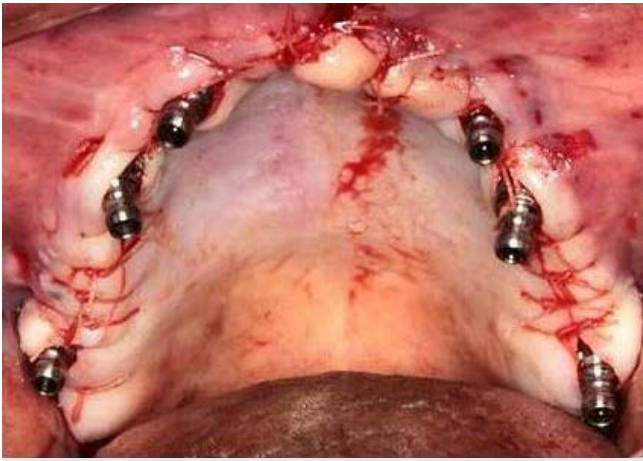

Figure 4

The operation field at the end of suture stitching.

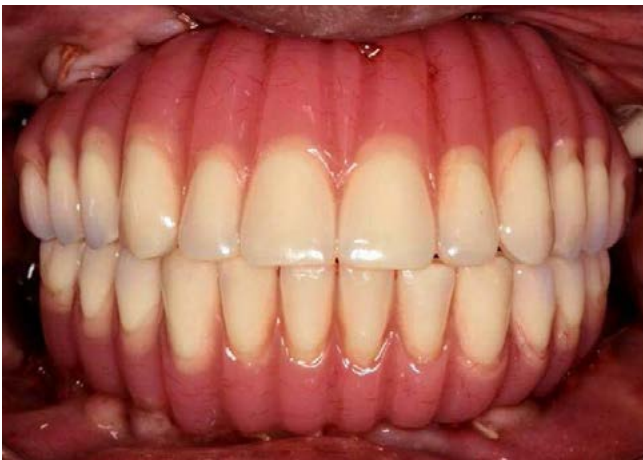

Figure 5

Fixed dentures in place.

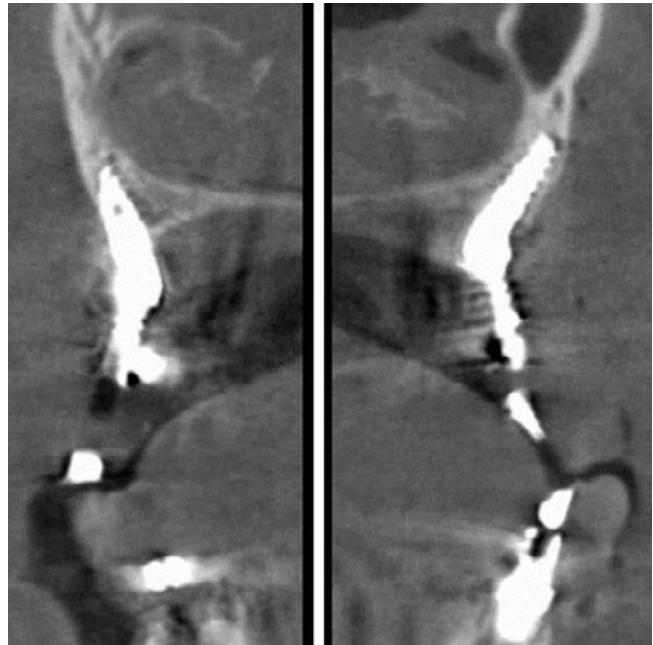


Figure 6

Right and left CT showing zygomatic implants.

Results

There were 10 females and 8 males with a median completed on all the implants with no adverse event reported by the patient. age of 62 (min-max 36-86). Half of them have a systemic diseases or major illness. A total of 29 zygomatic implants (Noris Medical, Italy) was inserted. In six cases ZI were single and place only in one side of upper maxilla. No one implant were lost after 12 months of follow-up. Provisional prosthesis was delivered the same day of surgery and patients have a great improvement in their quality of life.

Discussion

Maxillary atrophy is a hot topic of current implantology. Several different options were proposed over time, starting from simpli alveolar grats and sinus lifting to Le Fort I osteotomy combined with inlay bone block.

Zygomatic implants, introduced by Branemark in 1997 for the prosthetic rehabilitation of patients with serious and extended defects of the jaws caused by post-oncological resections, trauma or congenital malformations, have proven over the years a valid alternative in the treatment of atrophy of the jaws, presenting high success rates (96% in 10 years) (15). The technique used in our study, implies the insertion of implants in the frontal portion of zygomatic bone, and the residual alveolar-basal bone as anchorage of standard implants, decreasing the biological cost of surgery, and improving the postoperative morbidity and the healing time. In the majority of cases, it is possible a rehabilitation of the maxilla with a denture, with 2 zygomatic implants in adjunction to traditional implantology of the pre-maxilla. Besides the success rate of zygomatic implants is above 80%, peri-implantitis

Post-operative medication protocol

Antibiotics: Moxypen (amoxicillin) 500 mg 3 times a day/ Augmentin 500/875 3 or 2 times a day/ Dalacin 300 mg 3 times a day, for 7 days; 0.12% chlorhexidine rinse for a month; 400 mg ibuprofen every 4 hours, if needed; dexamethasone, starting with 12 mg daily and reducing 2 mg each following day, Botox (dilute according to manufacturer's instructions, divide to 6 doses, inject to the Masseter muscle in 3 points along the muscle, in each side).

By using the above mentioned technique a total of 29 zygomatic implants were inserted in the second pre-molar area of upper (left and/or right) maxilla. Additional 99 standard implants were inserted to restore the upper jaw (mean 5.5 implants per patient).

All patients agree to follow a strict oral hygiene protocol and recall. The post-operative period was uneventful and no soft tissue down-growth to interfere with the bone healing. The rehabilitation was successfully completed on all the implants with no adverse event reported by the patient.

may occurs in zygomatic rehabilitations also (16-21). Peri-implantitis and periodontal disease spring from bacterial infection that activates a cytokines cascade leading to inflammation and bone loss (22-25). In addition, the patient-related susceptibility is a critical factor for disease onset.

So, every factor favouring oral biofilm formation (poor oral hygiene), host defence capability (smoking habit, excessive alcohol consumption, genetic traits, history of periodontitis, use of bisphosphonates), might favour developing of peri-implantitis and periodontal disease in zygomatic implants, which diagnosis and treatment require dentist's engagement (26, 27).

Recently zygomatic implant solution has become popular since patients ask for therapies that offer a good final result while at the same time reduce costs, healing time and the temporary inability to work, as is the case of major grafting surgeries. So this procedure, that avoid big surgical field both for collecting and grafting bone, reduces the morbidity of treatment especially if one consider the advanced age of patients that request this treatment or type of pathology that determines the surgical indications such post-traumatic sequelae, post-oncological resections and severe malformations. In addition, bone grafting usually requires some time before fixtures and prosthesis can be loaded with consequent discomfort and limitation to social life.

In the recent literature there are few studies describing zygomatic implants to restore severe atrophic maxilla based on a large case series. Early publications on zygomatic implants were presented as case reports (28-38).

By considering our large case series, it became evident that the reconstruction of an atrophic jaw with zygomatic implants provide a good fine prosthetic solution while reduce the disadvantages related to a major surgery. In fact, it not only allow an immediate loading prosthetic rehabilitation but also restore the correct maxillary relationships and improve the aesthetics of the face. Among the most important advantages in using zygomatic implants are a more retentive denture-bearing ridge and a correct relationship between the two jaws. The use of zygomatic implants prevents problems related to potential bone resorption which usually happen after grafting.

In conclusion, oral rehabilitation of the maxilla with zygomatic implants can be used in selected patients, significantly shortened the time of rehabilitation with a reduction of adverse effects.

References

- Schwartz JS, Tajudeen BA, Adappa ND, et al. Modified endoscopic medial maxillectomy for zygomatic implant salvage. *Allergy Rhinol (Providence)*. 2016;7: 147-150.
- Atalay B, Doganay O, Saracoglu BK, et al. Clinical Evaluation of Zygomatic Implant-Supported Fixed and Removable Prosthesis. *J Craniofac Surg*. 2017;28:185- 189.
- Baj A, Trapella G, Lauritano D, et al. An overview on bone reconstruction of atrophic maxilla: success parameters and critical issues. *J Biol Regul Homeost Agents*. 2016;30:209-215.
- Grecchi F, Perale G, Candotto V, et al. Reconstruction of the zygomatic bone with smartbone®: Case report. *Journal of Biological Regulators and Homeostatic Agents*. 2015;29:42-47.
- Lauritano D, Avantaggiato A, Candotto V, et al. Insulin activity on dental pulp stem cell differentiation: An in vitro study. *Journal of Biological Regulators and Homeostatic Agents*. 2015;29:48-53.
- Tettamanti L, Andreasi Bassi M, Trapella G, et al. Applications of biomaterials for bone augmentation of jaws: Clinical outcomes and in vitro studies. *ORAL and Implantology*. 2017;10:37-44.
- Baj A, Sollazzo V, Lauritano D, et al. Lights and shadows of bone augmentation in severe resorbed mandible in combination with implant dentistry. *Journal of Biological Regulators and Homeostatic Agents*. 2016;30:177-182.
- Lauritano D, Avantaggiato A, Candotto V, et al. Effect of somatostatin on dental pulp stem cells. *Journal of Biological Regulators and Homeostatic Agents*. 2015; 29:54-58.
- Baj A, Muzio LL, Lauritano D, et al. Success of immediate versus standard loaded implants: A short literature review. *Journal of Biological Regulators and Homeostatic Agents*. 2016;30:183-188.
- Calcaterra R, Di Girolamo M, Mirisola C, et al. Effects of Repeated Screw Tightening on Implant Abutment Interfaces in Terms of Bacterial and Yeast Leakage in Vitro: One-Time Abutment Versus the Multiscrewing Technique. *Int J Periodontics Restorative Dent*. 2016;36:275-280.
- Calcaterra R, Pasquantonio G, Vitali LA, et al. Occurrence of Candida species colonization in a population of denture-wearing immigrants. *Int J Immunopathol Pharmacol*. 2013;26:239-246.
- Wang F, Monje A, Lin GH, et al. Reliability of four zygomatic implant-supported prostheses for the rehabilitation of the atrophic maxilla: a systematic review. *Int J Oral Maxillofac Implants*. 2015;30:293-298.
- Wen H, Guo W, Liang R, et al. Finite element analysis of three zygomatic implant techniques for the severely atrophic edentulous maxilla. *J Prosthet Dent*. 2014;111: 203-215.
- Grecchi F, Busato A, Grecchi E, et al. Surgically guided zygomatic and pterygoid implants - a no-grafting rehabilitation approach in severe atrophic maxilla - A case report 2013;1.
- Tolman DE, Desjardins RP, Jackson IT, et al. Complex craniofacial reconstruction using an implant-supported prosthesis: case report with long-term follow-up. *Int J Oral Maxillofac Implants*. 1997;12:243-251.

16. Lopez MA, Andreasi Bassi M, Confalone L, et al. Clinical outcome of 215 transmucosal implants with a conical connection: a retrospective study after 5-year follow-up. *J Biol Regul Homeost Agents*. 2016;30:55- 60.
17. Andreasi Bassi M, Lopez MA, Confalone L, et al. Clinical outcome of a two-piece implant system with an internal hexagonal connection: a prospective study. *J Biol Regul Homeost Agents*. 2016;30:7-12.
18. Lopez MA, Andreasi Bassi M, Confalone L, et al. Retrospective study on bone-level and soft-tissue-level cylindrical implants. *J Biol Regul Homeost Agents*. 2016;30:43-48.
19. Lopez MA, Andreasi Bassi M, Confalone L, et al. The influence of conical plus octagonal internal connection on implant survival and success rate: a retrospective study of 66 fixtures. *J Biol Regul Homeost Agents*. 2016;30:49-54.
20. Andreasi Bassi M, Andrisani C, Lopez MA, et al. Endoscopically controlled hydraulic sinus lift in combination with rotary instruments: one-year follow-up of a case series. *J Biol Regul Homeost Agents*. 2016;30 (S2):21-28.
21. Brunelli G, Carinci F, Zollino I, et al. Peri-implantitis. A case report and literature review. *European Journal of Inflammation*. 2012;10:1-5.
22. Carinci F, Lauritano D, Cura F, et al. Prevention of bacterial leakage at implant-Abutment connection level: An in vitro study of the efficacy of three different implant systems. *Journal of Biological Regulators and Homeostatic Agents*. 2016;30:69-73.
23. Scapoli L, Girardi A, Palmieri A, et al. Quantitative Analysis of Periodontal Pathogens in Periodontitis and Gingivitis. *J Biol Regul Homeost Agents*. 2015;29:101- 110.
24. Lauritano D, Martinelli M, Mucchi D, et al. Bacterial load of periodontal pathogens among Italian patients with chronic periodontitis: A comparative study of three different areas. *Journal of Biological Regulators and Homeostatic Agents*. 2016;30:149-154.
25. Lauritano D, Cura F, Candotto V, et al. Periodontal Pockets as a Reservoir of *Helicobacter Pylori* Causing Relapse of Gastric Ulcer: A Review of the Literature. *J Biol Regul Homeost Agents*. 2015;29:123-126.
26. Lauritano D, Muzio LLO, Gaudio RM, et al. The ecological catastrophe of oral diseases: A possible link between periodontitis and protozoa. *Journal of Biological Regulators and Homeostatic Agents*. 2016;30: 143-147.
27. Lauritano D, Muzio LL, Gaudio RM, et al. Why should patients with systemic disease and tobacco smokers go to the dentist? *Journal of Biological Regulators and Homeostatic Agents*. 2016;30:135-141.
28. Hinze M, Vrielinck L, Thalmair T, et al. Zygomatic implant placement in conjunction with sinus bone grafting: the "extended sinus elevation technique." a case-cohort study. *Int J Oral Maxillofac Implants*. 2013;28: e376-385.
29. Bothur S, Kindberg H, Lindqvist J. The positions of implant heads in relation to the fixed dental prosthesis: a comparison of multiple zygomatic implants with standard implants for the reconstruction of the atrophic maxilla. *Int J Oral Maxillofac Implants*. 2012;27:664- 670.
30. Penarrocha M, Garcia B, Marti E, et al. Rehabilitation of severely atrophic maxillae with fixed implant-supported prostheses using zygomatic implants placed using the sinus slot technique: clinical report on a series of 21 patients. *Int J Oral Maxillofac Implants*. 2007; 22:645-650.
31. Bedrossian E, Rangert B, Stumpel L, et al. Immediate function with the zygomatic implant: a graftless solution for the patient with mild to advanced atrophy of the maxilla. *Int J Oral Maxillofac Implants*. 2006;21:937- 942.
32. Farzad P, Andersson L, Gunnarsson S, et al. Rehabilitation of severely resorbed maxillae with zygomatic implants: an evaluation of implant stability, tissue conditions, and patients' opinion before and after treatment. *Int J Oral Maxillofac Implants*. 2006;21:399-404.
33. Balshi TJ, Wolfinger GJ, Petropoulos VC. Quadruple zygomatic implant support for retreatment of resorbed iliac crest bone graft transplant. *Implant Dent*. 2003; 12:47-53.
34. Gasparini G, Boniello R, Lafori A, et al. Navigation System Approach in Zygomatic Implant Technique. *J Craniofac Surg*. 2017;28:250-251.
35. Gonzalez-Garcia R, Monje A, Moreno-Garcia C, et al. Endoscopically-Assisted Zygomatic Implant Placement: A Novel Approach. *J Maxillofac Oral Surg*. 2016;15:272-276.
36. Dawood A, Collier J, Darwood A, et al. The reverse zygomatic implant: a new implant for maxillofacial reconstruction. *Int J Oral Maxillofac Implants*. 2015; 30:1405-1408.
37. Camargos Gde V, Do Prado CJ, Saad PA, et al. Zygomatic Implant Options for the Atrophic Maxilla: Case Report. *Dent Today*. 2015;34:64-65.
38. Pia F, Aluffi P, Crespi MC, et al. Intraoral transposition of pedicled temporalis muscle flap followed by zygomatic implant placement. *J Craniofac Surg*. 2012; 23:e463-465.

Correspondence to:

Dorina Lauritano, DDS
 Department of Medicine and Surgery
 University of Milano Bicocca
 Via Cadore 48
 20052 Monza, Italy
 Phone: +39.0392332301
 Fax: +39. 03923329892
 E-mail: dorina.lauritano@unimib.it



Article

A Novel Guided Zygomatic and Pterygoid Implant Surgery System: A Human Cadaver Study on Accuracy

Francesco Grecchi ¹, Luigi V. Stefanelli ², Fabrizio Grivetto ³, Emma Grecchi ⁴, Rami Siev ⁵, Ziv Mazor ⁵, Massimo Del Fabbro ^{1,6}, Nicola Pranno ^{7,*}, Alessio Franchina ⁸, Vittorio Di Lucia ², Francesca De Angelis ⁷ and Funda Goker ⁶

- ¹ IRCCS (Istituto di Ricovero e Cura a Carattere Scientifico) Orthopedic Institute Galeazzi, Via Riccardo Galeazzi, 4, 20161 Milano, Italy; dr.grecchi@tiscali.it (F.G.); massimo.delfabbro@unimi.it (M.D.F.)
- ² Private Practice, Viale Leonardo Da Vinci 256, 00145 Rome, Italy; gigistef@libero.it (L.V.S.); vittorio.dilucia@gmail.com (V.D.L.)
- ³ Maggiore della Carità di Novara, Università degli studi del Piemonte Orientale “Amedeo Avogadro”, Reparto di Chirurgia Maxillo-Facciale, C.so Mazzini 18, 28100 Novara, Italy; grivettof@gmail.com
- ⁴ Private Practice, Via G. Boccaccio 34, 20123 Milano, Italy; emma.grecchi@gmail.com
- ⁵ Private Practice, Tel Aviv Basel St 46, Tel Aviv 6100000, Israel; ramisiev@gmail.com (R.S.); drmazor1@gmail.com (Z.M.)
- ⁶ Department of Biomedical, Surgical and Dental Sciences, Università degli Studi di Milano, 20122 Milano, Italy; funda.goker@unimi.it
- ⁷ Department of Oral and Maxillo Facial Science, Sapienza University of Rome, Via Caserta 6, 00161 Rome, Italy; francesca.deangelis@uniroma1.it
- ⁸ Private Practice, Via Legione Gallieno 44, 36100 Vicenza, Italy; alessiofranchina@icloud.com
- * Correspondence: nicola.pranno@uniroma1.it; Tel.: +39-06-49976651



Citation: Grecchi, F.; Stefanelli, L.V.; Grivetto, F.; Grecchi, E.; Siev, R.; Mazor, Z.; Del Fabbro, M.; Pranno, N.; Franchina, A.; Di Lucia, V.; et al. A Novel Guided Zygomatic and Pterygoid Implant Surgery System: A Human Cadaver Study on Accuracy. *Int. J. Environ. Res. Public Health* **2021**, *18*, 6142. <https://doi.org/10.3390/ijerph18116142>

Academic Editor: Paul B. Tchounwou

Received: 3 May 2021

Accepted: 4 June 2021

Published: 7 June 2021

Publisher's Note: MDPI stays neutral with regard to jurisdictional claims in published maps and institutional affiliations.



Copyright: © 2021 by the authors. Licensee MDPI, Basel, Switzerland. This article is an open access article distributed under the terms and conditions of the Creative Commons Attribution (CC BY) license (<https://creativecommons.org/licenses/by/4.0/>).

Abstract: The aim of this human cadaver study was to assess the accuracy of zygomatic/pterygoid implant placement using custom-made bone-supported laser sintered titanium templates. For this purpose, pre-surgical planning was done on computed tomography scans of each cadaver. Surgical guides were printed using direct metal laser sintering technology. Four zygomatic and two pterygoid implants were inserted in each case using the guided protocol and related tools. Post-operative computed tomography (CT) scans were obtained to evaluate deviations between the planned and inserted implants. Accuracy was measured by overlaying the real position in the post-operative CT on the virtual presurgical placement of the implant in a CT image. Descriptive and bivariate analyses of the data were performed. As a result, a total of 40 zygomatic and 20 pterygoid implants were inserted in 10 cadavers. The mean deviations between the planned and the placed zygomatic and pterygoid implants were respectively (mean \pm SD): $1.69^\circ \pm 1.12^\circ$ and $4.15^\circ \pm 3.53^\circ$ for angular deviation. Linear distance deviations: $0.93 \text{ mm} \pm 1.23 \text{ mm}$ and $1.35 \text{ mm} \pm 1.45 \text{ mm}$ at platform depth, $1.35 \text{ mm} \pm 0.78 \text{ mm}$ and $1.81 \text{ mm} \pm 1.47 \text{ mm}$ at apical plane, $1.07 \text{ mm} \pm 1.47 \text{ mm}$ and $1.22 \text{ mm} \pm 1.44 \text{ mm}$ for apical depth. In conclusion, the surgical guide system showed accuracy for all the variables studied and allowed acceptable and accurate implant placement regardless of the case complexity.

Keywords: zygomatic implant; guided surgery; computer aided implantology; navigation; dynamic navigation; surgical guides; surgical templates; pterygoid implants; CAD/CAM; accuracy; guidance

1. Introduction

The goal of every surgical procedure, including implantology, is to achieve the planned result after carefully evaluating the cost-benefit ratio. Many variables can be influential on the design of the project and the accuracy of the outcomes. The accuracy of the diagnostic phase, the quality of the materials used, the operator's skills and expertise are all essential factors, and together with the advances in technology and the progressive improvement in the development of the devices used, allow one to achieve optimal clinical outcomes [1–4].

Currently, there is a continuous evolution and improvement in order to overcome operators' limitations and to minimize the gap of precision placement between expert operators and professionals with less experience in advanced surgical techniques [5–10]. In the medical field, one of the first examples dates back to the late 1970s and is the well-known advent of the Russian mechanical staplers for gastrointestinal surgery, which allowed unexperienced surgeons in peripheral hospitals to achieve results as excellent as experienced operators [11].

Currently, dynamic/static guided surgery is one of the hottest research topics in the field of conventional, pterygoid and zygomatic implantology [5,12–16]. The static guided surgery systems utilize surgical templates to guide the drilling process [15]. Dynamic navigation options plan and calibrate the ideal position of the implants by optical reference markers placed over the patient, and insert implants in accordance with the three-dimensional (3-D) image on navigation system using surgical instruments by means of a tracking system array [15,17–19]. Both of these guided surgery navigation methods for conventional dental implant placement have been widely evaluated and reported in literature with high accuracy levels as results [5,20–22].

In the guided implant placement, a pre-operative virtual plan and an accurate surgical diagnosis are crucial to evaluate the anatomical structures, in order to minimize the intra/post-operative complications and to improve the treatment outcomes [5,23–27]. Today, with the help of technological developments, it is possible to assess the 3-D anatomy of the patients and pre-operatively plan the ideal position of the implants, using the data provided by Computed Tomography (CT) and adequate surgical software programs [5,12–15].

The development of the imaging technologies known as Cone Beam Computed Tomography (CBCT) has led to a significant improvement in the pre-surgical planning, since it provides three-dimensional (3-D) data of the patient's anatomy with less radiologic dose than Computed Tomography (CT). In addition, it is possible today to virtually place the dental implants in their ideal position, through various software programs, using the DICOM (Digital Imaging and Communication in Medicine) data provided by CT scans [5,23–30].

Computer-guided implant placement represents several advantages when compared to free-hand surgery, including minimally invasive surgery with a reduction of operative time and steps. Additionally, these protocols allow prosthetic-driven implant placement with more accurate results and simplified procedures, making them applicable even by less experienced clinicians [6,27,31–33]. Currently, the majority of the reports in literature involve studies with high level experienced operators. There are only a limited number of model-based studies investigating whether the surgical experience has an impact on implant placement accuracy while using drilling guides [34,35]. According to the literature, there is an improvement in the precision of computer-guided implant placements compared to conventional ones, however the reports evaluating the results between inexperienced and skilled surgeons are not consistent, although similar values of errors were found [14,35,36].

Zygomatic and pterygoid implants were suggested as an alternative treatment to massive grafting surgery in the severe atrophic maxillary. The typical zygomatic implant length, ranging from 35 to 60 mm, and the proximity to many anatomic limitations such as vessels, nerves and structures such as the orbit, makes this procedure a challenging one and exposes the operators to higher risks when compared with conventional dental implantology [37]. Stella and Warner in 2000 described the sinus slot technique to prepare the site between the base of the zygoma to the bone crest, avoiding injuries to the sinus membrane. This approach also helped to respect the ideal three-dimensional zygomatic implant site preparation as the following drills can work free from any deviation generated by the bone crest remnants [38]. One of the main problems with guided zygomatic implant insertion is the application of the methods deriving from traditional implantology (which is based on a two-dimensional view of the problem, to zygomatic implants, whose vision must be strictly kept in mind in the third angular dimension) [39,40]. A dedicated system for zygomatic implant placement based on a bone-supported surgical template seems to be

reasonable to increase the safety and the accuracy. It is still difficult to achieve the correct driven angle of zygomatic osteotomies, and additional researches with randomized clinical trials are needed to assess the predictability of these procedures [13,40,41].

The aim of this cadaver study was to analyze zygomatic and pterygoid implant deviations when applying a novel surgical guide protocol for ZI/PI surgery, as an alternative to free hand placement. The accuracy was evaluated by merging the pre-operative and post-operative CT scan datasets to assess the effect of this novel surgical guide on implant deviations.

2. Materials and Methods

This study evaluates accuracy of zygomatic and pterygoid implant insertions, during a practical training on human cadavers with unexperienced surgeons (in zygomatic implant insertions). A total of 4 zygomatic and 2 pterygoid implants were placed in each cadaver's head (10 cadaver heads in total), using DMLS (Direct Metal Laser Sintering) 3D printed titanium surgical templates.

The cadavers were donated by individuals for their use in scientific purposes and an official laboratory permission to work on cadavers was obtained from Italian competent authority (Prot. Nr 08-05 Maggio 2021). Common rules/guidelines applied in European Union which was used in this study while working on cadavers were as follows:

- Cadavers were treated with respect at all times
- A professional attitude was applied during all lab procedures
- Human cadaver material was not removed from the laboratory under any circumstances.
- No photographs or video cameras were used in the laboratory
- Only health professionals enrolled in the course and instructors entered the lab
- All cadaver material remained at the assigned dissection table
- Incomplete dissections or intentional destruction of dissected structures was considered unprofessional behavior and work area was kept as clean as possible.

The guide design was performed by a clinical plan based on the CT scan of each maxilla. The CT scan Gantry tilt was 0° and slices thickness were 0.4 mm. After implant insertions, a new CT scan was carried out to compare deviations between planned and achieved implants. Accuracy was measured by overlaying the real implant position in the postoperative CT on the virtual presurgical placement of the implants in the pre-operative CT scan. The accuracy evaluation involved angular and linear (coronal, apical and depth) deviations.

2.1. Presurgical Procedure

In brief, a pre-operative CT scan was taken for each cadaver and the resulting DICOM files were segmented, forming STL (Standard Triangulation Language) files. Using a dedicated planning software, both zygomatic (ZI) and pterygoid implants (PI) were planned (Figure 1) and the surgical templates were designed (Figures 2 and 3). Each STL file of the maxillary bone with planned zygomatic and pterygoid implants became the baseline for the post-operative comparison. A post-operative CT scan of each cadaver's head with implants was taken after the surgery.

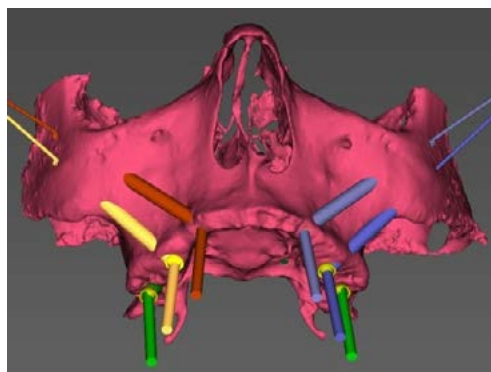


Figure 1. 3D view of the pre-surgical plan for position of the zygomatic and pterygoid implants.

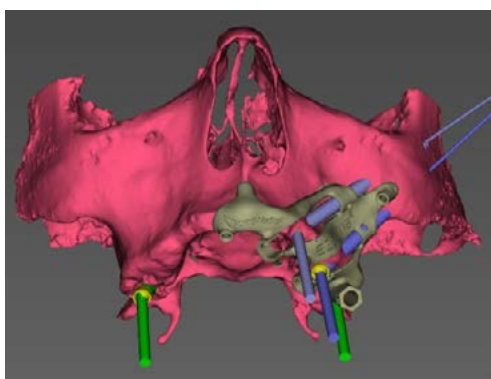


Figure 2. 3D view of the pre-surgical plan with the surgical guide on the left side.

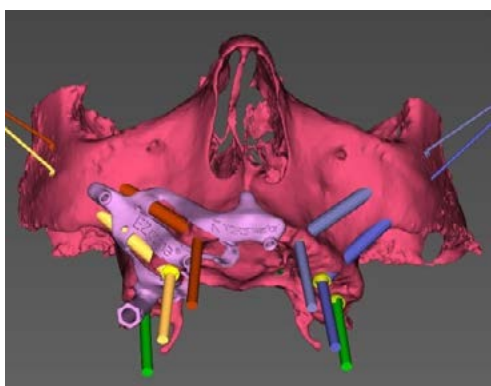


Figure 3. 3D view of the pre-surgical plan with the surgical guide on the right side.

The DICOM images of the post-operative CT were uploaded in a dedicated software (mimics Medical 19.0, Materialise Dental, Leuven, Belgium). Segmentation based on tissue density was carried out in order to separate implants from the surrounding bone.

The STL files of the maxillary bone with the planned implants, which were obtained from the first CT scan, were uploaded into the software. The superimposition of the pre-op and post-op CT images was achieved by using the best fit alignment tool (Figures 4 and 5).

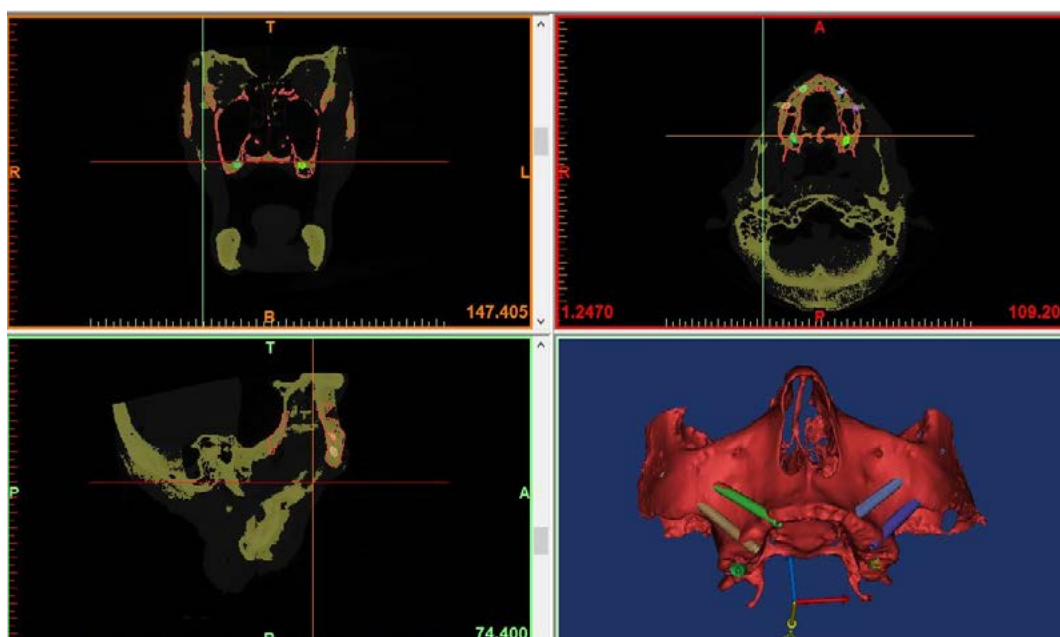


Figure 4. Pre-operative and post-operative CT-scans superimposed and aligned for evaluation of planned and placed implants.

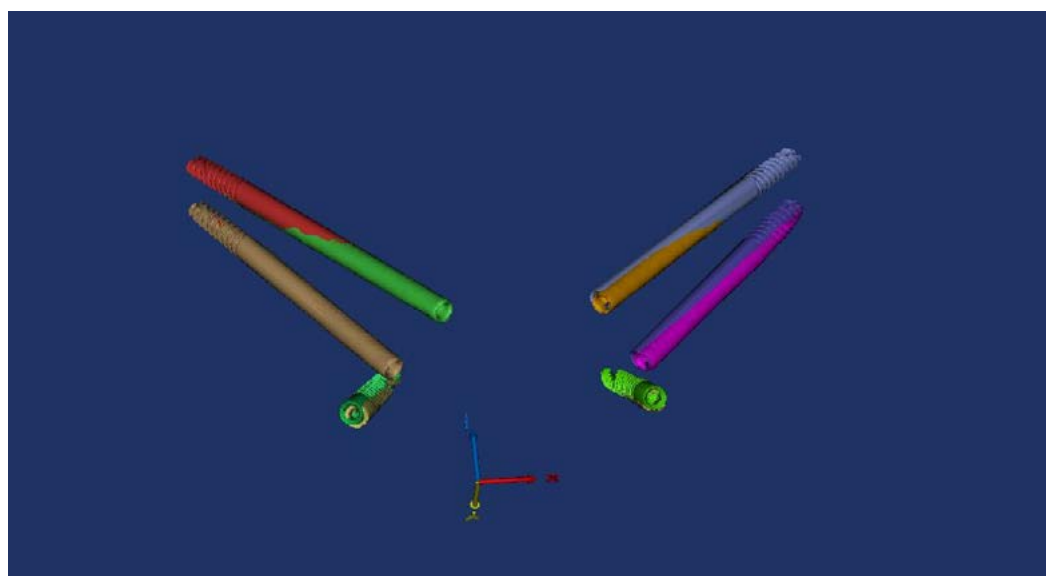


Figure 5. Superimposition of the pre-surgical plan and the post-operative placement of the implants showing minimal deviations.

The planned and inserted implants were considered as cones with a base and an apex and their spatial coordinates (the center of the base and the apex) were registered by using a dedicated software (3-matic Medical 11.0, Materialise Dental, Leuven, Belgium) and were exported in an excel sheet in order to calculate coronal, apical, depth and angular deviations.

A diagnostic CT scan was performed to evaluate the residual maxillary bone anatomy in order to determine the location of ZI/PI sites using a 3D planning software. The implants' angulations, positions, and dimensions as well as the inclinations of the multi-

unit-abutments (MUA) were carried out using a dedicated implant surgical software (EZplan Real Guide, NORIS medical).

The ZIs were planned with an extra-sinus path with a lateral upward angulation of 45–60 degrees from the vertical axis. The implant's apex was positioned to pass through the zygomatic bone in a bi-cortical manner in order to obtain the maximum anchorage. PIs entry points were designed to be 10–12 mm posterior to the tuberosity and the angulation was adjusted to join the pterygoid medial plate.

Once the surgical plan was defined, the data set allowed to design a CT-derived bone supported surgical guide with a novel layout and showed an optimal stability. To do that, the designed guide was exported as a STL (standard triangulation language) file to be fabricated using 3D printing processes.

2.1.1. EZgoma Principle

The EZgoma guide is an apparatus for the placement of zygomatic implants previously planned by a dedicated software. The guide provided two separate supports for two ZIs on one side (Figure 6). Each support had a cylindric form divided into two parts (upper support on the buccal part and lower support on the palatal part). The lower support worked with the upper support creating an efficient system to avoid the bending momentum due to the rotational movement of the bur during drilling, which also allowed the alignment of the burs to the cylindric body.

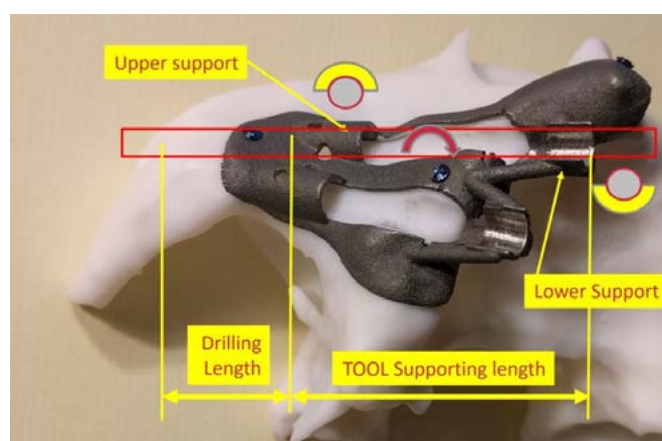


Figure 6. The 3D printed titanium surgical guide provides the support for the burs. Attention is paid to the supports which are designed in two parts, as upper and lower, in order to allow the surgeon to have a comfortable approach and to avoid a bur's stop.

2.1.2. EZgoma Procedure

A palatal incision was carried out in the maxillary soft tissues with bilateral vertical posterior releasing incisions. The muco-periosteal flap was elevated to expose the alveolar crest, the piriform aperture, the lateral wall of the maxillary sinus, the infraorbital nerve emergence, the tuber maxilla, the central and the posterior part of the zygomatic complex (Figure 7).

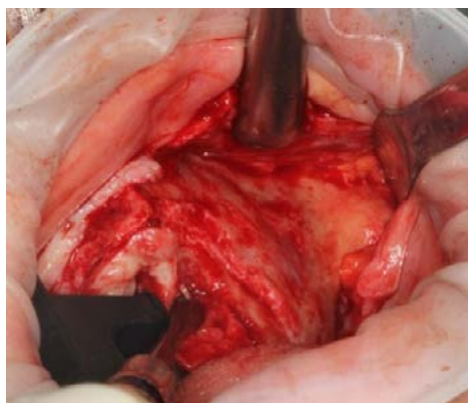


Figure 7. Palatal incision allowed a wide surgical access.

The bone-supported surgical drill guide was placed and fixed with three 1.6 mm diameter mono-cortical osteosynthesis screws. These screws provided a stable fitting of the guide to the bone, preventing any tilting, which is crucial for the success of the guided surgery (Figure 8).

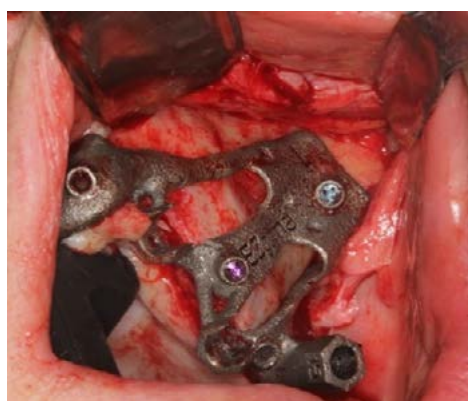

Figure 8. The guide perfectly fitted on the maxillary bone with 3 screws.

2.1.3. Pterygoid Implant Protocol

When pterygoid implants are planned in addition to zygomatic ones, it is recommended to start the procedure with pterygoid implants placement in order to use the implants as anchor pin, in addition to the screw fixation.

The pterygoid osteotomy was performed by a long 2.8 mm diameter drill, used with a reduction spoon placed in a long sleeve defining the planned drilling direction. The marks on the drills were used to check the drilling depth (Figure 9).

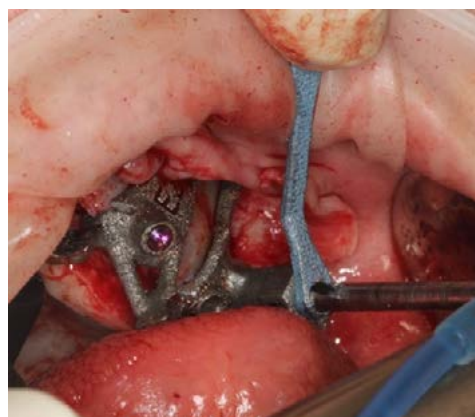

Figure 9. The first step was the pterygoid implant preparation, performed with the aid of a reduction spoon and a calibrated drill.

The implant was seated by a driver through the guide (Figure 10) until the driver stopped on the sleeve. The planned orientation of the implant was achieved by aligning the hex of the driver with the hex of the sleeve (Figure 11).

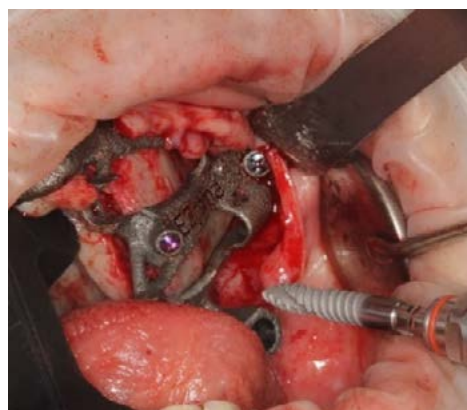

Figure 10. The placement of the pterygoid implant increased the guide's stability for the following zygomatic implant site preparations.

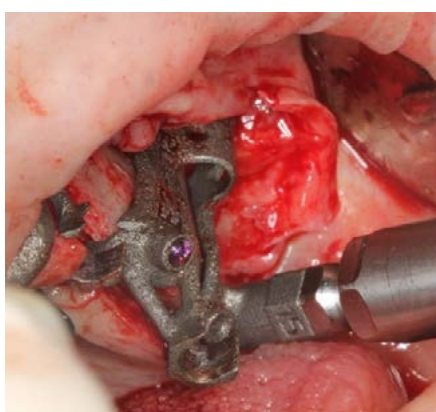

Figure 11. Pterygoid implant was placed by an implant mount that allow to position the implant as planned.

2.1.4. Zygomatic Protocol

After the surgical guide was fixed, the implant site preparation continued with a spherical diamond bur ($\varnothing 4.2$ mm) to create a notch in the bone (Figure 12) facilitating the bone approach of the next cylindric diamond bur (Figure 13).

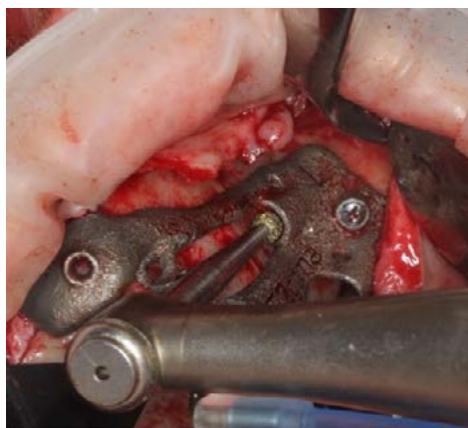


Figure 12. Round diamond bur was used to perform the primary corticotomy.

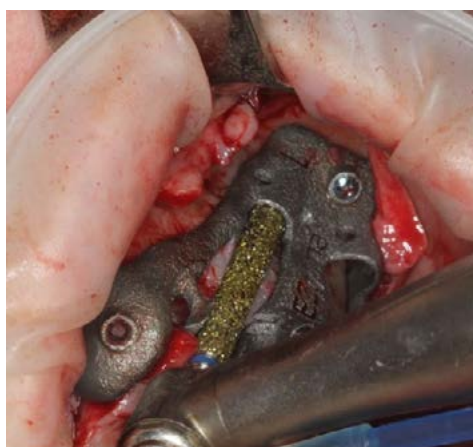

Figure 13. The outer wall of the sinus was prepared with cylindric diamond burs, in order to prepare the bone slot until it was adapted to the upper and lower support.

The cylindric diamond bur was used to create a cylindric groove in the lateral wall of the maxillary sinus to enable the drilling tools to complete the osteotomy and to provide adequate bone support to the zygomatic implant. The cylindric diamond bur's tip was placed between the bone and the upper support of the guide, that worked as a fulcrum for the medial movement of the bur against the sinus lateral wall, that was grinded until the bur was seated on the lower support. (Figure 13).

A 4.2 mm diameter drill was positioned between the guide supports and driven inwards up to a mark on the drill (Figure 14), removing the remaining bone under the upper support to allow a free setting of the following centering spoon.

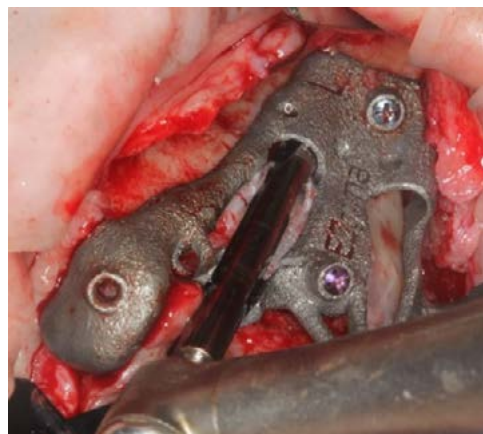

Figure 14. Centering spoon's site preparation.

The centering spoon (Figure 15) was placed in order to allow the bone site preparation with a 3 mm internal diameter. A centric drilling is always suggested in order to respect the original planning and to avoid a final implant deviation higher than usual. The drilling depth was determined once the drill was stopped by the spoon sleeve (Figure 16).

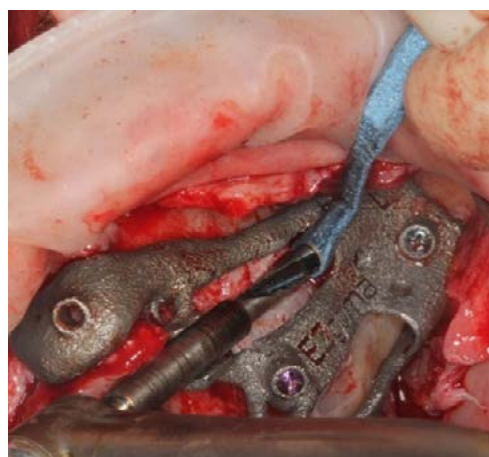


Figure 15. Main implant site preparation was carried out with a deepness bur and a reduction spoon.

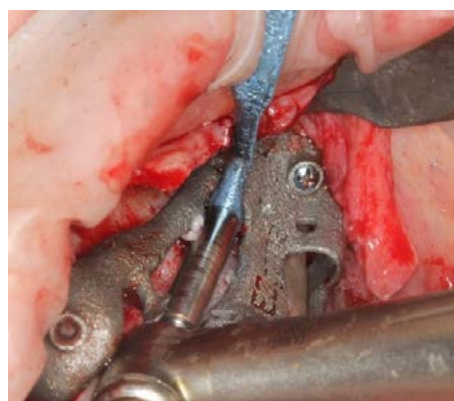

Figure 16. The deepness bur at the end of its path.

The drill No. 1 was used to finalize the bone preparation, taking care to align the bur with the upper and the lower support (Figure 17). The drilling depth was determined by aligning the planned depth mark on the drill with a reference slot on the guide (Figure 18) (The N. 2 and N. 3 final drills are used only in case of D1 bone).

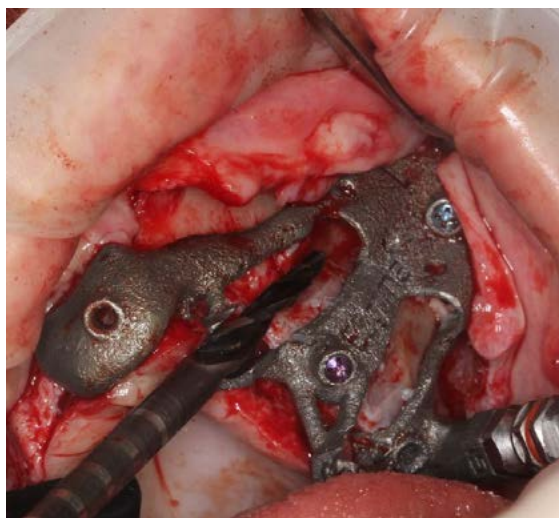


Figure 17. Last bur to finalize the implant site. Note that at this point no other tool, including reduction spoon is needed.

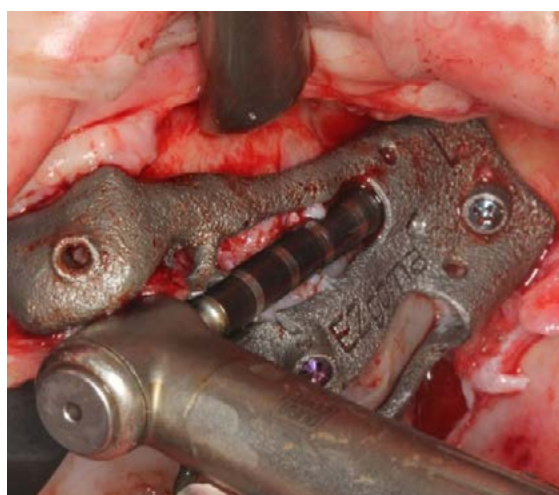

Figure 18. The final drill at the end of the preparation.

A depth probe was inserted into the osteotomy through the guide and the depth of the osteotomy was assessed aligning the planned line on the probe with the mark on the guide (Figure 19).

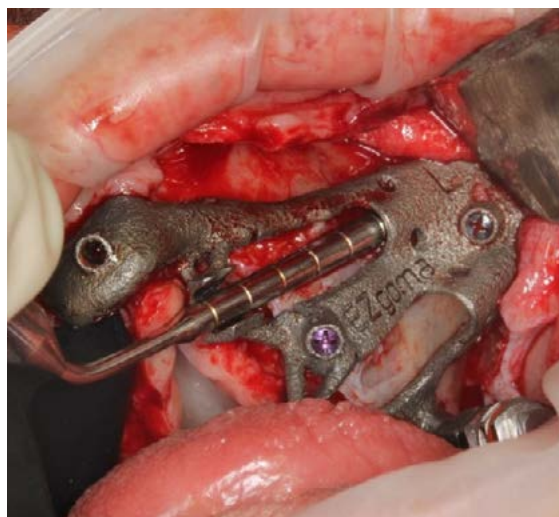


Figure 19. Depth caliper was used to assess the bone site preparation.

The planned zygomatic implant was screwed into the osteotomy site through the opposite half-sleeve of the guide (Figure 20).

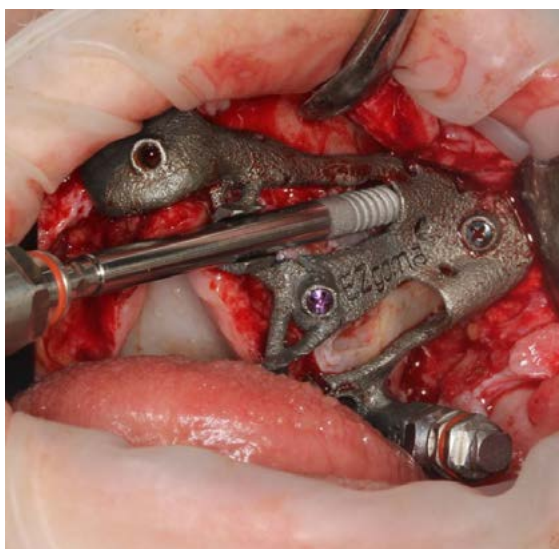


Figure 20. The zygomatic implant was screwed by a dedicated mounter to prevent implant's deviation.

An implant driver was used to perform the implant's seating until its final vertical position was aligned with the mark on the guide and the head geometry was helpful to control its final alignment. Moreover, a pin was also used to definitely orientate the prosthetic connection as planned, in order to respect the following correct placement of the selected angulated abutment (Figure 21).

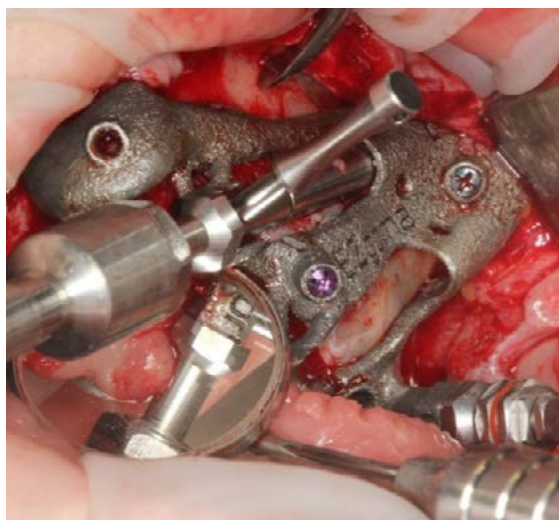

Figure 21. Implant placement was finalized with the aid of a pin to check even if the planned prosthetic connection orientation was achieved.

Finally, the surgical guide was removed simply unscrewing the two fixation screws.

The above-mentioned guided approach allowed the placement of the multi-unit-abutment on the implants before the surgical guide was removed (Figures 22 and 23).

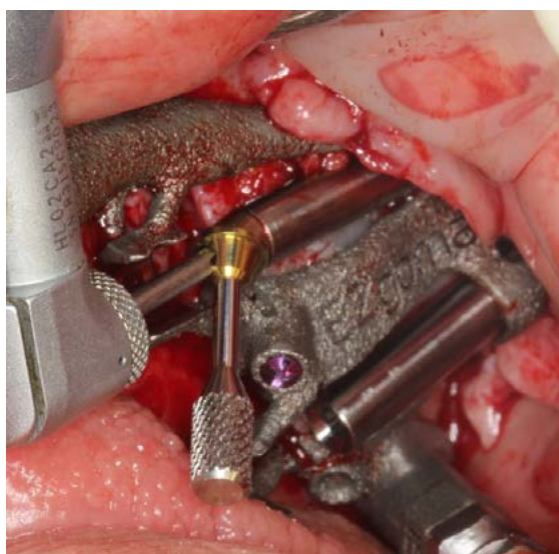


Figure 22. Multi-unit-abutment was screwed on the fixture with the surgical guide still in place.

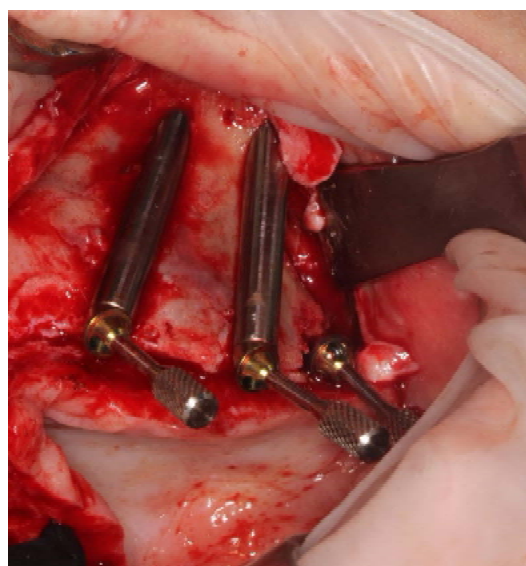


Figure 23. Implants and abutments in place confirming the surgical plan.

3. Results

A database was created using Excel (Microsoft, Redmond, WA, USA). Data were evaluated using standard statistical analysis software (version 20.0, Statistical Package for the Social Sciences, IBM Corporation, Armonk, NY, USA).

Descriptive statistics including minimum and maximum values and mean \pm SD values were calculated for each variable, and box plots were used to evaluate data outliers. The Shapiro–Wilk test was used to determine whether or not the data conformed to a normal distribution.

The independent-samples t-test was used to identify statistically significant differences in the accuracy of zygomatic implants compared to pterygoid implants and to evaluate differences in the intragroup analysis between implants positioned on the right and the left sides of the maxilla.

In each test, the cut-off for statistical significance was $p \leq 0.05$.

In total, 10 cadavers were used for the study. In each cadaver heads were inserted four zygomatic implants, two for the left and two for the right side, and two pterygoid implants, one for each side (for a total of 40 zygomatic and 20 pterygoid implants).

The mean differences in the platform plane, platform depth, apical plane, apical depth and angle position between the zygomatic and pterygoid implants compared to the virtual implant planning are reported in Table 1 and Figure 24.

Table 1. Mean difference in the platform plane, platform depth, apical plane, apical depth and angle position between zygomatic and pterygoid implants.

	Zygomatic	Pterygoid	<i>p</i> -Value
Platform plane (mm)	0.76 \pm 0.41	0.61 \pm 0.28	0.144
Platform depth(mm)	0.93 \pm 1.23	1.35 \pm 1.45	0.256
Apical plane (mm)	1.35 \pm 0.78	1.81 \pm 1.47	0.213
Apical depth (mm)	1.07 \pm 1.47	1.22 \pm 1.44	0.711
Angle position (°)	1.69 \pm 1.12	4.15 \pm 3.53	0.006

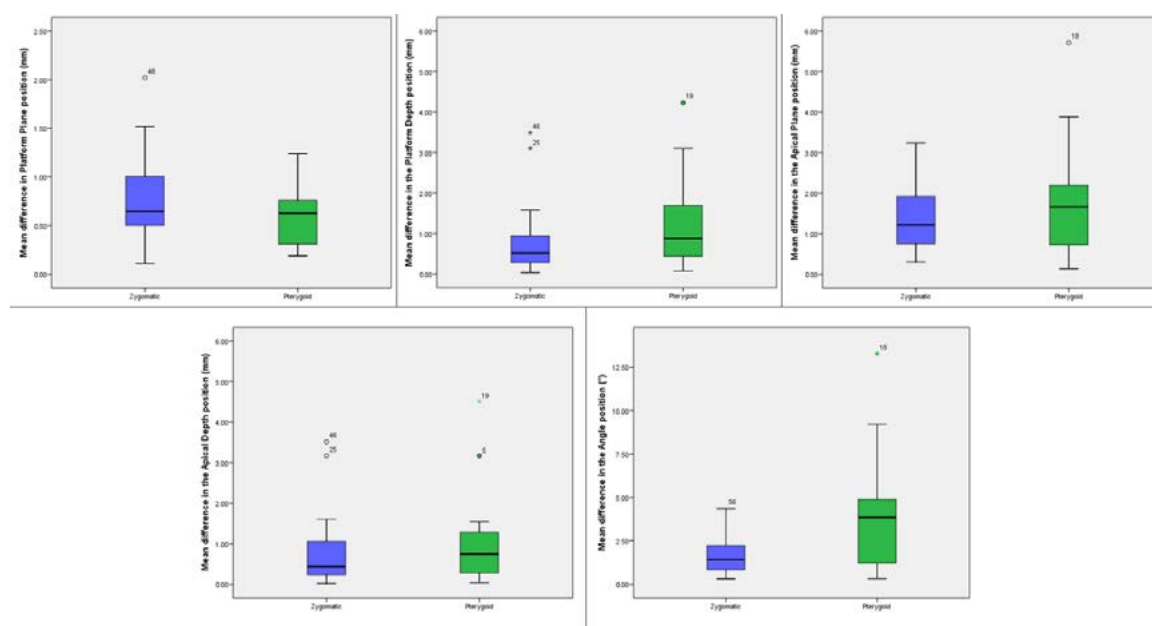


Figure 24. Box plots showing the median, quartile, minimum and maximum values of the mean differences in the platform plane (mm), platform depth (mm), apical plane (mm), apical depth (mm) and angle ($^{\circ}$) between the zygomatic and the pterygoid implants compared to the virtual planning. Boxes contain 50% of all values; the horizontal lines inside the boxes indicate the medians and the vertical lines extend to 1.5 of the interquartile range.

The independent-samples *t*-test showed no statistically significant mean difference in the platform plane, platform depth, apical plane, apical depth and a significant mean difference in the angle ($p = 0.006$) of zygomatic versus pterygoid implants (Table 1).

No difference was found in the accuracy between the left and right side in both zygomatic and pterygoid implants (Table 2).

Table 2. Mean difference in the platform plane, platform depth, apical plane, apical depth and angle position between left and right side in both zygomatic and pterygoid implants.

Zygomatic			
	Left Side	Right Side	<i>p</i> -Value
Platform plane (mm)	0.86 ± 0.44	0.67 ± 0.36	0.163
Platform depth (mm)	0.64 ± 0.43	1.17 ± 1.59	0.204
Apical plane (mm)	1.32 ± 0.84	1.38 ± 0.76	0.799
Apical depth (mm)	0.65 ± 0.45	1.41 ± 1.88	0.095
Angle position ($^{\circ}$)	1.65 ± 1.20	1.72 ± 1.09	0.864
Pterygoid			
Platform plane (mm)	0.62 ± 0.15	0.59 ± 0.37	0.801
Platform depth (mm)	1.24 ± 1.64	1.47 ± 1.30	0.741
Apical plane (mm)	1.70 ± 1.57	1.91 ± 1.43	0.762
Apical depth (mm)	1.09 ± 1.52	1.35 ± 1.43	0.703
Angle position ($^{\circ}$)	3.89 ± 3.73	4.42 ± 3.49	0.748

4. Discussion

In order to prevent possible complications of implantology, numerous authors have proposed surgical navigation systems with the support of techniques aimed at increasing precision and decreasing the risks. In this study, an innovative system used for a safe placement of zygomatic and pterygoid implants is reported. Each implant was carefully planned, starting from a virtual plan, based on a 3-D CT-scan, using a specific software. The surgeries were carried out by innovative customized 3-D printed surgical guides and a dedicated surgical kit.

The free hand extra-sinus drilling protocol for zygomatic implants requires a three-dimensional visualization of the anatomy. The first step is to define the position of the multi-unit-abutment that have to be attached to the zygomatic implant on the alveolar ridge. Tracking a line connecting the entry point of the implant at the bone crest level with the zygomatic bone, it is possible to define the path of the bone preparation. Zygomatic and pterygoid implant insertions can be affected by many risks occurring during their planning and performing. Clear setting of the entrance point, trajectory path, and exit point of the implants, combined with a successful transition from the implant planning to the surgical phase, are all crucial factors [17,18,40].

This study tested a bone-supported technique that consists of a single sintered titanium template, placed during all the surgical procedures and clinically validated by the data emerging from the overlapping of the pre-operative planning with the post-operative CT of the specimens' heads (Tables 1 and 2).

The success of a guided procedure mostly depends on the precise position of the guide on the hard or soft tissues. Particularly, in cases of severe atrophic maxilla, it might be quite difficult to maintain the stability of the surgical guide throughout the whole drilling procedure [42]. A screw-retained surgical guide, fabricated with CAD-CAM (computer-aided design and computer aided manufacturing) technology, seems to make it feasible to ensure the accuracy and the safety of the final results [36,37,39,40]. The guide thus constructed was placed on the anterolateral wall of the maxilla and fixed to the bone surface by means of 3 screws with a diameter of 1.6 mm and was removed after implants and multi-unit-abutments were correctly placed. No additional nor more aggressive procedures were needed in terms of surgical access to the maxillary sinus.

A surgical guide for the placement of zygomatic implants fabricated in the same manner as conventional dental implants is considered less reliable, as these implants are significantly longer (35–60 mm) compared to conventional dental implants. Due to this fact, a slight error in the drill path direction and in the angular deviation can significantly alter the trajectory, the positions of the apex and the divergence at the exit point. In the event of deviations in zygomatic implant placement, the consequences can be much more serious than the complications of conventional implantology [37,41,42].

The use of the bone tissue as a supporting base has been considered mandatory, as well as the use of a rigid structural material as titanium, for the guide manufacturing, as both make it feasible to transfer the plan with absolute precision to the implant site. Moreover, due to the path of these extra-sinus long fixtures, a mucosal-supported guide cannot be feasible.

The guided templates for conventional implants, even the most advanced, provide occlusal sleeves to guide burs during osteotomy. The length of the above-mentioned sleeves usually ranges from 4 to 6 mm and they are suitable for implants within 15 mm. Besides, a 35 mm to 60 mm zygomatic sleeve would be exposed to the consistent risk that the bur may get stuck and may reduce handling.

The EZgoma inverted support system overcomes these difficulties by reducing the overall dimensions of the device, as it is based on a single bone-supported template consisting of two open, opposite half-sleeves, connected by a double track, in which it is possible to house the drills with extreme precision with a standard handpiece for low speed implantology. This is unconventional if compared with free hand zygomatic

implants placement, which has usually been proposed to be performed by using a straight head handpiece.

The suggested surgical guide design made the entire guided surgery, as well as implant and abutment placement according to the planned project to support an immediate loading prosthesis, easier. In order to test implant deviations, the planned zygomatic and pterygoid implants have been saved as SLT files and compared with the ones obtained from the post-operative CT-scan. As shown in Table 1, both zygomatic and pterygoid implant deviations resulted in values comparable with those published for conventionally guided implants and no statistically significant differences have been reported [39,43,44].

This present cadaver study was performed in an anatomical laboratory environment, however in real life, clinicians perform zygomatic implant surgery on patients with extremely atrophic maxillary bone. Management of oral rehabilitation in such patients can be quite demanding, and one of the key factors is the careful follow-up period. The marginal bone resorption and changes in bone levels must be evaluated at least every two years. Especially for the specific extra-sinus placement that is typical of the presented surgical protocol, peri-implant mucosal situation must be additionally controlled. For this purpose, it is mandatory to annually remove the prostheses to check the oral hygiene status of prosthesis and the status of the abutments that are placed over the zygomatic implants. The radiographic assessment of the on-going peri-implant vertical bone loss after implant placement is considered as an essential issue for clinicians. Cosola et al., proposed a method of standardization of two-dimensional radiographs that can allow the clinicians to minimize the patient's exposure to ionizing radiations for the measurement of marginal bone levels around dental implants [45]. Such methods can be critical in order to evaluate the bone changes around the zygomatic implants at the follow-up period and have a great impact on the long-term successful results.

In the present work, as the implants have been planned both on the right and the left side of the involved heads, a comparative analysis of the side-related deviations has been carried out. No statistically significant differences have been observed in terms of accuracy between the left and right side either in zygomatic or pterygoid implants. Since all the implants have been placed by the inexperienced surgeons involved in the clinical training on cadaver heads, the accuracy results gave evidence of the safety of this guided procedure.

In cases of guided implant surgery, patients with limited arch space can be a challenging situation, especially for zygomatic implant insertions. In such cases, various protocols were introduced in literature as a solution. De Santis et al., in a clinical study evaluated a novel radiologic protocol and a new occlusal radiographic index that can give the clinician the possibility of identifying patients with limited inter-arch space. As a result, the new radiological occlusal index made with condensation silicone (Sandwich Index) proved to be effective in reproducing the maxillary forced maximum opening position during the initial planning phase. Additionally, their method prevented errors in the inclusion or exclusion of patients suitable for NobelGuide treatment [46]. The EZgoma guide system represented in this study, is a suitable method even for patients with limited mouth opening. This guide system is fixed unilaterally, which is easy to use.

The proposed EZgoma method takes several advantages of conventional sleeve guides. The two opposite supports of the guide (Figure 1), the coronal one located palatal to the alveolar ridge and the apical one placed buccally, at the entry point of the zygomatic bone and on the lateral maxillary wall of the sinus, make easier the entire surgical procedure as they leave a certain degree of freedom to the surgeon to prepare the implant site. Moreover, there is a prosthetic advantage because of the extra-sinus implant placement, as it allows a better and natural emergence profile of the future prosthesis, avoiding an uncomfortable larger palatal volume.

5. Conclusions

Zygomatic and pterygoid implants have been suggested as a solution to rehabilitate severely resorbed maxillary bone. The proposed guided zygomatic and pterygoid surgery seems to be an easier and safer method when compared with the free hand approach. Further research on the accuracy of the entire procedure is mandatory in order to avoid critical surgical complications, which can involve accidents to the surrounding anatomy. This research, which utilized a new surgical guide design, in terms of accuracy between planned and placed zygomatic and pterygoid implants, resulted in very small deviations, comparable with the ones obtained with conventional surgical guides.

Zygomatic and pterygoid implant insertions represent an effective, quicker and less invasive treatment method in indicated cases, as compared to massive bone augmentation. According to the results of this study, in terms of accuracy and with respect to the pre-surgical planning, the procedure is feasible with successful results even if performed by unexperienced surgeons. However, the simplification of the surgery and the reduction of the invasiveness should be improved.

One of the limitations of this study is the fact that it is a cadaver study.

Author Contributions: Conceptualization, F.G. (Francesco Grecchi), E.G. and L.V.S.; methodology, F.G. (Francesco Grecchi) and L.V.S.; software, R.S. and Z.M.; validation, F.G. (Francesco Grecchi), F.G. (Fabrizio Grivetto) and N.P.; formal analysis, L.V.S. and N.P.; investigation, F.G. (Francesco Grecchi) and F.G. (Fabrizio Grivetto); resources, V.D.L. and F.D.A.; data curation, N.P.; writing—original draft preparation, A.F., F.G. (Funda Goker) and E.G.; writing—review and editing, A.F., F.G. (Funda Goker) and E.G.; supervision, M.D.F. All authors have read and agreed to the published version of the manuscript.

Funding: This research received no external funding.

Institutional Review Board Statement: The study was conducted according to the guidelines of the Declaration of Helsinki, and approved by the Institutional Review Board (or Ethics Committee) of Nicola's Foundation, ICLO (Prot. Nr. 08, 5 May 2021).

Informed Consent Statement: Informed consent to use the body for study, training and scientific research, was obtained from all the alive subjects (donors) involved in the study.

Data Availability Statement: The data presented in this study are available on request from the corresponding author.

Conflicts of Interest: The authors declare no conflict of interest.

References

- Hartmann, R.; de Menezes Bandeira, A.C.F.; de Araújo, S.C.; McKenna, G.; Brägger, U.; Schimmel, M.; Leles, C.R. Cost-effectiveness of three different concepts for the rehabilitation of edentulous mandibles: Overdentures with 1 or 2 implant attachments and hybrid prosthesis on four implants. *J. Oral Rehabil.* **2020**, *47*, 1394–1402. [\[CrossRef\]](#)
- Probst, L.F.; Vanni, T.; de Cavalcante, D.F.B.; da Silva, E.T.; Cavalcanti, Y.W.; Passeri, L.A.; Pereira, A.C. Cost-effectiveness of implant-supported dental prosthesis compared to conventional dental prosthesis. *Rev. Saude Publica* **2019**, *53*, s1518–8787. [\[CrossRef\]](#)
- Nogueira, T.E.; Esfandiari, S.; Leles, C.R. Cost-effectiveness analysis of the single-implant mandibular overdenture versus conventional complete denture: Study protocol for a randomized controlled trial. *Trials* **2016**, *17*, 533. [\[CrossRef\]](#)
- Barone, A.; Toti, P.; Marconcini, S.; Derchi, G.; Saverio, M.; Covani, U. Esthetic Outcome of Implants Placed in Fresh Extraction Sockets by Clinicians with or without Experience: A Medium-Term Retrospective Evaluation. *Int. J. Oral Maxillofac. Implants* **2016**, *31*, 1397–1406. [\[CrossRef\]](#) [\[PubMed\]](#)
- Jorba-García, A.; Figueiredo, R.; González-Barnadas, A.; Camps-Font, O.; Valmaseda-Castellón, E. Accuracy and the role of experience in dynamic computer guided dental implant surgery: An in-vitro study. *Med. Oral Patol. Oral Cir. Bucal* **2019**, *24*, e76–e83. [\[CrossRef\]](#)
- Stefanelli, L.V.; DeGroot, B.S.; Lipton, D.I.; Mandelaris, G.A. Accuracy of a Dynamic Dental Implant Navigation System in a Private Practice. *Int. J. Oral Maxillofac. Implants* **2019**, *34*, 205–213. [\[CrossRef\]](#) [\[PubMed\]](#)
- Sun, T.-M.; Lee, H.-E.; Lan, T.-H. The influence of dental experience on a dental implant navigation system. *BMC Oral Health* **2019**, *19*, 222. [\[CrossRef\]](#)
- Rozov, R.A.; Trezubov, V.N.; Urakov, A.L.; Azarin, G.S.; Reshetnikov, A.P.; Kopylov, M.V. Criterion assessment system of the actual level of expertise of dental professionals practicing implant dentistry. *Stomatologiya* **2019**, *98*, 4–11. [\[CrossRef\]](#)

9. Golob Deeb, J.; Bencharit, S.; Carrico, C.K.; Lukic, M.; Hawkins, D.; Renner-Sitar, K.; Deeb, G.R. Exploring training dental implant placement using computer-guided implant navigation system for predoctoral students: A pilot study. *Eur. J. Dent. Educ.* **2019**, *23*, 415–423. [\[CrossRef\]](#) [\[PubMed\]](#)
10. Chrcanovic, B.R.; Kisch, J.; Albrektsson, T.; Wennerberg, A. Impact of Different Surgeons on Dental Implant Failure. *Int. J. Prosthodont.* **2017**, *30*, 445–454. [\[CrossRef\]](#)
11. Ravitch, M.M.; Steichen, F.M. A stapling instrument for end-to-end inverting anastomoses in the gastrointestinal tract. *Ann. Surg.* **1979**, *189*, 791–797. [\[CrossRef\]](#) [\[PubMed\]](#)
12. Watzinger, F.; Birkfellner, W.; Wanschitz, F.; Ziya, F.; Wagner, A.; Kremser, J.; Kainberger, F.; Huber, K.; Bergmann, H.; Ewers, R. Placement of endosteal implants in the zygoma after maxillectomy: A Cadaver study using surgical navigation. *Plast. Reconstr. Surg.* **2001**, *107*, 659–667. [\[CrossRef\]](#)
13. Schirotti, G.; Angiero, F.; Silvestrini-Biavati, A.; Benedicenti, S. Zygomatic implant placement with flapless computer-guided surgery: A proposed clinical protocol. *J. Oral Maxillofac. Surg.* **2011**, *69*, 2979–2989. [\[CrossRef\]](#)
14. Pellegrino, G.; Bellini, P.; Cavallini, P.F.; Ferri, A.; Zaccchino, A.; Taraschi, V.; Marchetti, C.; Consolo, U. Dynamic Navigation in Dental Implantology: The Influence of Surgical Experience on Implant Placement Accuracy and Operating Time. An In Vitro Study. *Int. J. Environ. Res. Public Health* **2020**, *17*, 2153. [\[CrossRef\]](#)
15. Mediavilla Guzmán, A.; Riad Deglow, E.; Zubizarreta-Macho, Á.; Agustín-Panadero, R.; Hernández Montero, S. Accuracy of Computer-Aided Dynamic Navigation Compared to Computer-Aided Static Navigation for Dental Implant Placement: An In Vitro Study. *J. Clin. Med.* **2019**, *8*, 2123. [\[CrossRef\]](#) [\[PubMed\]](#)
16. Stefanelli, L.V.; Graziani, U.; Pranno, N.; Di Carlo, S.; Mandelaris, G.A. Accuracy of Dynamic Navigation Surgery in the Placement of Pterygoid Implants. *Int. J. Periodontics Restor. Dent.* **2020**, *40*, 825–834. [\[CrossRef\]](#)
17. Qin, C.; Cao, Z.; Fan, S.; Wu, Y.; Sun, Y.; Politis, C.; Wang, C.; Chen, X. An oral and maxillofacial navigation system for implant placement with automatic identification of fiducial points. *Int. J. Comput. Assist. Radiol. Surg.* **2019**, *14*, 281–289. [\[CrossRef\]](#)
18. Qin, C.; Ran, X.; Wu, Y.; Chen, X. The development of non-contact user interface of a surgical navigation system based on multi-LSTM and a phantom experiment for zygomatic implant placement. *Int. J. Comput. Assist. Radiol. Surg.* **2019**, *14*, 2147–2154. [\[CrossRef\]](#)
19. Stefanelli, L.V.; Mandelaris, G.A.; DeGroot, B.S.; Gambarini, G.; De Angelis, F.; Di Carlo, S. Accuracy of a Novel Trace-Registration Method for Dynamic Navigation Surgery. *Int. J. Periodontics Restor. Dent.* **2020**, *40*, 427–435. [\[CrossRef\]](#) [\[PubMed\]](#)
20. Kaewsiri, D.; Panmekiate, S.; Subbalekha, K.; Mattheos, N.; Pimkhaokham, A. The accuracy of static vs. dynamic computer-assisted implant surgery in single tooth space: A randomized controlled trial. *Clin. Oral Implant Res.* **2019**, *30*, 505–514. [\[CrossRef\]](#)
21. Widmann, G.; Bale, R.J. Accuracy in computer-aided implant surgery—A review. *Int. J. Oral Maxillofac. Implants* **2006**, *21*, 305–313.
22. Lal, K.; White, G.S.; Morea, D.N.; Wright, R.F. Use of stereolithographic templates for surgical and prosthodontic implant planning and placement. Part II. A clinical report. *J. Prosthodont* **2006**, *15*, 117–122. [\[CrossRef\]](#)
23. Vercruyssen, M.; Fortin, T.; Widmann, G.; Jacobs, R.; Quirynen, M. Different techniques of static/dynamic guided implant surgery: Modalities and indications. *Periodontology 2000* **2014**, *66*, 214–227. [\[CrossRef\]](#) [\[PubMed\]](#)
24. D'haese, J.; Ackhurst, J.; Wismeijer, D.; De Bruyn, H.; Tahmaseb, A. Current state of the art of computer-guided implant surgery. *Periodontology 2000* **2017**, *73*, 121–133. [\[CrossRef\]](#) [\[PubMed\]](#)
25. Somogyi-Ganss, E.; Holmes, H.I.; Jokstad, A. Accuracy of a novel prototype dynamic computer-assisted surgery system. *Clin. Oral Implants Res.* **2015**, *26*, 882–890. [\[CrossRef\]](#)
26. Miller, R.J.; Bier, J. Surgical navigation in oral implantology. *Implant. Dent.* **2006**, *15*, 41–47. [\[CrossRef\]](#)
27. Block, M.S.; Emery, R.W. Static or Dynamic Navigation for Implant Placement—Choosing the Method of Guidance. *J. Oral Maxillofac. Surg.* **2016**, *74*, 269–277. [\[CrossRef\]](#) [\[PubMed\]](#)
28. Bornstein, M.M.; Scarfe, W.C.; Vaughn, V.M.; Jacobs, R. Cone beam computed tomography in implant dentistry: A systematic review focusing on guidelines, indications, and radiation dose risks. *Int. J. Oral Maxillofac. Implants* **2014**, *29*, 55–77. [\[CrossRef\]](#)
29. Jung, R.E.; Schneider, D.; Ganeles, J.; Wismeijer, D.; Zwahlen, M.; Hammerle, C.H.F.; Tahmaseb, A. Computer technology applications in surgical implant dentistry: A systematic review. *Int. J. Oral Maxillofac. Implants* **2009**, *24*, 92–109.
30. Gaggli, A.; Schultes, G.; Kärcher, H. Navigational precision of drilling tools preventing damage to the mandibular canal. *J. Cranio Maxillofac. Surg.* **2001**, *29*, 271–275. [\[CrossRef\]](#) [\[PubMed\]](#)
31. Colombo, M.; Mangano, C.; Mijiritsky, E.; Krebs, M.; Hauschild, U.; Fortin, T. Clinical applications and effectiveness of guided implant surgery: A critical review based on randomized controlled trials. *BMC Oral Health* **2017**, *17*, 150. [\[CrossRef\]](#)
32. Bover-Ramos, F.; Viña-Almunia, J.; Cervera-Ballester, J.; Peñarocha-Diogo, M.; García-Mira, B. Accuracy of Implant Placement with Computer-Guided Surgery: A Systematic Review and Meta-Analysis Comparing Cadaver, Clinical, and In Vitro Studies. *Int. J. Oral Maxillofac. Implants* **2018**, *33*, 101–115. [\[CrossRef\]](#)
33. Block, M.S.; Emery, R.W.; Cullum, D.R.; Sheikh, A. Implant Placement Is More Accurate Using Dynamic Navigation. *J. Oral Maxillofac. Surg.* **2017**, *75*, 1377–1386. [\[CrossRef\]](#) [\[PubMed\]](#)
34. Cassetta, M.; Bellardini, M. How much does experience in guided implant surgery play a role in accuracy? A randomized controlled pilot study. *Int. J. Oral Maxillofac. Surg.* **2017**, *46*, 922–930. [\[CrossRef\]](#)
35. Park, S.-J.; Leesungbok, R.; Cui, T.; Lee, S.W.; Ahn, S.-J. Reliability of a CAD/CAM Surgical Guide for Implant Placement: An In Vitro Comparison of Surgeons' Experience Levels and Implant Sites. *Int. J. Prosthodont* **2017**, *30*, 367–369. [\[CrossRef\]](#)

36. Scherer, U.; Stoetzer, M.; Ruecker, M.; Gellrich, N.-C.; von See, C. Template-guided vs. non-guided drilling in site preparation of dental implants. *Clin. Oral Investig.* **2015**, *19*, 1339–1346. [[CrossRef](#)] [[PubMed](#)]
37. Wang, C.I.; Cho, S.-H.; Ivey, A.; Reddy, L.V.; Sinada, N. Combined bone- and mucosa-supported 3D-printed guide for sinus slot preparation and prosthetically driven zygomatic implant placement. *J. Prosthet. Dent.* **2021**. [[CrossRef](#)]
38. Stella, J.P.; Warner, M.R. Sinus slot technique for simplification and improved orientation of zygomaticus dental implants: A technical note. *Int. J. Oral Maxillofac. Implants* **2000**, *15*, 889–893.
39. Van Steenberghe, D.; Malevez, C.; Van Cleynenbreugel, J.; Bou Serhal, C.; Dhoore, E.; Schutyser, F.; Suetens, P.; Jacobs, R. Accuracy of drilling guides for transfer from three-dimensional CT-based planning to placement of zygoma implants in human cadavers. *Clin. Oral Implants Res.* **2003**, *14*, 131–136. [[CrossRef](#)]
40. Chrcanovic, B.R.; Oliveira, D.R.; Custódio, A.L. Accuracy evaluation of computed tomography-derived stereolithographic surgical guides in zygomatic implant placement in human cadavers. *J. Oral Implantol.* **2010**, *36*, 345–355. [[CrossRef](#)] [[PubMed](#)]
41. Cao, Z.; Qin, C.; Fan, S.; Yu, D.; Wu, Y.; Qin, J.; Chen, X. Pilot study of a surgical robot system for zygomatic implant placement. *Med. Eng. Phys.* **2020**, *75*, 72–78. [[CrossRef](#)]
42. Schneider, D.; Marquardt, P.; Zwahlen, M.; Jung, R.E. A systematic review on the accuracy and the clinical outcome of computer-guided template-based implant dentistry. *Clin. Oral Implants Res.* **2009**, *20* (Suppl. 4), 73–86. [[CrossRef](#)]
43. Hung, K.-F.; Wang, F.; Wang, H.-W.; Zhou, W.-J.; Huang, W.; Wu, Y.-Q. Accuracy of a real-time surgical navigation system for the placement of quad zygomatic implants in the severe atrophic maxilla: A pilot clinical study. *Clin. Implant. Dent. Relat. Res.* **2017**, *19*, 458–465. [[CrossRef](#)]
44. Tahmaseb, A.; Wismeijer, D.; Coucke, W.; Derksen, W. Computer technology applications in surgical implant dentistry: A systematic review. *Int. J. Oral Maxillofac. Implants* **2014**, *29*, 25–42. [[CrossRef](#)] [[PubMed](#)]
45. Cosola, S.; Toti, P.; Peñarrocha-Diogo, M.; Covani, U.; Brevi, B.C.; Peñarrocha-Oltra, D. Standardization of three-dimensional pose of cylindrical implants from intraoral radiographs: A preliminary study. *BMC Oral Health* **2021**, *21*, 100. [[CrossRef](#)] [[PubMed](#)]
46. De Santis, D.; Graziani, P.; Castellani, R.; Zanolli, G.; Gelpi, F.; Marconcini, S.; Bertossi, D.; Nocini, P.F. A New Radiologic Protocol and a New Occlusal Radiographic Index for Computer-Guided Implant Surgery. *J. Craniofac. Surg.* **2016**, *27*, e506–e510. [[CrossRef](#)] [[PubMed](#)]



Article

Three-Dimensional Technology Applications in Maxillofacial Reconstructive Surgery: Current Surgical Implications

Yasmin Ghantous ^{1,†}, Aysar Nashef ^{1,*,†}, Aladdin Mohanna ¹ and Imad Abu-El-naaj ^{1,2}

¹ Department of Oral and Maxillofacial Surgery, Baruch Padeh Medical Center Poriya, Tiberias 158001, Israel; yasmen.ghantous@gmail.com (Y.G.); ma.aladdin@gmail.com (A.M.); iabu@poria.health.gov.il (I.A.-E.-n.)

² The Azrieli Faculty of Medicine, Bar Illan University, 8 Henrietta Szold St, Safed 1310000, Israel

* Correspondence: dr.aysarn@gmail.com

† Equal contribution.

Received: 16 November 2020; Accepted: 14 December 2020; Published: 16 December 2020



Abstract: Defects in the oral and maxillofacial (OMF) complex may lead to functional and esthetic impairment, aspiration, speech difficulty, and reduced quality of life. Reconstruction of such defects is considered one of the most challenging procedures in head and neck surgery. Transfer of different auto-grafts is still considered as the “gold standard” of regenerative and reconstructive procedures for OMF defects. However, harvesting of these grafts can lead to many complications including donor-site morbidity, extending of surgical time, incomplete healing of the donor site and others. Three-dimensional (3D) printing technology is an innovative technique that allows the fabrication of personalized implants and scaffolds that fit the precise anatomy of an individual’s defect and, therefore, has attracted significant attention during the last few decades, especially among head and neck surgeons. Here we discuss the most relevant applications of the 3D printing technology in the oral and maxillofacial surgery field. We further show different clinical examples of patients who were treated at our institute using the 3D technology and discuss the indications, different technologies, complications, and their clinical outcomes. We demonstrate that 3D technology may provide a powerful tool used for reconstruction of various OMF defects, enabling optimal clinical results in the suitable cases.

Keywords: three dimensional printing; 3D printing; oral and maxillofacial reconstruction; 3D printing in the cranio-maxillofacial surgery

1. Introduction

The repair of large oral and maxillofacial (OMF) defects, secondary to tumor, trauma, or congenital disease, employs a multidisciplinary approach and represents one of the most difficult and challenging areas in head and neck surgery. The goals of craniofacial reconstruction include, mainly, the restoration of complex functional, anatomic, and aesthetic characteristics, with important respect to the craniofacial growth in the growing patients. To this end, autologous bone grafts remain the gold standard in hard-tissue reconstructive surgery owing to their osteoinductive and osteoconductive properties, osteogenic properties and the potential for continuous growth of particular autologous grafts at the defect sites (i.e., costochondral graft) [1,2]. Moreover, in defects with extensive hard and soft tissue loss in the OMF complex, loco-regional flaps and microvascular free tissue transfer is still considered as the superior reconstructive option [3,4]. However, despite high success rates of both vascularized and non-vascularized grafts, such reconstructive options still have critical disadvantages including, mainly, donor-site morbidity, availability in limited quantities, prolonged anesthesia time, unpredictability of

bone graft resorption, total flap loss, and the need to manually sculpt the graft into the shape of the defect site [4–6].

The use of biomaterials for bone regeneration in large OMF defects is promising, however, those materials must meet specific characteristics in order to regenerate new and functional bone; for example, biocompatibility, porosity, morphology and inter-connectivity, osteoconductivity/osteinductivity, biodegradability and several specific mechanical characteristic that enable suitable handling and growing. Unfortunately, there are few biomaterials that fit those requirements, especially for large defects.

Three-dimensional (3D) printing is a novel technique that has evolved over the past three decades and has the potential to revolutionize the field of reconstructive medicine in general [7,8]. Since its first description by Hideo Kodama in 1981 [9], 3D technology has matured and many more sophisticated different printers than the original machines currently exist, allowing for application in a range of fields including aerospace, engineering, consumer products, arts, food industry, education, manufacturing, and medicine [8,10]. Three-dimensional printing is also defined as additive manufacturing (AM), and this technique uses metals, ceramics, and plastic material to produce three-dimensional (3D) objects for the usage in different disciplines, including medical application [11]. The AM process is defined by the International Organization for Standardization (ISO) and American Society for Testing and Materials (ASTM) as the “process of joining materials to make parts from 3D model data, usually layer upon layer, as opposed to subtractive and formative manufacturing methodologies”. [12]. The processes encompassed in AM are the 3D analog of the very common 2D digital printers; therefore, AM is also commonly referred to as 3D printing. AM has gained to many definitions over the last 30 years, such as direct digital manufacturing, additive layer manufacturing, additive fabrication, additive processes, free-formed fabrication, solid free-formed fabrication, rapid manufacturing, and rapid prototyping [13]. It is noteworthy that, in contrast to the conventional manufacturing processes (i.e., subtractive and formative manufacturing processes), AM technology has the ability to deal and create complex geometric products [14], with a high degree of functionality [13] and low cost of manufacturing [15]. Thus, AM is considered as the ideal technology for producing unique 3D objects that are manufactured in low volumes that are generally used for medical and dental applications [16–18].

In this review, we discuss the three principal applications of AM process that are relevant to oral and maxillofacial surgery including: (i) the use of 3D printing to generate 3D models for surgical planning and education; (ii) the use of 3D printing technology for the production of patient-specific implants (PSI); and (iii) the bio printing of organic structures. We provide different clinical cases where AM process is applied for treatment planning, surgical stimulation, intraoperative guidance and printing of PSIs for reconstruction of OMF defects. We also provide an overview of the printing technologies that are most commonly used for oral and maxillofacial surgery applications.

2. Three-Dimensional (3D) Printing Techniques

In the medical field, and particularly, in the oral and the maxillofacial reconstructive surgery, there are several variants of AM processes and printers available today [8,10,12,19]. However, all AM process share the same concept of work-flow which can be summarized as follows [11,15]: the process begins with capturing anatomical scans using imaging techniques such as magnetic resonance imaging (MRI) and computed tomography (CT) scans; then, a computer aided design (CAD) model is processed and optimized using specific computer techniques. Then, the CAD model is transformed into a standard triangulation or tessellation language (STL) file and imported into an AM setup. Each AM model, is formatted in the STL to a geometric shape, and sliced into thin layers and the movement of the depositing or fusing unit (“printing head”), and substrate (“printing platform”), as well as other parameters are programmed by specialized software. Consequently, the AM machine constructs the 3D model layer-by-layer according to a specific and precise programmed parameters., the built object is removed from the building platform and followed by post-processing procedures (such as polishing, coating, or thermal treatment) to obtain a functional part.

2.1. Stereolithography

In stereolithography (SLA), the 3D model is fabricated in a series of layers that correspond to the axial image slices of the CT scan. The technology is classified as a vat photopolymerisation AM process in which an ultraviolet (UV) light is projected on a bath of curable photopolymeriser resin. After the first layer is built, it either moves, gradually, out of the bath or descends depending on the production configuration, and the focused energy beam renders the next layer, according. Typically, each layer is polymerized at a thickness of 0.05–0.15 mm. This process is continued until each corresponding slice of the CT image is duplicated in the resin model. In medical field, and in particular in OMF surgery, the generated SLA models are, mostly, prepared by acrylate or epoxy resin, and used for surgical guides and templates, as well as for training residents, designing soft tissue incisions, surgical resection margins, assessing of bony defects for grafting, adaptation and pre-bending of reconstruction plates, and fabrication of custom prostheses. The accuracy of these printed objects in resembling the human anatomy as well as its utility in the perioperative management for improving the predictability of treatment of maxillofacial defects secondary to traumatic or pathologic conditions have been confirmed in numerous reports [20–27].

2.2. Laser Sintering

Laser sintering (LS) and related techniques (i.e., selective laser sintering, direct metal laser sintering, laser melting and others) are classified as a powder bed fusion process of AM that is currently employed, widely, in medical disciplines. The process is based on the same principle of layer-by-layer AM. The system normally consists of a laser, an automatic powder layering apparatus, a computer system for process control and some accessorial mechanisms such as gas protection systems and powder bed preheating systems. The function of a LS system employs a focusing of a high-powered energy laser into a powdered substrate, causing a fusion of the substrate into the desired shape. Once a layer of substrate has been sintered, a new layer of substrate is added on the top of the developing construct, and energy is applied again [28]. Different types of laser are used for this purpose (including CO₂, Nd:YAG, fiber lasers, disc lasers and others) and selected based on to the laser absorptivity of the specific material used and the operative metallurgical mechanism of the powder densification [29,30]. The process is include firstly a leveling and fixation of the substrate on the building platform, followed by deposition of a thin layer of loose powder (normally ~100 µm) on the substrate. Subsequently, a laser beam scans the powder bed surface to form a layer according to the CAD data. The procedure is repeated, in a layer-by-layer manner, until a complete highly accurate and nearly a full density functional part is produced [28]. This technology has traditionally been used in non-biological printing, but also for biological substrates [8]. Indeed, the LS technologies have changed the workflow for various surgical procedures among many disciplines within the OMF surgery field during the last years. The availability of this process provided us with the ability to fabricate a wide range of objects including surgical osteotomy guides with high accuracy, custom-made titanium orbital floors, custom made grids, sub-periosteal dental implants, custom-made cranial plates and other parts that perfectly adapt to the specific anatomical requirements of patients [31–39].

2.3. Extrusion Printing

Extrusion printing is another widely available process for 3D printing of biological and non-biological materials and considered among the most widely used AM processes, especially when dealing with polymers and thermoplastic composites. This process includes, mainly, the fused deposition modeling (FDM) technique and the fused filament fabrication (FFF). The basic principle of material extrusion additive technology involves the loading and liquefaction of a printed material. The material moves through a nozzle or orifice by applying a pneumatic pressure, followed by plotting of the liquefied material according to a pre-defined path in a controlled manner, and layer-by-layer bonding of the material to itself or a secondary build material to form a coherent solid structure.

Once a layer is formed, the build platform moves down or the extrusion head moves up, and a new layer of material is deposited and adhered onto the previous layer. In contrast to other AM techniques, the extrusion printing process allow for multi-material deposition due to the possibility of adding one or more extrusion unit simultaneously and can be used for various thermoplastics for the same product [40,41]. Depending on the type of extruder used, one can classify material extrusion additive manufacturing into main three different types; plunger-based, filament-based, and screw-based [42]. Indeed, material extrusion of filaments was first patented by the company Stratasys and commercialized as fused deposition modeling (FDM) [43]. This process of AM is popular in the medical field due to its safe and simple fabrication process because of no powders, lasers, solvents, nor volatile compounds are used, the low cost of the equipment, and the availability of a great variety of filaments for printing. During the last few years, the use of FDM technology for OMF reconstructive surgery was restricted mainly to manufacturing surgical guides for preoperative planning of complex surgical treatments. However, recently the technology was successfully used to print alloplastic materials, named polyetheretherketone (PEEK), which has emerged as an attractive option for producing PSI owing to its excellent combination of high-temperature performance, chemical resistance, fatigue resistance, lightweight, high yield strength, stiffness, and durability [44,45].

3. Three-Dimensional Printing Materials

The fabrication process of each 3D printing includes external heat, light, laser and other energy sources. The mechanical characteristics of the different materials and the variable chemistry enable it to react optimistically to the different external source of energy and to transform to the desired shape. Nowadays, the advanced 3D printing technologies enable shape transforming of the materials, layer by layer, in response to the external energy source. There are several material states available, such as powder, pellets, resin, and granules, while the specific material type and characteristics are developed in accordance with the expanded development of 3D manufacturing.

The most popular AM materials are plastic nylon, and polyamide, since both are strong and flexible, and basically white in color. They can be used in two forms, powder and filament. Powder is used mainly in the sintering process, and filament is mainly used in FDM [46]. If a different range of color is desired, Acrylonitrile butadiene styrene (ABS) could present a suitable choice, ABS is a strong, filament plastic material and it is available in a wide range of colors. Polylactic acid (PLA) is also a plastic material available both in filament and resin forms, in addition it is available in several colors, this material can be used for the FDM process, where in resin form it can be used for digital light processing, the main drawback of this material being its rigidity, and non-malleability. Alumide, is a powder format plastic material that is used for sintering, this material is formed by combining Polyamide in its powder format with powdered aluminum. Ceramics are relatively a new group of 3D materials that have proved to be suitable for several medical applications, however, the printed ceramic objects should undergo post-processing firing and glazing to achieve a smooth surface area [46,47]. Another popular group of materials are metals, while the most common metal composites used are aluminum, titanium, and cobalt derivatives. Stainless steel is one the metal materials most often used in 3D printing due to its strength, it is naturally silver, but it can be blended with other materials to gain a variety of other properties. Research is being undertaken to evaluate the use of bio materials for 3D printing for medical applications.

Simple direct media layer (SDL) process-based printers provide a professional 3D printing technique, and this technique enables the use paper-based 3D printers; such materials have many advantages, they are safe, easily recycled and require no post processing [47].

4. Clinical Examples of Additive Manufacturing (AM) Use in Oral and Maxillofacial Surgery

The following section of the paper is focusing on clinical case reports that were treated at our department with emphasis on the indications for use, material of choice, intra-operative and post-operative complications. The demographic characteristics, treatment indications, and clinical

outcome of patients who were treated with the 3D application at our institute between 2015–2020 were reviewed, retrospectively. The institutional review board of Peda-Poria hospital approved the study protocol. Briefly, computed tomography (CT) scans were obtained for these patients. Images from these modalities were saved in a digital imaging and communications in medicine (DICOM) format. Subsequently, CAD software were used to create a virtual 3D prototype, based on the surgery plan. Standard tessellation Language (STL) format was then generated to allow 3D printing and deposition of the material layer by layer to achieve the final 3D object. Depending on the application, an appropriate printing technique and printer was selected (i.e., SLA, SLS etc...). Finally, final post printing modification of the printed part was performed [8,10,12,19].

A total of 16 patients were treated at our department between 2015 and 2020, using the AM process, and are summarized in Table 1. The mean age of patients was 45.5 years (range 19–80 years). The male to female ratio was 8:8. The technology was mostly applied for the trauma and post-trauma surgery discipline (7/16; 44% of cases), followed by pre-prosthetics surgery discipline (5 out of 16, 31%), oncologic surgery discipline (2 out of 16; ~13%), one case of temporomandibular joint (TMJ) surgery and one case for facial deformity correction surgery. PSI was the most printed object (10 out of 16) in our case series and were used mainly for floor of orbit reconstruction (4 out of 10 cases; 40%). Titanium material was the most used material in 3D printing with 69% of cases (11 out of 16 cases). PEEK material was used in three cases for PSI printing as a reconstruction approach of the floor of the orbit, nasal bone and temporal and frontal bone reconstruction. Intraoperative complications were noted among three cases (19%- two PSI and one surgical cutting guide) and were to include mainly loss of accurate fitting of the printed object; in these cases, minimal adjustment of the printed part was performed intra-operatively allowing for acceptable fitting. With regard to post-operative complications, one case has showed extensive post-operative edema followed by exposure of PSI and development of acute infection, this patient was retreated successfully with a free flap fibula reconstruction. In one patient, who was treated for nasal bone reconstruction, this showed an insufficient esthetic of nasal contour. As expected, almost all of the cases with PSI showed some degree of postoperative edema.

Table 1. List of the 16 cases that were treated at our department between 2015–2020 using the 3D technology including demographic data, surgical discipline, site of surgery, the printed objects, material of choice, intra-operative and post-operative complications. IO: intra-operative, PO: post-operative, TMJ: temporomandibular joint. PEEK: polyetheretherketone, PSI: patient-specific implant, SLA: stereolithographic.

Case Nu.	Age	Sex	Surgical Disciplines	Site		
1	33	F	Trauma	Mandible		
2	80	M	Oncology	Mandible		
3	40	M	Trauma	Orbit		
4	64	M	Oncology	Mandible		
5	21	M	Trauma	Nose		
6	50	M	TMJ Ankylosis	TMJ		
7	49	M	Trauma	Orbit		
8	20	F	Trauma	Orbital cavity, frontal bone and temporal bone		
9	19	M	Trauma	Orbit		
10	44	F	Trauma	Orbit		
11	22	F	Facial deformity	Mandible		
12	44	F	Pre-prosthetics	Mandible		
13	50	F	Pre-prosthetics	Maxilla	Surgical guide stent	Ti
14	71	M	Pre-prosthetics	Maxilla	Surgical guide stent	Ti
15	66	F	Pre-prosthetics	Maxilla	Surgical guide stent	Ti
16	56	F	Pre-prosthetics	Maxilla	Surgical guide stent	Ti

Printed Object	Material	IO. Complication	PO. Complication
SLA model for pre-bending of reconstruction plate	Resin	–	Mild edema
PSI for of mandibular body reconstruction including dental implants	Titanium	–	Severe edema, exposure of implant and infection
PSI for floor of orbit reconstruction	Titanium	–	Mild edema
PSI of mandibular body with ramus and condyle	Titanium	–	Moderate edema
PSI for nasal bone reconstruction	PEEK	–	Edema and improper contour
PSI for ramus and condyle reconstruction	Titanium	–	Mild edema
PSI for floor of orbit reconstruction	Titanium	–	Mild peri-orbital edema
PSI for temporal and frontal bone reconstruction	PEEK	Loss of accurate fitting	Moderate peri-orbital edema
PSI for floor of orbit reconstruction	PEEK	–	Mild edema
PSI for floor of orbit reconstruction	Titanium	Loss of accurate fitting	Mild edema
Surgical cutting guide of mandibular lower border	Resin	Loss of accurate fitting	
PSI of sub-periosteal dental implant	Titanium	–	Mild edema
Surgical guide stent	Titanium	–	
Surgical guide stent	Titanium	–	
Surgical guide stent	Titanium	–	
Surgical guide stent	Titanium	–	

5. AM Process in Virtual Surgical Treatment Planning, Surgical Stimulation and Education

SLA is a valuable adjunct to traditional methods of treatment planning and surgical stimulation for reconstruction following resection of tumors, developmental abnormalities, or trauma reconstruction. In practice, SLA aids in patient education, clarification of diagnoses, and improving treatment planning. These models allow case-specific surgical simulation and are used as a template for modification of bone plates or the fabrication of implants, which may improve the workup and operative phases and can enhance the surgical treatment [20]. Here, we present a 33-year-old woman who was referred to our institution for evaluation and treatment plan 8 years after a gunshot wound injury (GSW) to her right mandible (Figure 1). She was treated by other surgeons with bone plates 8 years ago, but infection developed at the surgery site and a fistula was noted. Her first management included the removal of the infected plate and a wound closure. In addition, because of a large defect in her mandible body, the patient elected to undergo reconstruction using bone plates with subsequent bone graft. A SLA model was constructed to pre-bend the bone plates in order to re-create this patient's pre-injury bony contour and allow for adequate mandible strength. Prior to surgery, a mandibular reconstruction plate was prebent using the printed SLA model as a reference and screw placement was also planned, as well as screw lengths, which were recorded by measuring the thickness of the model at each plate hole. The final post-operative result showed adequate reconstruction of facial contours and adequate facial symmetry.

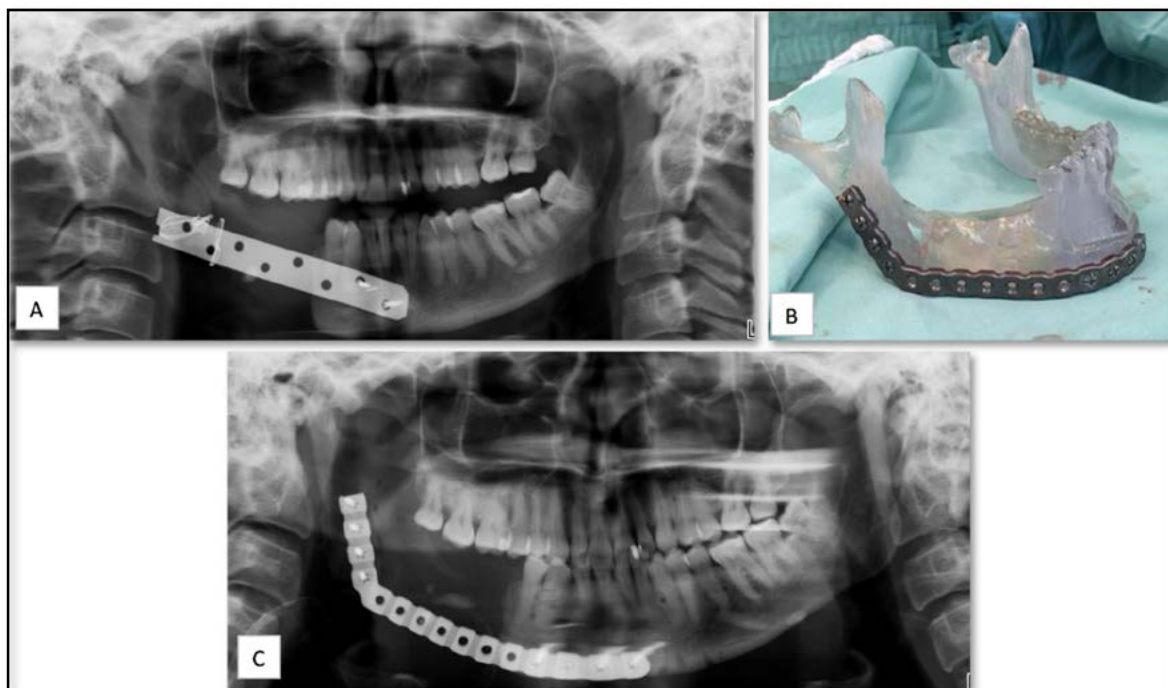


Figure 1. (A) Panoramic radiograph showing right mandibular defect with the old bone plate. (B) Stereolithographic (SLA) model and the prebent reconstruction plate. (C) Post-operative panoramic radiograph showing the installed reconstruction plate.

5.1. AM for Manufacturing of Surgical Guides for Zygomatic Implants Insertion

One of the most printed 3D objects in the OMF surgery are surgical guides that are designed to facilitate the orientation and execution of drillings, permitting a correct dental implant placement and angulation, as predicted in preoperative planning [48–50]. Here, we show a 56-year-old female patient who was referred to our clinic because of severely atrophic posterior mandible and maxilla (Figure 2). The treatment plan included placing two conventional, four zygomatic and two pterygoid implants with immediate loading principle. Mandibular prosthesis was planned with five implant

supported fixed partial denture. Indeed, zygomatic and pterygoid implant implants have become a predictable treatment modality for the rehabilitation of the severely atrophic maxilla [49]. However, due to different anatomic variations, proximity to vital anatomic structures and limited intraoperative visibility, the placement of such implants can be a challenging procedure and may ultimately lead to postoperative surgical and prosthetic complications [51]. A prosthetically driven preoperative planning was performed and a 3D metal drill guide was fabricated and used to allow full control of the accurate location and angulation of the implants.

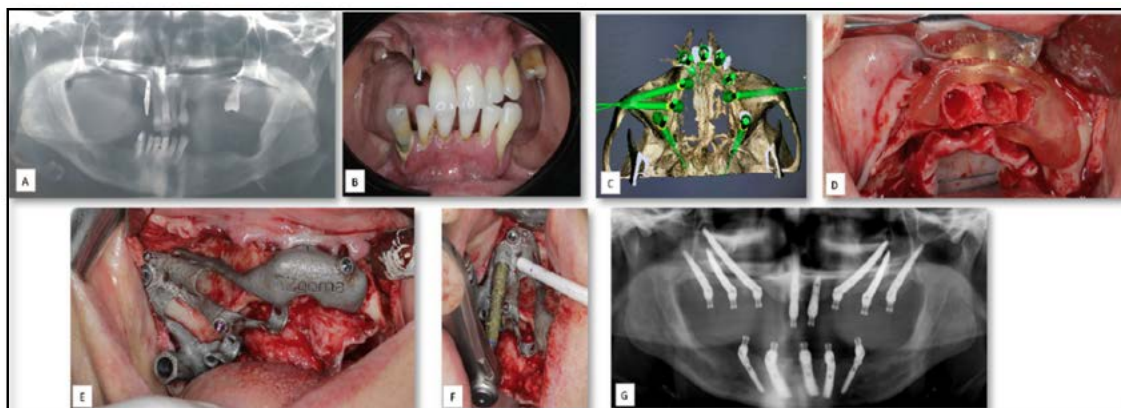


Figure 2. (A,B) Pre-operative panoramic and clinical view of partially edentulous atrophic posterior maxilla and maxilla. (C) Implants planned based on the prosthetic needs. (D) Cutting guide for alveoplasty before implants placement. (E) The installation of the created surgical guide. (F) Implant osteotomy guided by the surgical guide. (G) Post-operative panoramic view showed the implants opposition as planned preoperatively.

5.2. AM for of Pre-Prosthetics Patient-Specific Implant (PSI) Manufacturing

Endosseous dental implants provide a highly predictable solution for the prosthetic rehabilitation of partially and totally edentulous patients, with high rates of survival and success in the medium and long terms. Insertion of such implants requires the existence of adequate quantity (volume) and quality (density) of bone at the surgical site [50]. Several surgical technique have been proposed to restore bone volume to a level that allows the proper implant placement in cases of patients with severe bone atrophy, including inlay/inlay bone grating [52,53], guided bone regeneration (GBR) with resorbable or non-resorbable membranes [54,55], alveolar ridge split, distraction osteogenesis [56,57], and maxillary sinus augmentation. However, theses surgical techniques are complex and can have a rather high percentage of complications. The new direct metal laser sintering techniques available today provide the ability to fabricate custom-made implants [56]. Briefly, a subperiosteal implant is a type of dental implant that is placed between the periosteum and the residual alveolar bone [58]. It usually has two to four trans-mucosal elements projecting through the mucosa into the oral cavity, connecting the implant to the prosthesis. Here, we show an example of a patient with left posterior severe atrophic mandible referred to our clinic for evaluation and a treatment plan for a pre-prosthetics solution (Figure 3). Accurate impressions of the arches were taken and a diagnostic wax-up was performed in order to better understand the prosthetic needs. A sub-periosteal implant was designed virtually, based on the prosthetics needs. The customized implant was produced with holes for the fixing screws and the integral abutments for the support of the cemented fixed prosthetic rehabilitation.

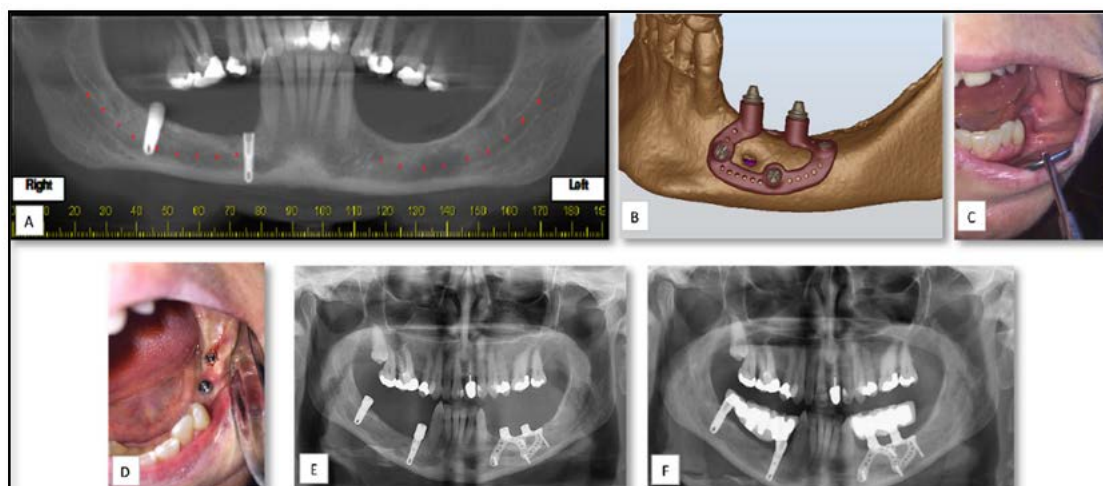


Figure 3. (A) Preoperative Cone beam computed tomography (CBCT) panoramic showed posterior edentulous mandible. (B) Pre-surgical planning and modeling of the sub-periosteal implant (C) One week after placement of the sub-periosteal implant shows proper healing. (D) One week after implant coverage and installation of dental healing caps. (E,F) Postoperative panoramic view showed the sub-periosteal implant with and without the final dental rehabilitation.

5.3. AM for PSI Manufacturing for Delayed Correction of Post-Traumatic Defects

Orbital fractures is a commonly occurring facial bone fractures and clinically important, as they may cause serious complications such as diplopia, extraocular movement limitation, and enophthalmos., resulting in loss of an aesthetically pleasing appearance [59]. A 19-year-old male was referred to our medical center for evaluation and surgical management of injuries sustained 8 month prior, secondary to a gunshot wound injury (GSW) to the right face (Figure 4). Based on his medical history, the first management of his injury included closure of soft tissue on a significant right infra-orbital laceration. Upon initial presentation at our clinic, a clinical examination revealed, facial asymmetry, significant right-sided enophthalmos, cicatricial ectropion and a sensation distribution at the infra-orbital region. Based on a CT scan, a significant avulsed bony injury of his right infraorbital rim and orbital floor was observed. Since the left orbit was not affected, a virtual 3D prototype was designed based on anatomy mirroring of the left orbit. A 3D custom-made implant was created and used to reconstruct the orbital rim and orbital floor. The final result shows a restoration of facial form and contour, with good symmetry and correction of enophthalmos.

5.4. AM for Temporomandibular Joint (TMJ) Reconstruction Surgery Due to Oncologic Resection

Metastatic lesions to the mandible and oral cavity are rare, compromising less than 1% of all malignancy [60]. Here we show a 64-year-old patient with a history of lung signet cell carcinoma that was resected two months prior to his presentation at our clinic (Figure 5). The patient was referred to our institute because of an intra-bony lesion that was noted, radiologically, in his right mandibular ramus. Incisional biopsy was taken from the lesion and metastases from the primary tumor was confirmed, histologically. Resection of the metastasis was planned after discussion with his oncologist. Resection of the tumor required removal of the condyle, resulting in loss of the TMJ but with no articular disc involvement. In this case, a 3D SLA template surgical guide was prepared and used for accurate margins of tumor resection. After resection, a custom metal implant was placed using specific screws. Excellent functional and esthetical results were noted during his follow-up.

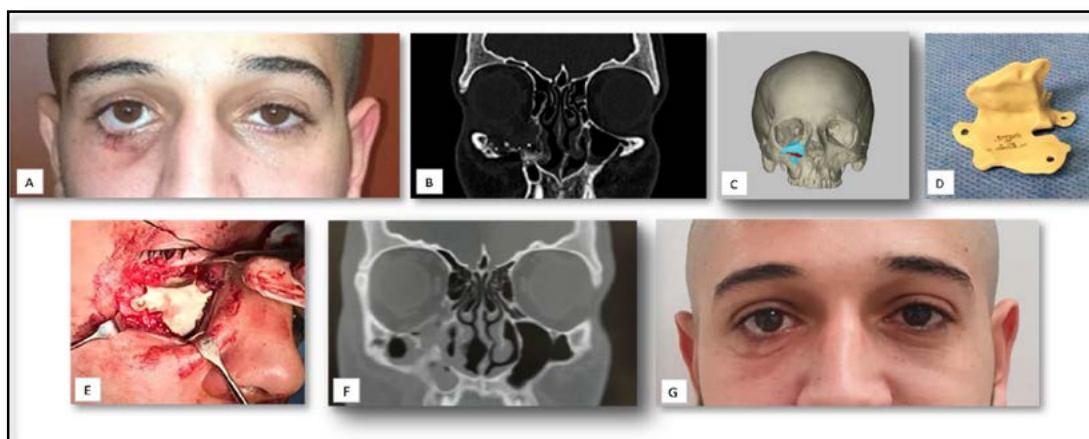


Figure 4. (A) A clinical view shows significant right-sided enophthalmos, cicatricial ectropion. (B) A preoperative coronal computed tomography (CT) scan shows the defect of the right infraorbital rim. (C) Pre-operative 3D planning. (D) Individual custom reconstruction implant. (E) A post-operative coronal CT scan shows the position of the right infraorbital rim. (F) Postoperative implant position. (G) Clinical view shows an accepted postoperative esthetic result.

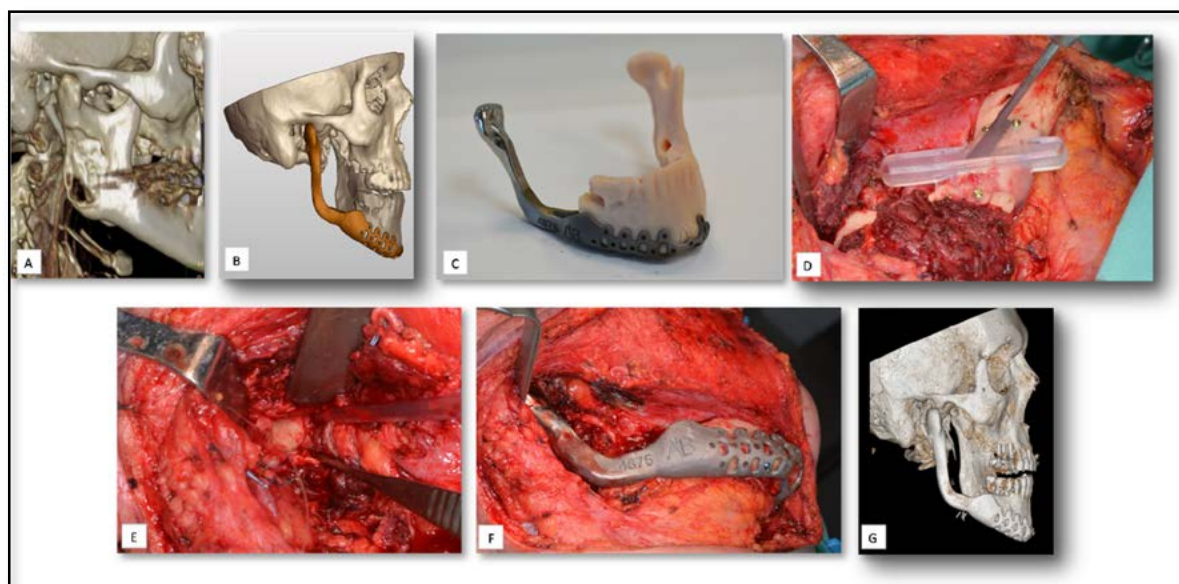


Figure 5. (A) A pre-operative 3D CT show the position and dimensions of the metastatic lesion. (B) 3D Planning including virtual removal of tumor and the virtual construction of the right temporomandibular joint (TMJ). (C) 3D printed stereolith model and metal implant after virtual removal of Tumor in the right mandibular ramus. (D) The use of the cutting guide for accurate resection based on virtual cutting plan. (E) Removal of the tumor. (F): the placement of the printed TMJ implant. (G) Postoperative CT shows the accurate position of the TMJ implant.

5.5. AM for Producing PSI for Reconstruction of Large Mandibular Defect after Tumor Resection

Squamous cell carcinoma (SCC) of oral cavity is a fatal disease caused by complex interactions between environmental, genomic and epigenetic alterations [61]. Surgical resection with microscopically clear margins of the primary tumor and prophylactic or therapeutic clearance of the neck lymph nodes, followed by various reconstructive approaches, remains the fundamental treatment for Oral Squamous Cell Carcinoma (OSCC) with adjuvant therapy reserved for high-risk disease [62–66]. Here, we present an example of use of 3D approach for reconstruction large mandibular defect following resection of

OSCC in the right mandibular body and angle. An 80-year-old man was referred to our institute for evaluation and a treatment plan due to lesion at his right mandible (Figure 6). An incisional biopsy from the lesion confirmed a diagnosis of SCC of the right mandible. A resection of the primary tumor with clear margins was performed and a reconstruction using patient specific plate was placed. The 3D reconstruction plate was planned to include two trans-mucosal implants for subsequent dental rehabilitation. However, this implant failed, and acute infection developed in conjunction with oral and skin fistula. This patient was re-treated, successfully, with free flap fibula reconstruction.

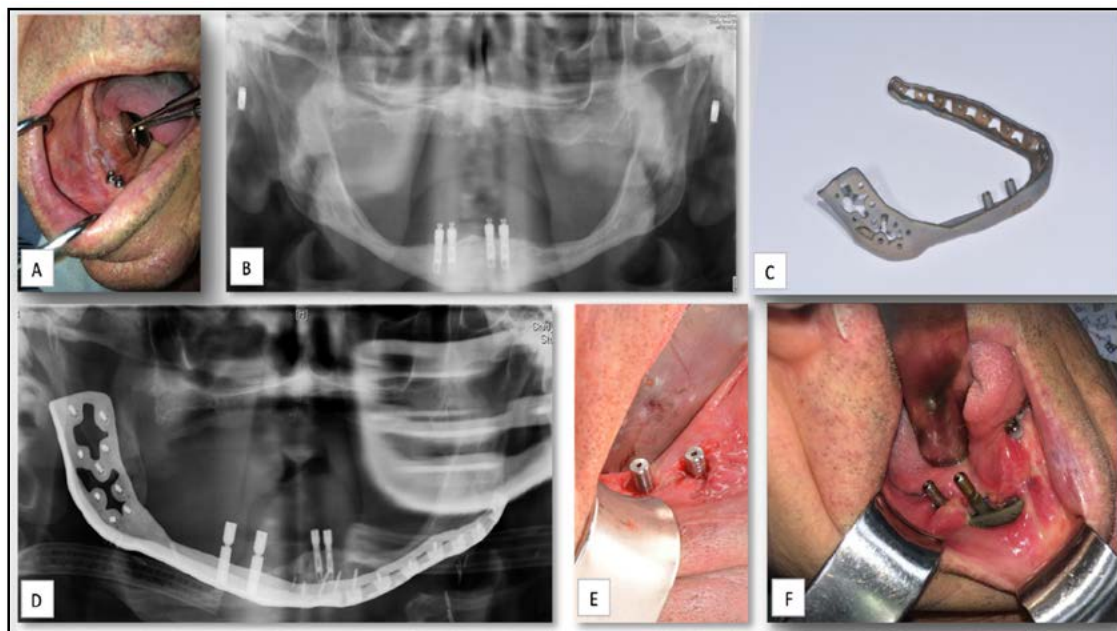


Figure 6. (A) A clinical view shows the squamous cell carcinoma (SCC) lesion on at the right posterior mandible. (B) A pre-operative panoramic view of the mandible. (C) The 3D reconstruction implant of the mandible. (D) Post-operative panoramic view shows the implanted reconstruction plate. (E) one week after the placement of the reconstruction plate shows the trans-mucosal components of the plate. (F) clinical view shows the development of postoperative infection with soft tissue dehiscence.

6. Current Challenges and Future Directions

Reconstruction of the oral and maxillofacial region is a challenging procedure since it contains several delicate parts (such as maxilla, orbits and the nasal area etc.) with extreme importance in terms of esthetic and functional ability of the patients. Accurate reconstruction surgeries along with minimization of the operation time is of crucial importance to surgeons for improving treatment outcomes.

Nowadays, more than 50% of the clinical trials of 3D printed medical devices are related to the oral and maxillofacial surgery field and most often concern anatomical models for preoperative planning and guides for aiding surgery [67,68]. In the recent years, the 3D printing technology had undergone many adjustments, improvements, enabling an accurate and durable patient-specific model's creation for complex individualized construct with high fitting properties. These changes lead to the printing of a custom-made patient reconstruction implant where the field of oral and maxillofacial surgery is leading the way in using such devices for clinical use. Various studies have showed the utility of using AM processes as an effective solution for both fabricating PSIs that fit precisely the specific anatomical defects and for pre-operative surgical simulation and planning. As seen also among our clinical examples, the AM technology is applied for printing non-biological components that are used as PSI, intra-operative surgical guides and for pre-operative planning. Indeed, these applications are to be the main indications for using the AM technology in the OMF field.

AM processes are growing and have positively influenced the medical sector by producing biological and non-biological components [69,70]. Recently, humans and animal studies showed some promising results in using bio-printing technology and opened a new avenue for alternative and innovative therapeutic methods for craniofacial defects [71]. Briefly, the bio-printing technology is defined as a single approach combining a set of techniques incorporating cells, biologically active compounds (e.g., growth factors and extracellular matrix components) within or onto a printed substrate. Different material delivery methods and technologies have since been used, including contact bio-printing (e.g., dip pen lithography, [micro]extrusion, and soft lithography) [72,73]; contactless bio-printing (e.g., laser-based forward transfer) [74] and inkjet deposition [75] and other methods. Despite different limitations and obstacles of bio-printing technology (mainly related to scaffold material and scaffold survival), the fabrication of 3D printed scaffolds seem to be a promising alternative approach for bone tissue repair in craniofacial defects [71]. Moreover, the authors believe that once the bio-printing approach is applied successfully for bone tissue repair it can then be extended for soft tissue regeneration and will change, totally, the current management of reconstructive medicine in general, and maxillofacial surgery in particular.

In terms of accurate reconstructive surgery; the accuracy of AM products is still considered to be the main challenge when such objects are printed, knowing that surfaces in contact with a bone at the surgical site need to fit closely to ensure new bone growth and such inaccuracy of printed guides and plates may lead to critical complications. Based on our experience, some printed components are not completely accurate and further minimal adjustment should be performed, intra-operatively, to fit the accurate patient anatomy. This was the intra-operative complication that we needed to deal with. Indeed, most systems used to fabricate biomedical models provide satisfactory accuracy. However, one should take into consideration that the shape, dimensions and anatomic details of prototypes may be affected by errors at any stage of the process, such as CT image acquisition, image manipulation with CAD software, or fabrication and finishing [22,76,77]. Therefore, some parameters should be carefully analyzed to ensure accuracy including: slice thickness when the CAD model is re-sliced, diameter and angle of the laser beam, properties of the used powder particles, and direction of fabrication [77,78]. The authors argue that, to overcome this limitation, work is still needed towards increasing higher-resolution printing, but without sacrificing the strength, handling properties and shape of the final implant.

The non-technology related challenges should not be underestimated, for instance, with one of the limitations being the type of the material to be used. There are very few sets of material available for printing, which present a major setback. Most of the materials used are thermoplastic, while other companies use metal, glass, carbon fibers materials. For instance, when 3D printing bone tissue using SLA only photopolymers could be used, since binder fitting for materials are not suitable in the sintering process.

Staff education is also a main challenge, and developed skills are needed in the manual stages in producing the 3D printed model, and thus staff education is also a major concern in 3D printing process. Most of the PSI products in the present clinical use, as well as in our case series, are produced by titanium material using the SLS technique. For many years, metallic implants have been the most preferred alloplastic material in PSI manufacturing due to their favorable mechanical strength and excellent friction-resistance [79–81]. However, different limitations of metal materials are reported including hypersensitivity reactions, osteolysis initiation, MRI incompatibility and the mismatching between the elastic modulus of the metal products and that of normal human bone tissues which may lead to a stress-shielding effect and prosthetic loosening. To overcome this array of limitations and others, a new alloplastic material, PEEK, has emerged and have been considered as promising material for the PSI manufacturing. Briefly, PEEK is a semicrystalline linear polycyclic aromatic thermoplastic belonging to a family of linear aromatic polymers containing ether and ketone linkages [44]. PEEK was first developed in 1978 [79] and has since been used in a wide range of applications owing to its excellent combination of high-temperature performance, chemical resistance, fatigue resistance,

lightweight, high yield strength, stiffness, and durability [44]. Various studies conducted with PEEK in reconstruction of complex maxillofacial defects and calvarial defects have shown excellent postoperative esthetic and functional results without any complications [80–82]. Although a small number of PSI were performed in the our department using the PEEK material, the authors believe that this material may be very useful for reconstruction of OMF defects, especially, at the non-sensitive sites that do not tolerate a directly applied pressure/load.

In regard of the post-operative complications; one case out of the 16 cases treated at our department showed postoperative loss of the PSI. In this case, extensive edema developed combined with exposure of the PSI and acute infection development. Infection development is well documented in the literature when using PSI devices. In such cases, the results may be catastrophic and may lead ultimately to free flap use in the best scenario. The authors speculate that this complication may be developed due to different causes including patient susceptibility, infection of the surgical wound itself that lead to the PSI exposure, the loss of sufficient soft tissue coverage due to large oncologic resection, stress shielding that leads to loose hardware, and the surface texture of the implant itself. In addition, it should be mentioned that this PSI was implanted with trans-mucosal components in an area with poor keratinized tissue, which may lead to bacterial invasion around these components. Apart from the surgical skills themselves, different studies have aimed to assess the best surface texture modification, mechanically and chemically, for improving the osteointegration process of PSI and showed that surface modification, at the microscale and nanoscale, may support osteoblastic differentiation of normal human osteoblasts and enhance the osteointegration process [83]. In another case, postoperative improper contours of the nasal bridge were noted; this patient was lost subsequently to follow-up. We believe that this may have been due to the soft tissue scars that existed in the surgical site prior to the reconstruction surgery.

A major limitation of the additive manufacturing technologies in general is the fact that there is no consensus practice, nor standardized manufacturing guidelines. Therefore, the same 3D CAD file can be translated into a wide range of models while using different additive methods. All the additive techniques require calibration, processing, and formatting to achieve the required result. However, variability between the machines and the building process may produce a lack of appropriate strength and quality and, thus, a standardized quality measurements are required to ensure that parts built meet appropriate strength and reliability requirements.

Another limitation is supporting the components structures during the printing process. In AM manufacturing, components gain strength through the building process, thus a special concern must be given to the specific processing techniques to support the components structure, and to stand the material weight, external and internal forces from the printing process. Also, additive manufacturing techniques allow internal features to be built but, nonetheless, the geometrical shape and position must be verified [84].

In summary, the utilization of additive manufacturing in craniofacial surgery has significant promise and can extend way beyond the production of custom-fit implants used for large defects in the craniofacial complex resulting from trauma, oncologic surgery, congenital disease, as well as, for surgical stimulation, training and student/resident education. We hypothesize that these enormous potential applications may continue to grow with advancements in imaging, manufacturing, and the widespread availability of more sophisticated printers. In conclusion, from the clinical point of view, additive manufacturing provides a powerful method for fabricating 3D devices based on the CT of individual patients, enabling optimal results in suitable cases. However, more clinical trials with hundreds of cases are needed to build a clear optimal algorithm for the use of this approach.

Author Contributions: Y.G., A.N. and I.A.-E.-n. conceived and designed the experiments; A.N. and A.M. analyzed the data; I.A.-E.-n. and Y.G. analysis tools; Y.G. and A.N. wrote the paper. All authors have read and agreed to the published version of the manuscript.

Funding: This research received no external funding.

Conflicts of Interest: The authors declare no conflict of interest.

References

1. Figueroa, A.A.; Gans, B.J.; Pruzansky, S. Long-term follow-up of a mandibular costochondral graft. *Oral Surg. Oral Med. Oral Pathol.* **1984**, *58*, 257–268. [\[CrossRef\]](#)
2. Padwa, B.L.; Mulliken, J.B.; Maghen, A.; Kaban, L.B. Midfacial growth after costochondral graft construction of the mandibular ramus in hemifacial microsomia. *J. Oral Maxillofac. Surg.* **1998**, *56*, 122–127. [\[CrossRef\]](#)
3. Naaj IAEI Leiser, Y.; Liberman, R.; Peled, M. The Use of the Temporalis Myofascial Flap in Oral Cancer Patients. *J. Oral Maxillofac. Surg.* **2010**, *68*, 578–583. [\[CrossRef\]](#)
4. Wu, C.-C.; Lin, P.-Y.; Chew, K.-Y.; Kuo, Y.-R. Free tissue transfers in head and neck reconstruction: Complications, outcomes and strategies for management of flap failure: Analysis of 2019 flaps in single institute. *Microsurgery* **2009**, 504–506. [\[CrossRef\]](#)
5. Marx, R.E.; Morales, M. Morbidity from bone harvest in major jaw reconstruction: A randomized trial comparing the lateral anterior and posterior approaches to the ilium. *J. Oral Maxillofac. Surg.* **1988**, *46*, 196–203. [\[CrossRef\]](#)
6. Spoerl, S.; Schoedel, S.; Spanier, G.; Mueller, K.; Meier, J.K.; Reichert, T.E.; Ettl, T. A decade of reconstructive surgery: Outcome and perspectives of free tissue transfer in the head and neck. Experience of a single center institution. *Oral Maxillofac. Surg.* **2020**, *24*, 173–179. [\[CrossRef\]](#)
7. Colaco, M.; Igel, D.A.; Atala, A. The potential of 3D printing in urological research and patient care. *Nat. Rev. Urol* **2018**, *15*, 213–221. [\[CrossRef\]](#)
8. Murphy, S.V.; Atala, A. 3D bioprinting of tissues and organs. *Nat. Biotechnol.* **2014**, *32*, 773–785. [\[CrossRef\]](#)
9. Kodama, H. Automatic method for fabricating a three-dimensional plastic model with photo-hardening polymer. *Rev. Sci. Instrum.* **1998**, *52*, 2–6. [\[CrossRef\]](#)
10. Zhu, W.; Ma, X.; Gou, M.; Mei, D.; Zhang, K.; Chen, S. 3D printing of functional biomaterials for tissue engineering. *Curr. Opin Biotechnol.* **2016**, *40*, 103–112. [\[CrossRef\]](#)
11. Singh, S.; Ramakrishna, S.; Singh, R. Material issues in additive manufacturing: A review. *J. Manuf. Process.* **2017**, *25*, 185–200. [\[CrossRef\]](#)
12. Rengier, F.; Mehndiratta, A.; Von Tengg-Kobligh, H.; Zechmann, C.M.; Unterhinninghofen, R.; Kauczor, H.U.; Giesel, F.L. 3D printing based on imaging data: Review of medical applications. *Int. J. Comput. Assist. Radiol. Surg.* **2010**, *5*, 335–341. [\[CrossRef\]](#) [\[PubMed\]](#)
13. Gibson, I.; Rosen, D.; Stucker, B. *Additive Manufacturing Technologies: 3D Printing, Rapid Prototyping, and Direct Digital Manufacturing*, 2nd ed.; Springer: New York, NY, USA, 2015; pp. 375–397. [\[CrossRef\]](#)
14. Hegab, H.A. Design for additive manufacturing of composite materials and potential alloys: A review. *Manuf. Rev.* **2016**, *3*. [\[CrossRef\]](#)
15. Bourell, D.L. Perspectives on Additive Manufacturing. *Ann. Rev. Mater. Res.* **2016**, *46*, 1–18. [\[CrossRef\]](#)
16. Giannatsis, J.; Dedoussis, V. Additive fabrication technologies applied to medicine and health care: A review. *Int. J. Adv. Manuf. Technol.* **2009**, *40*, 116–127. [\[CrossRef\]](#)
17. Goffard, R.; Sforza, T.; Clarinval, A.; Dormal, T.; Boilet, L.; Hocquet, S.; Cambier, F. Additive manufacturing of biocompatible ceramics. *Adv. Prod. Eng. Manag.* **2013**, *8*, 96–106. [\[CrossRef\]](#)
18. Murr, L.E.; Gaytan, S.M.; Medina, F.; Lopez, H.; Martinez, E.; MacHado, B.I.; Hernandez, D.H.; Lopez, M.I.; Wicker, R.B.; Bracke, J. Next-generation biomedical implants using additive manufacturing of complex cellular and functional mesh arrays. *Philos Trans. R Soc. A Math. Phys. Eng. Sci* **2010**, *368*, 1999–2032. [\[CrossRef\]](#)
19. Frame, M.; Huntley, J.S. Rapid prototyping in orthopaedic surgery: A user's guide. *Sci. World J.* **2012**, 2012. [\[CrossRef\]](#)
20. Cunningham, L.L.; Madsen, M.J.; Peterson, G. Stereolithographic modeling technology applied to tumor resection. *J. Oral Maxillofac. Surg.* **2005**, *63*, 873–878. [\[CrossRef\]](#)
21. Frühwald, J.; Schicho, K.A.; Figl, M.; Benesch, T.; Watzinger, F.; Kainberger, F. Accuracy of craniofacial measurements: Computed tomography and three-dimensional computed tomography compared with stereolithographic models. *J. Craniofac. Surg.* **2008**, *19*, 22–26. [\[CrossRef\]](#)
22. Barker, T.M.; Earwaker, W.J.S.; Lisle, D.A. Accuracy of stereolithographic models of human anatomy. *Australas. Radiol.* **1994**, *38*, 106–111. [\[CrossRef\]](#) [\[PubMed\]](#)
23. Schicho, K.; Figl, M.; Seemann, R.; Ewers, R.; Lambrecht, J.T.; Wagner, A.; Watzinger, F.; Baumann, A.; Kainberger, F.; Fruehwald, J.; et al. Accuracy of treatment planning based on stereolithography in computer assisted surgery. *Med. Phys.* **2006**, *33*, 3408–3417. [\[CrossRef\]](#) [\[PubMed\]](#)

24. Mazzoli, A.; Germani, M.; Moriconi, G. Application of Optical Digitizing Techniques to Evaluate the Shape Accuracy of Anatomical Models Derived From Computed Tomography Data. *J. Oral Maxillofac. Surg.* **2007**, *65*, 1410–1418. [[CrossRef](#)] [[PubMed](#)]
25. Wong, T.Y.; Fang, J.J.; Chung, C.H.; Huang, J.S.; Lee, J.W. Comparison of 2 methods of making surgical models for correction of facial asymmetry. *J. Oral Maxillofac. Surg.* **2005**, *63*, 200–208. [[CrossRef](#)] [[PubMed](#)]
26. Chow, L.K.; Cheung, L.K. The Usefulness of Stereomodels in Maxillofacial Surgical Management. *J. Oral Maxillofac. Surg.* **2007**, *65*, 2260–2268. [[CrossRef](#)] [[PubMed](#)]
27. Mehra, P.; Miner, J.; D’Innocenzo, R.; Nadershah, M. Use of 3-D Stereolithographic Models in Oral and Maxillofacial Surgery. *J. Maxillofac. Oral Surg.* **2011**, *10*, 6–13. [[CrossRef](#)] [[PubMed](#)]
28. Gu, D.D.; Meiners, W.; Wissenbach, K.; Poprawe, R. Laser additive manufacturing of metallic components: Materials, processes and mechanisms. *Int. Mater. Rev.* **2012**, *57*, 133–164. [[CrossRef](#)]
29. Fischer, P.; Romano, V.; Blatter, A.; Weber, H.P. Highly precise pulsed selective laser sintering of metallic powders. *Laser Phys. Lett* **2005**, *2*, 48–55. [[CrossRef](#)]
30. Schleifenbaum, H.; Meiners, W.; Wissenbach, K.; Hinke, C. Individualized production by means of high power Selective Laser Melting. *CIRP J. Manuf. Sci. Technol.* **2010**, *2*, 161–169. [[CrossRef](#)]
31. Ciocca, L.; Fantini, M.; De Crescenzo, F.; Corinaldesi, G.; Scotti, R. Direct metal laser sintering (DMLS) of a customized titanium mesh for prosthetically guided bone regeneration of atrophic maxillary arches. *Med. Biol. Eng. Comput.* **2011**, *49*, 1347–1352. [[CrossRef](#)]
32. Mangano, F.G.; De Franco, M.; Caprioglio, A.; MacChi, A.; Piattelli, A.; Mangano, C. Immediate, non-submerged, root-analogue direct laser metal sintering (DLMS) implants: A 1-year prospective study on 15 patients. *Lasers Med. Sci.* **2014**, *29*, 1321–1328. [[CrossRef](#)] [[PubMed](#)]
33. Mangano, F.G.; Cirotti, B.; Sammons, R.L.; Mangano, C. Custom-made, root-analogue direct laser metal forming implant: A case report. *Lasers Med. Sci.* **2012**, *27*, 1241–1245. [[CrossRef](#)] [[PubMed](#)]
34. Sannomiya, E.K.; Silva, J.V.L.; Brito, A.A.; Saez, D.M.; Angelieri, F.; da Silva Dalben, G. Surgical planning for resection of an ameloblastoma and reconstruction of the mandible using a selective laser sintering 3D biomodel. *Oral Surg. Oral Med. Oral Pathol Oral Radiol. Endodontol.* **2008**, *106*, 36–40. [[CrossRef](#)] [[PubMed](#)]
35. Leiggener, C.; Messo, E.; Thor, A.; Zeilhofer, H.F.; Hirsch, J.M. A selective laser sintering guide for transferring a virtual plan to real time surgery in composite mandibular reconstruction with free fibula osseous flaps. *Int. J. Oral Maxillofac. Surg.* **2009**, *38*, 187–192. [[CrossRef](#)] [[PubMed](#)]
36. Rodr, E.; Kypson, A.P.; Moten, S.C.; Nifong, L.W.; Chitwood, W.R., Jr. Robotic mitral surgery at East Carolina University: A 6-year experience. *Int. J. Med. Robot. Comput. Assist. Surg.* **2006**, *2*, 211–215. [[CrossRef](#)]
37. Williams, J.V.; Revington, P.J. Novel use of an aerospace selective laser sintering machine for rapid prototyping of an orbital blowout fracture. *Int. J. Oral Maxillofac. Surg.* **2010**, *39*, 182–184. [[CrossRef](#)]
38. Rotaru, H.; Băciut, M.; Stan, H.; Bran, S.; Chezan, H.; Iosif, A.; Tomescu, M.; Kim, S.G.; Rotaru, A. Silicone rubber mould cast polyethylmethacrylate-hydroxyapatite plate used for repairing a large skull defect. *J. Cranio-Maxillofac. Surg.* **2006**, *34*, 242–246. [[CrossRef](#)]
39. Aung, S.C.; Tan, B.K.; Foo, C.L.; Lee, S.T. Selective laser sintering: Application of a rapid prototyping method in craniomaxillofacial reconstructive surgery. *Ann. Acad. Med.* **1999**, *28*, 739–743.
40. Turner, B.N.; Gold, S.A. A review of melt extrusion additive manufacturing processes: II. Materials, dimensional accuracy, and surface roughness. *Rapid Prototyp. J.* **2015**, *21*, 250–261. [[CrossRef](#)]
41. Turner, B.N.; Strong, R.; Gold, S.A. A review of melt extrusion additive manufacturing processes: I. Process design and modeling. *Rapid Prototyp. J.* **2014**, *20*, 192–204. [[CrossRef](#)]
42. Valkenaers, H.; Vogeler, F.; Ferraris, E.; Voet, A.; Kruth, J.-P. A novel approach to additive manufacturing: Screw extrusion 3D-printing. In Proceedings of the 10th International Conference on Multi-Material Micro Manufacture, San Sebastian, Spain, 1 October 2013.
43. Crump, S. Apparatus and Method for Creating Three-Dimensional Objects. US Patent 07/429,012, 30 October 1989.
44. Ma, R.; Tang, T. Current strategies to improve the bioactivity of PEEK. *Int. J. Mol. Sci.* **2014**, *15*, 5426–5445. [[CrossRef](#)] [[PubMed](#)]
45. Honigsmann, P.; Sharma, N.; Okolo, B.; Popp, U.; Msallem, B.; Thieringer, F.M. Patient-specific surgical implants made of 3D printed PEEK: Material, technology, and scope of surgical application. *Biomed. Res. Int.* **2018**, *2018*. [[CrossRef](#)] [[PubMed](#)]

46. Available online: <http://3dprintingindustry.com/3d-printing-basics-free-beginners-guide/materials/> (accessed on 15 December 2020).
47. Available online: <https://www.stratasysdirect.com/resources/choosing-the-right-material-for-your-application/> (accessed on 15 December 2020).
48. Chow, J. A novel device for template-guided surgery of the zygomatic implants. *Int. J. Oral Maxillofac. Surg.* **2016**, *45*, 1253–1255. [CrossRef] [PubMed]
49. Wang, C.I.; Cho, S.H.; Cho, D.; Ducote, C.; Reddy, L.V.; Sinada, N. A 3D-Printed Guide to Assist in Sinus Slot Preparation for the Optimization of Zygomatic Implant Axis Trajectory. *J. Prosthodont.* **2020**, *29*, 179–184. [CrossRef] [PubMed]
50. Becker, C.M.; Kaiser, D.A. Surgical guide for dental implant placement. *J. Prosthet. Dent.* **2000**, *83*, 248–251. [CrossRef]
51. Goiato, M.C.; Pellizzer, E.P.; Moreno, A.; Gennari-Filho, H.; Dos Santos, D.M.; Santiago, J.F.; Santos, E.G. Implants in the zygomatic bone for maxillary prosthetic rehabilitation: A systematic review. *Int. J. Oral Maxillofac. Surg.* **2014**, *43*, 748–757. [CrossRef]
52. Rocchietta, I.; Fontana, F.; Simion, M. Clinical outcomes of vertical bone augmentation to enable dental implant placement: A systematic review. *J. Clin. Periodontol.* **2008**, *35*, 203–215. [CrossRef]
53. Esposito, M.; Grusovin, M.G.; Coulthard, P.; Worthington, H.V. The efficacy of various bone augmentation procedures for dental implants: A Cochrane systematic review of randomized controlled clinical trials. *Int. J. Oral Maxillofac. Implant.* **2006**, *21*, 696–710.
54. Jensen, O.T.; Greer, R.O., Jr.; Johnson, L.K.D. Vertical guided bone-graft augmentation in a new canine mandibular model. *Int. J. Oral Maxillofac. Implant.* **1995**, *10*, 335–344.
55. Jung, R.E.; Fenner, N.; Hämmerle, C.H.F.; Zitzmann, N.U. Long-term outcome of implants placed with guided bone regeneration (GBR) using resorbable and non-resorbable membranes after 12–14 years. *Clin. Oral Implant. Res.* **2013**, *24*, 1065–1073. [CrossRef]
56. McCarthy, J.G.; Schreiber, J.; Karp, N.; Thorne, C.H.; Grayson, B. Lengthening the human mandible by gradual distraction. *Plast Reconstr. Surg.* **1992**, *89*, 1–10. [CrossRef] [PubMed]
57. Rachmiel, A.; Srouji, S.; Peled, M. Alveolar ridge augmentation by distraction osteogenesis. *Int. J. Oral Maxillofac. Surg.* **2001**, *30*, 510–517. [CrossRef] [PubMed]
58. Cerea, M.; Dolcini, G.A. Custom-made direct metal laser sintering titanium subperiosteal implants: A retrospective clinical study on 70 patients. *Biomed. Res. Int.* **2018**, *2018*. [CrossRef] [PubMed]
59. Shin, J.W.; Lim, J.S.; Yoo, G.; Byeon, J.H. An analysis of pure blowout fractures and associated ocular symptoms. *J. Craniofac. Surg.* **2013**, *24*, 703–707. [CrossRef] [PubMed]
60. Schwartz, M.L.; Baredes, S.; Mignogna, F.V. Metastatic Disease To the Mandible. *Laryngoscope* **1988**, *98*, 270–273. [CrossRef]
61. Ghantous, Y.; Nashef, A.; Abu-Elnaaj, I. Epigenetic Alterations Associated with the Overall Survival and Recurrence Free Survival among Oral Squamous Cell Carcinoma Patients. *J. Clin. Med.* **2020**, *9*, 1035. [CrossRef]
62. Joo, Y.H.; Cho, J.K.; Koo, B.S.; Kwon, M.; Kwon, S.K.; Kwon, S.Y.; Kim, M.-S.; Kim, J.K.; Kim, H.; Nam, I.; et al. Guidelines for the surgical management of oral cancer: Korean society of thyroid-head and neck surgery. *Clin. Exp. Otorhinolaryngol.* **2019**, *12*, 107–144. [CrossRef]
63. Pfister, D.G.; Spencer, S.; Brizel, D.M.; Burtress, B.; Busse, P.M.; Caudell, J.J.; Cmelak, A.J.; Colevas, A.D.; Dunphy, F.; Eisele, D.W.; et al. Head and neck cancers, version 2.2014. *JNCCN J. Natl. Compr. Cancer Netw.* **2014**, *12*, 1454–1487. [CrossRef]
64. Di Taranto, G.; Chen, S.H.; Elia, R.; Sitpahul, N.; Chan, J.C.Y.; Losco, L.; Cigna, E.; Ribuffo, D.; Chen, H. Outcomes following head neck free flap reconstruction requiring interposition vein graft or vascular bridge flap. *Head Neck* **2019**, *41*, 2914–2920. [CrossRef]
65. Jain, P.V.; Sharan, R.; Manikantan, K.; Clark, G.M.; Chatterjee, S.; Mallick, I.; Roy, P.; Arun, P. Redefining adequate margins in oral squamous cell carcinoma: Outcomes from close and positive margins. *Eur. Arch. Oto-Rhino-Laryngol.* **2020**, *277*, 1155–1165. [CrossRef]
66. Chi, A.C.; Day, T.A.; Neville, B.W. Oral cavity and oropharyngeal squamous cell carcinoma-an update. *CA Cancer J. Clin.* **2015**, *65*, 401–421. [CrossRef] [PubMed]
67. Diment, L.E.; Thompson, M.S.; Bergmann, J.H.M. Clinical efficacy and effectiveness of 3D printing: A systematic review. *BMJ Open* **2017**, *7*. [CrossRef] [PubMed]


68. Tack, P.; Victor, J.; Gemmel, P.; Annemans, L. 3D-printing techniques in a medical setting: A systematic literature review. *Biomed. Eng. Online* **2016**, *15*, 1–21. [[CrossRef](#)] [[PubMed](#)]
69. Kruth, J.P. Material Incess Manufacturing by Rapid Prototyping Techniques. *CIRP Ann. Manuf. Technol.* **1991**, *40*, 603–614. [[CrossRef](#)]
70. Heller, T.B.; Hill, R.M.; Saggal, A.F. Apparatus for Forming a Solid Three-Dimensional Article from a Liquid Medium. U.S. Patent 5,071,337, 10 December 1991.
71. Maroulakos, M.; Kamperos, G.; Tayebi, L.; Halazonetis, D.; Ren, Y. Applications of 3D printing on craniofacial bone repair: A systematic review. *J. Dent.* **2019**, *80*, 1–14. [[CrossRef](#)]
72. Roth, E.A.; Xu, T.; Das, M.; Gregory, C.; Hickman, J.J.; Boland, T. Inkjet printing for high-throughput cell patterning. *Biomaterials* **2004**, *25*, 3707–3715. [[CrossRef](#)]
73. Ringeisen, B.R.; Othon, C.M.; Barron, J.A.; Young, D.; Spargo, B.J. Jet-based methods to print living cells. *Biotechnol. J.* **2006**, *1*, 930–948. [[CrossRef](#)]
74. Wu, P.K.; Ringeisen, B.R. Development of human umbilical vein endothelial cell (HUVEC) and human umbilical vein smooth muscle cell (HUVSMC) branch/stem structures on hydrogel layers via biological laser printing (BioLP). *Biofabrication* **2010**, *2*. [[CrossRef](#)]
75. Cui, X.; Breitenkamp, K.; Finn, M.G.; Lotz, M.; D’Lima, D.D. Direct human cartilage repair using three-dimensional bioprinting technology. *Tissue Eng. Part. A* **2012**, *18*, 1304–1312. [[CrossRef](#)]
76. Choi, J.Y.; Choi, J.H.; Kim, N.K.; Kim, Y.; Lee, J.K.; Kim, M.K. Analysis of errors in medical rapid prototyping models. *Int. J. Oral Maxillofac. Surg.* **2002**, *31*, 23–32. [[CrossRef](#)]
77. Tang, Y.; Loh, H.T.; Fuh, J.Y.H.; Wong, Y.S.; Lu, L.; Ning, Y.; Wang, X. Accuracy analysis and improvement for direct laser sintering. *Innov. Manuf. Syst. Technol.* **2004**, 119260.
78. Nizama, A.; Gopal, R.; Naing, N.L.; Hakim, A.B.; Samsudin, A.R. Dimensional accuracy of the skull models produced by rapid prototyping technology using stereolithography apparatus. *Arch. Orofac. Sci.* **2006**, *1*, 60–66.
79. Eschbach, L. Nonresorbable polymers in bone surgery. *Injury* **2000**, *31*, 22–27. [[CrossRef](#)]
80. Jardini, A.L.; Larosa, M.A.; Maciel Filho, R.; de Carvalho Zavaglia, C.A.; Bernardes, L.F.; Lambert, C.S.; Calderoni, D.R.; Kharmandayan, P. Cranial reconstruction: 3D biomodel and custom-built implant created using additive manufacturing. *J. Cranio-Maxillofac. Surg.* **2014**, *42*, 1877–1884. [[CrossRef](#)] [[PubMed](#)]
81. Kim, M.M.; Boahene, K.D.O.; Byrne, P.J. Use of customized polyetheretherketone (PEEK) implants in the reconstruction of complex maxillofacial defects. *Arch Facial Plast Surg.* **2009**, *11*, 53–57. [[CrossRef](#)] [[PubMed](#)]
82. Thieringer, F.M.; Sharma, N.; Mootien, A.; Schumacher, R.; Honigsmann, P. *Patient Specific Implants from a 3D Printer—An Innovative Manufacturing Process for Custom PEEK Implants in Cranio-Maxillofacial Surgery*; Springer: Cham, Switzerland, 2017.
83. Cohen, D.J.; Cheng, A.; Kahn, A.; Aviram, M.; Whitehead, A.J.; Hyzy, S.L.; Clohessy, R.M.; Boyan, B.; Schwartz, Z. Novel osteogenic Ti-6Al-4V device for restoration of dental function in patients with large bone deficiencies: Design, development and implementation. *Sci. Rep.* **2016**, *6*. [[CrossRef](#)]
84. Thompson, M.K.; Moroni, G.; Vaneker, T.; Fadel, G.; Campbell, R.I.; Gibson, I.; Bernard, A.; Schulz, J.; Graf, P.; Ahuja, B.; et al. Design for Additive Manufacturing: Trends, opportunities, considerations, and constraints. *CIRP Ann.* **2016**, *65*, 737–760. [[CrossRef](#)]

Publisher’s Note: MDPI stays neutral with regard to jurisdictional claims in published maps and institutional affiliations.



© 2020 by the authors. Licensee MDPI, Basel, Switzerland. This article is an open access article distributed under the terms and conditions of the Creative Commons Attribution (CC BY) license (<http://creativecommons.org/licenses/by/4.0/>).

Platform switch hybrid zygoma implants improve prosthetics and marginal bone protection after extra-sinus placement

Paweł Aleksandrowicz PhD, MD, DDS¹  | Marta Kusa-Podkańska PhD, DDS¹ |
Witold Tomkiewicz MD² | Lidia Kotuła PhD, MD³ | Jan Perek DDS² |
Joanna Wysokińska-Miszczuk PhD prof. DDS¹

¹Department of Periodontology, Medical University of Lublin, Lublin, Poland

²Department of Oral Surgery, Medical University of Warsaw, Warsaw, Poland

³Department of Clinical Genetics, Medical University of Lublin, Lublin, Poland

Correspondence

Paweł Aleksandrowicz, Katedra i Zakład Periodontologii Uniwersytetu Medycznego w Lublinie, 20-081 Lublin, Ul. Karmelicka 7, Poland.
Email: pawel.aleksandrowicz@umlub.pl

Abstract

Purpose: The aim of our study is clinical evaluation of Platform switch hybrid zygoma implants.

Materials and Methods: 117 zygomatic implants were followed up during this time. They included 55 Brånemark System zygoma implants, 38 Noris implants, and 24 novel iRES hybrid implants with platform switch.

Results: Bone quality and quantity are the prerequisite for successful implant treatment. Zygomatic implants are intended for patients with severely resorbed maxilla that cannot accommodate conventional implants without prior extensive bone grafting. Such regenerative procedures, like sinus lifts, prolong implant rehabilitation to several months (12–18). Furthermore, extensive grafts are less predictable showing varying degrees of graft resorption. Zygoma implants enable full, often immediate, reconstruction of the upper dental arch without the need for sinus lift treatment. The original zygoma protocol runs the implants through the sinus, requires general anesthesia, and positions the prosthetic platform of the implants on the palate, which makes prosthesis cumbersome. It also induces risk for post-op sinusitis. Extra-sinus approach with novel zygoma hybrid implants bypasses sinuses and positions the implant prosthetic platform on the crest allowing for same good prosthetics as on conventional dental implants. Furthermore, crestal threads and a platform-switch, of the novel zygoma design, increase implant anchorage and minimize marginal bone loss. The study presents evolution of zygoma implant rehabilitation protocol and zygoma implant design in our clinical practice over 15 years (2004–2019).

Conclusion: Extra-sinus zygomatic implant placement lowers the risk of post-op sinusitis and makes procedure possible to be done in local anesthesia.

KEYWORDS

edentulous atrophic maxilla, extra-sinus, platform switch, zygoma implants

This is an open access article under the terms of the Creative Commons Attribution License, which permits use, distribution and reproduction in any medium, provided the original work is properly cited.

© 2020 The Authors. *Clinical Implant Dentistry and Related Research* Published by Wiley Periodicals, Inc.

1 | INTRODUCTION

Loss of teeth leads to bone atrophy of the alveolar crest¹⁻⁹ up to 1/3 of the original height within a few weeks after extraction. In the following years, atrophy progresses both from the crest and the sinus as a result of invasive proliferation of the maxillary sinus mucosa.¹⁰

The shape and structure of the zygomatic bones presented good anchorage alternative for longer implants (zygomatic implants). The efficacy of rehabilitation with zygomatic implants in maxilla is well documented.¹¹⁻¹³ The limitations for the more comprehensive use of this method were invasive surgery under general anesthesia and prosthetic challenges with palatally positioned implant heads.

This study presents evolution of the protocol from intrasinus in general anesthesia into extra-sinus in local anesthesia¹⁴ and from palatal to crestal position of the implant heads for easier prosthetics. These changes required a new implant design: hybrid surface with crestal threads and platform-switch internal connection for better anchorage and marginal bone care.

Zygomatic implants first introduced by professor Per-Ingvar Brånemark in 1988³ had machined surface and a lengths from 35 to 52.5 mm. The original protocol was two zygoma implants placed bilaterally (one on each side) and four regular implants in the anterior maxilla. Zygomatic implants ran through the lumen of the maxillary sinus, with the implant heads sticking out on the palatal side of the alveolar crest¹⁵ (Figure 1).

Zygoma implants reduced overall treatment (full upper arch rehabilitation) time and eliminated the need for bone grafting into maxillary sinus.^{16,17} The protocol was then modified to four zygomatic implants two on each side¹⁸ for patients who do not have enough bone in the front of maxilla.

The goal of our clinical research was first to facilitate prosthetics by moving the implant heads to the crestal ridge. Therefore, we began to place zygoma implants more mesially, in the front of maxilla.¹⁹ The 30 mm implants went through the sinus cavity and the implant heads stuck out at the second molar site. Prosthetics became normal then and did not require any additional prosthetic elements towards the palate.

Then we wanted to bypass the sinus to make procedure less invasive and minimize the risk of post-op sinusitis. So we went with drills more buccally that the implant does not pass through the maxillary sinus but runs in the sinus wall or outside. Crestally we wanted to preserve a bony bridge around implant head as much as possible to prevent soft tissue recession around the prosthetic abutment. We used implants 40 or 45 mm^{20,21} long. The implant head was at the position of second premolar or first molar but not exactly on the crest. In this protocol, however, prosthetic framework had to be thicker and palatal extensions were often necessary.

Further evolution of the protocol for extra-sinus placement considered improvement of abutment position and also how to avoid mucosal recession around it (Figure 2). We needed an implant with crestal thread and internal platform switch connection so the implant could be placed below the crest (subcrestal placement) with prosthetic abutment emerging on the top of the alveolar crest (Figure 3).

The novel implant is a hybrid with rough (sand blasted and double attached) surface at the intra-zygomatic apex, machined surface at nonthreaded central part (in contact with the maxillary sinus wall or cavity), and crestal threads to minimize periimplantitis risk there. Implants are 30 to 65 mm long and are adapted to the surgical protocol with Le Fort I simultaneous osteotomy. The Multi-Unit abutments have a "fleur-de-lys" emerging profile with platform-switch for both bone and soft tissues (Figure 4).

The hybrid implant's surgical protocol involves the extra-sinus implant placement in the zygomatic bone body. The hybrid implant needs to be placed subcrestally in order to position the abutment on the top of the alveolar crest.

Fat pads soft tissue augmentation. In patients with a thin mucosal biotype we did soft tissue augmentation with pedunculated Bichata/Corpus adiposum buccae/fat pads (Figure 5) to avoid mucosal recession around the abutment.

2 | ANESTHESIA

The extra-sinus zygoma implants were done in local anesthesia both intra-oral and extra-oral, percutaneously in the zygomatic bone area to detach the periosteum for subsequent preparation of the mucoperiosteal flap as well as detachment of the muscle *m. zygomaticus major et minor* attachment.

We also performed the procedure under general anesthesia at the patient's request.



FIGURE 2 Patient with advanced periodontal disease rehabilitated with Noris zygomatic implants—x-rays before and after surgery. Extraoral images at 1 year follow up—visible

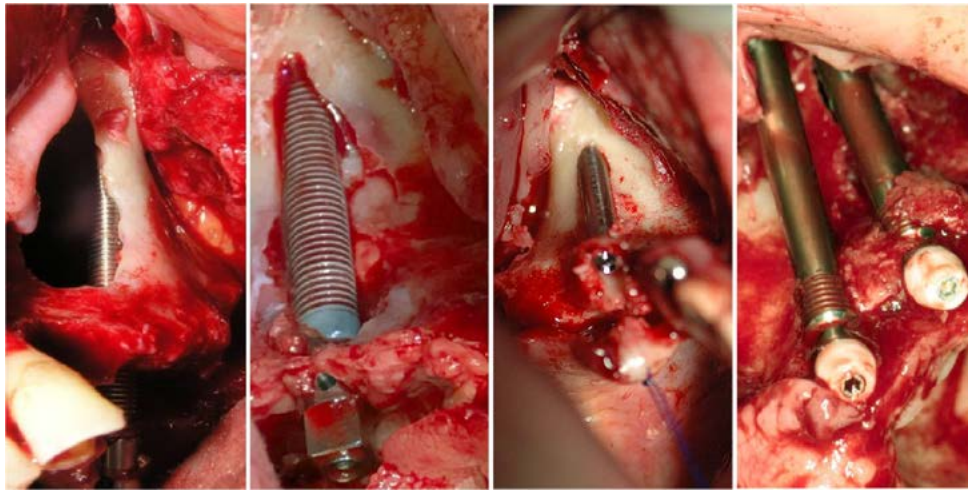


FIGURE 1 Evolution of zygoma implants and surgical protocol

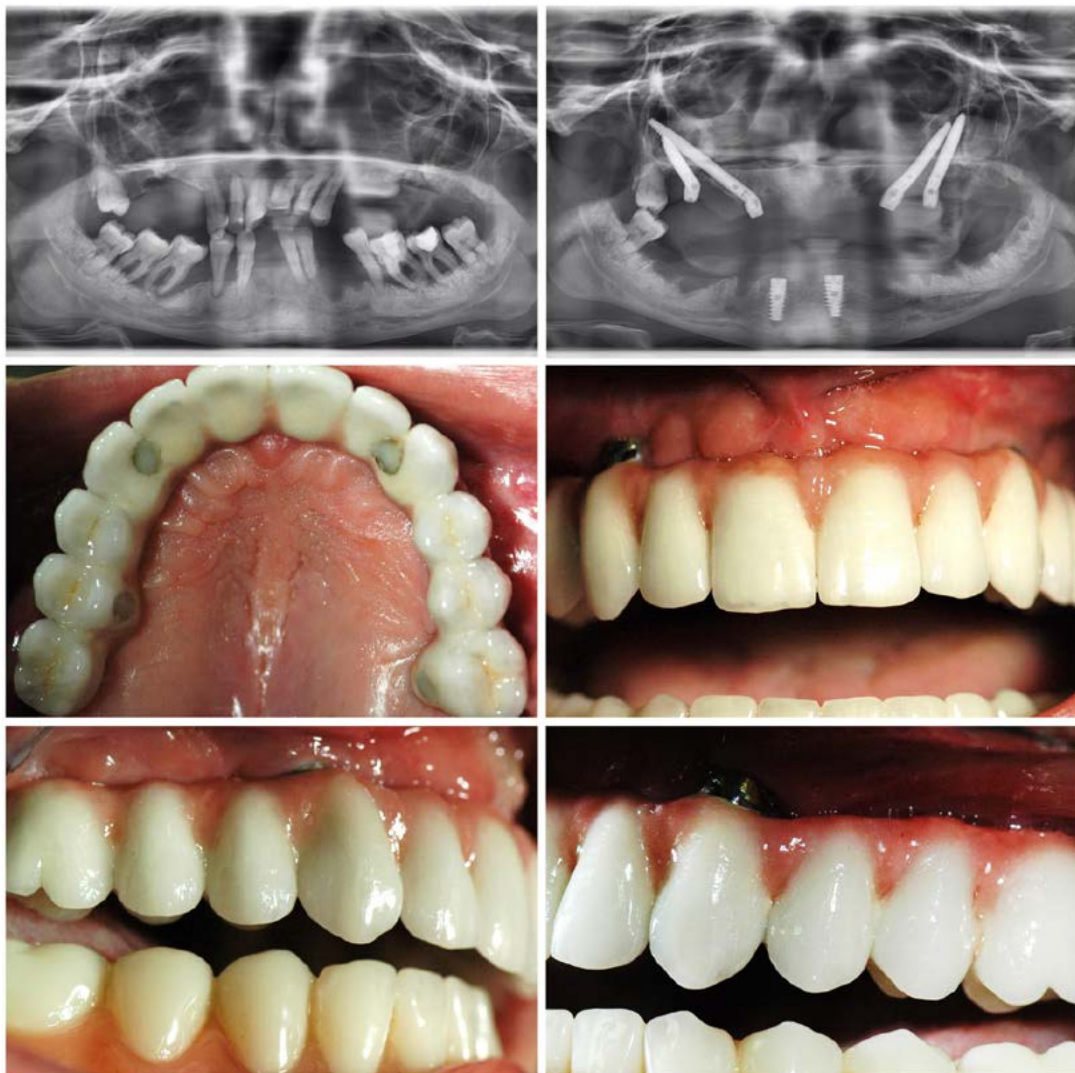

FIGURE 3 Zygomatic hybrid implant with "platform-switch" prosthetic connection

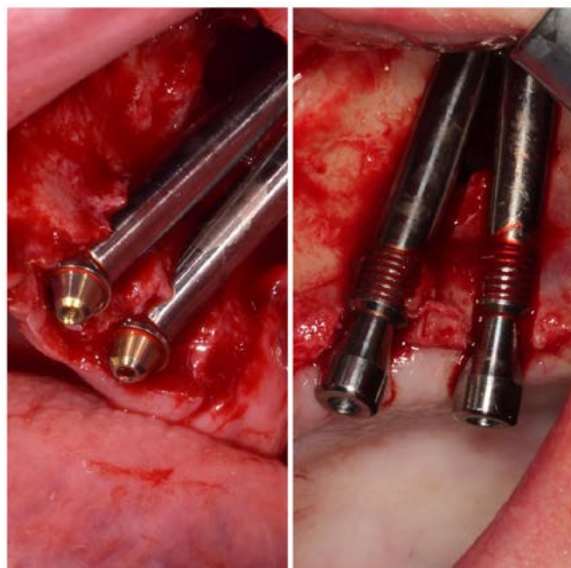


FIGURE 4 Two types of zygomatic implants classic left—(Noris Medical) and right—hybrid with platform-switch (iRES)

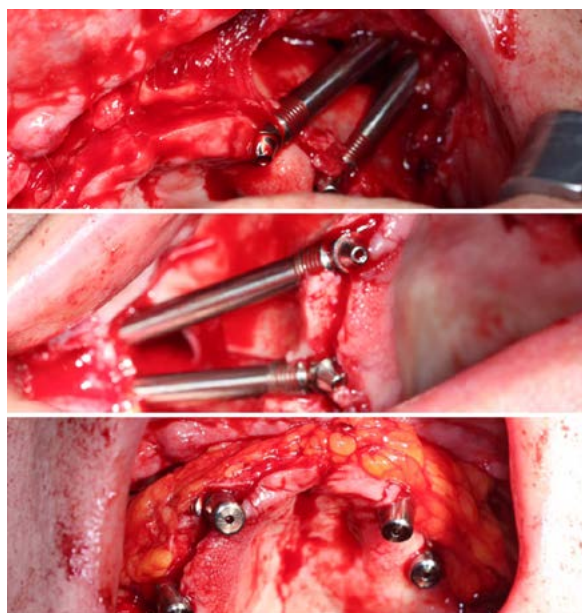


FIGURE 5 Augmentation of soft tissues with fat pads Corpus adiposum buccae

After a thorough physical examination, we qualify the patient for surgery according to the ASA scale. Due to the extent of the procedure and its duration, we use general anesthesia in a complex manner—intravenously and intratracheally. We collect a patient's consent each time after routine preanesthetic testing and risk assessment. We place the patient in a prone position—with the option of using the Trendelenburg position. Then we use standard vital functions monitoring, that is, automatic periodic RR measurement, ECG recording from four precordial leads, pulse, and arterial blood saturation recording. We perform venipuncture with a 1.4 mm Venflon cannula and intravenous induction: Fentanyl 0.002 mg/kg + Norcuron 0.07 mg/kg + Thiopental 3.45 mg/kg—using passive oxygenation with 100% oxygen at the same time. Switching to active oxygenation—after muscle relaxation—we perform atraumatic tracheal intubation through the nose—a 7 mm diameter profiled pulmonary silicone tube with a low-pressure sealing cuff. After establishing the artificial respiration and starting ventilation in CMV mode with 100% oxygen, we change the breathing mixture to 67% nitrous oxide and 33% oxygen using a standard anesthesia fan—for example, Fabius-Draeger with full control of ventilation parameters. We use Fentanyl—0.0005 mg/kg/h to carry out anesthesia, Norcuron 0.01 mg/kg/h for relaxation and isotonic fluids/PWE/2.5 mL/kg/h. After the procedure, there is a transition to 100% oxygen and spontaneous breathing. Then, after achieving full contact and recovery of the patient's muscular strength, we carry out extubation. After the procedure, we apply postoperative analgesia with an automatic syringe Fentanyl 0.0006 mg/kg/h for 24 hours with a positive result according to the subjective pain scale.

3 | MATERIALS AND METHODS

The study involved 29 women and 20 men aged 33 to 81 who were treated at the Department of Periodontology of the Medical University in Lublin. Patients were qualified for surgery by one doctor after ENT consultation. Among the patients 16 were treated for hypertension and six were smokers.

Each patient had an OPG and CBCT scans done for optimal diagnostics. The first patient in the study group received zygomatic implants in 2004 and the last patient in 2019. The cumulative follow up was 180 months.

The study protocol was positively evaluated by the local Bioethics Committees at the Medical University of Lublin on day January 31, 2019 (number resolution KE-Q254/43/2019).

TABLE 1 Position of the implant in relation to the maxillary sinus

Position of the implant (1—in the sinus lumen; 2—extra-sinus)	A (Group: zygomatic implants)		B (Group: Noris implants)		C (Group: hybrid implants)	
	N	%	N	%	N	%
1	40	72.73	1	2.63	0	0.00
2	15	27.27	37	97.37	24	100.00

Note: "1"—N = 41 (35.04%); "2"—N = 76 (64.96%).

4 | RESULTS

Three types of zygomatic implants were used. Total 117 implants. Zygomatic implants (a), with a fully sandblasted and acid-etched surface, accounted for 47% (n = 55). The group (B) of implants were smooth with rough threaded apex—32% (n = 38).

Hybrid implants (C), with rough threaded apex and machined (nonthreaded) body and crestal threads accounted for 21% (n = 24).

General anesthesia was done to patients who received an intra-sinus implant—35.04%. All extra-sinus procedures were performed under local anesthesia—64.96% (Table 1).

The crestal position of the prosthetic abutments was achieved in 71.79% (Table 2).

The implants used in the study were from 30 to 50 mm long. The most commonly implanted zygomatic implants were 45 mm—32.48% (Table 3).

During follow-up visits, periodontal examination with a calibrated plastic tube, periimplantitis was found in around 3% of classic zygomatic implants (Table 4) and maxillary sinusitis was below 6% (Table 5). The immediate loading was applied in 22 patients. Zygomatic implants in remaining 27 patients were loaded within 3–6 months after surgery.

In the study group, about six implants (11%) Brånemark System and six Noris implants (16%) were exposed. There was no mucosal recession around the prosthetic abutments of hybrid implants.

TABLE 2 Position of the implant head/prosthetic abutment: on the crest or palatally

Placement of the implant (1—top of the crest; 2—slightly palatal)	A (Group: zygomatic implants)		B (Group: Noris implants)		C (Group: hybrid implants)	
	N	%	N	%	N	%
1	23	41.82	37	97.37	24	100.00
2	32	58.18	1	2.63	0	0.00

Note: "1"—N = 84 (71.79%); "2"—N = 33 (28.21%).

TABLE 3 Implant lengths

Length of zygomatic implant	A (Group: Zygomatic implants)		B (Group: Noris implants)		C (Group: Hybrid implants)	
	N	%	N	%	N	%
30	15	27.27	0	0.00	0	0.00
35	6	10.91	2	5.26	0	0.00
40	7	12.73	14	36.84	10	41.68
45	18	32.73	14	36.84	6	25.00
47.5	6	10.91	5	13.17	4	16.66
50	3	5.45	3	7.89	4	16.66

TABLE 4 Periimplantitis in zygomatic implants

Percentage of periimplantitis around zygoma	A (Group: zygomatic implants)		B (Group: Noris implants)		C (Group: hybrid implants)	
	N	%	N	%	N	%
0	52	94.55	38	100.00	24	100.00
1	3	5.45	0	0.00	0	0.00

Note: "0"—N = 114 (97.44%); "1"—N = 3 (2.56%).

TABLE 5 Post-op sinusitis

Percentage of sinusitis on zygomatic implants (0—no sinusitis; 1—sinusitis)	A (Group: zygomatic implants)		B (Group: Noris implants)		C (Group: hybrid implants)	
	N	%	N	%	N	%
0	51	92.73	36	94.74	23	95.83
1	4	7.27	2	5.26	1	4.17

Note: "0"—N = 110 (94.02%); "1"—N = 7 (5.98%).

5 | DISCUSSION

The original Brånemark technique of placing zygomatic implants in patients with severely resorbed maxilla opened new opportunities for predictable and even immediate rehabilitation of such patients without grafting the sinus. With time, however, intra-sinus placement of completely threaded and rough implants, palatal location of implant heads and general anesthesia were the limiting factors, for making zygoma treatment more common, due to the risk of post-op sinusitis, implant failures, prosthetic challenges.

Therefore, extra-sinus placement of hybrid (rough/machined) surfaced implants with crestal threads and internal platform switch connection lowers the risk of sinusitis and implant failure. Furthermore, subcrestal placement and platform-switched abutments on the crest—make prosthetics more comfortable for the patient and predictable as with conventional dental implants.²²

The novel implant design reduces gingival recession around prosthetic abutments due to platform-switch applied.^{23,24}

Furthermore the results of our study indicate efficacy of immediate loading of extra-sinus zygomatic implants which is the major benefit for the patient and treating team.²⁵ Prosthetic loading 3–6 months after surgery is also very popular among authors doing similar research. The overall failure rate of zygomatic implants in our study does not differ from the reported by other authors and amounts to 1.7%.²⁶

According to our knowledge, no report on zygoma platform switch hybrid implants placed extra-sinus has been published yet and therefore our findings may be encouraging for other investigators to further examine and popularize this graft-less method of full and frequently immediate rehabilitation of highly compromised patients.

6 | CONCLUSION

Extra-sinus zygomatic implant placement lowers the risk of post-op sinusitis and makes procedure possible to be done in local anesthesia. The use of hybrid implants lowers the risk of periimplantitis, sinusitis and implant failure. Crestal threads and internal platform-switch connection enable subcrestal placement and on-crest emerging of prosthetic abutment hence making prosthetics as good as on conventional dental implants. Soft tissue augmentation with fat-pads can be made in patients with a thin soft tissue biotype to avoid gingival recession. The overall failure rate of zygomatic implants in our study does not differ from the reported by other authors and amounts to 1.7%.²⁶

The use of zygomatic implants is often a rescue procedure after complications in patients who have previously received conventional implant treatment.

CONFLICT OF INTEREST

The authors declare no conflicts of interest.

ORCID

Paweł Aleksandrowicz  <https://orcid.org/0000-0003-2380-6800>

REFERENCES

1. Xu X, Zhao S, Liu H, Sun Z, Wang J, Zhang W. An anatomical study of maxillary-zygomatic complex using three-dimensional computerized tomography-based zygomatic implantation. *Biomed Res Int*. 2017; 2017:8027307 <https://doi.org/10.1155/2017/8027307>.
2. Rossi M, Duarte LR, Mendonça R, Fernandes A. Anatomical bases for the insertion of zygomatic implants. *Clin Implant Dent Relat Res*. 2008; 10(4):271–275.
3. Brånemark P-I, Gröndahl K, Öhrnell L-O, et al. Zygoma fixture in the management of advanced atrophy of the maxilla: technique and long-term results. *Scand J Plast Reconstr Surg Hand Surg*. 2004;38:70–85.
4. Breeze J, Patel J, Dover MS, Williams RW. Success rates and complications of autologous onlay bone grafts and sinus lifts in patients with congenital hypodontia and after trauma. *Br J Oral Maxillofac Surg*. 2017;55(8):830–833.
5. Zinser MJ, Randelzhofer P, Kuiper L, Zöller JE, De Lange GL. The predictors of implant failure after maxillary sinus floor augmentation and reconstruction: a retrospective study of 1045 consecutive implants. *Oral Surg Oral Med Oral Pathol Oral Radiol*. 2013;115(5):571–582.
6. Dreiseidler T, Kaunisaho V, Neugebauer J, Zöller JE, Rothamel D, Kreppel M. Changes in volume during the four months' remodelling period of iliac crest grafts in reconstruction of the alveolar ridge. *Br J Oral Maxillofac Surg*. 2016;54(7):751–756.
7. Jager DHJ, Maarse F, Klausch T, et al. Wound dehiscences following pre-implant bone augmentation with autogenous iliac crest bone grafts: a retrospective cohort study. *Int J Oral Implantol (New Malden)*. 2019;12(2):227–236.
8. Kang YH, Kim HM, Byun JH, et al. Stability of simultaneously placed dental implants with autologous bone grafts harvested from the iliac crest or intraoral jaw bone. *BMC Oral Health*. 2015;15:172.
9. Cosci F, Luccioli M. A new sinus lift technique in conjunction with placement of 265 implants: a 6-year retrospective study. *Implant Dent*. 2000;9(4):363–368.
10. Wagner F, Dvorak G, Nemec S, Pietschmann P, Figl M, Seemann R. A principal components analysis: how pneumatization and edentulism contribute to maxillary atrophy. *Oral Dis*. 2017;23(1):55–61.
11. Atalay B, Doğanay Ö, Saraçoğlu BK, Bultan Ö, Hafiz G. Clinical evaluation of zygomatic implant-supported fixed and removable prosthesis. *J Craniofac Surg*. 2017;28(1):185–189.
12. Lombardo G, D'Agostino A, Trevisiol L, et al. Clinical, microbiologic and radiologic assessment of soft and hard tissues surrounding zygomatic implants: a retrospective study. *Oral Surg Oral Med Oral Pathol Oral Radiol*. 2016;122(5):537–546.
13. Dos Santos PL, Silva GH, Da Silva Pereira FR, et al. Zygomatic implant subjected to immediate loading for atrophic maxilla rehabilitation. *J Craniofac Surg*. 2016;27(8):734–737.
14. Aleksandrowicz P, Kusa-Podkańska M, Grabowska K, Kotuła L, Szkatuła-Łupina A, Wysokińska-Miszczyk J. Extra-sinus zygomatic implants to avoid chronic sinusitis and prosthetic arch malposition: 12 years of experience. *J Oral Implantol*. 2019;45(1):73–78.
15. Bedrossian E, Stumpel L, Beckely M, Indersano T. The zygomatic implant: preliminary data on treatment of severely resorbed maxillae. A clinical report. *Int J Oral Maxillofac Implants*. 2002;17: 861–865.
16. Kato Y, Kizu Y, Tonogi M, Ide Y, Yamane G-y. Internal structure of zygomatic bone related to zygomatic fixture. *J Oral Maxillofac Surg*. 2005;63:1325–1329.
17. Petruson B. Sinuscopy in patients with titanium implants in the nose and sinuses. *Scand J Plast Reconstr Surg Hand Surg*. 2004;38: 86–93.
18. Bothur S, Jonsson G, Sandahl L. Modified technique using multiple zygomatic implants in reconstruction of the atrophic maxilla: a technical note. *Int J Oral Maxillofac Implants*. 2003;18:902–904.
19. Aleksandrowicz P, Wysokińska – Miszczyk J. Zygoma implants as a method of implantology treatment of difficult cases with considerable

- bone loss—Description in cases implantoprotetyka. *Eur J Oral Implantol*. 2007;7:26–27.
20. Maló P, Nobre Mde A, Lopes I. A new approach to rehabilitate the severely atrophic maxilla using extramaxillary anchored implants in immediate function: a pilot study. *J Prosthet Dent*. 2008;100(5):354–366.
21. Davó R, Malevez C, López-Orellana C, Pastor-Beviá F, Rojas J. Sinus reactions to immediately loaded zygoma implants: a clinical and radiological study. *Eur J Oral Implantol*. 2008;1:53–60.
22. Aparicio C, Ouazzani W, Aparicio A. Extrasinus zygomatic implants: three year experience from a new surgical approach for patients with pronounced buccal concavities in the edentulous maxilla. *Clin Implant Dent Relat Res*. 2010;12(1):55–61.
23. Sculean A, Chappuis V, Cosgarea R. Coverage of mucosal recessions at dental implants. *Periodontol 2000* 2000 2017; 73(1):134–140.
24. Mazzotti C, Stefanini M, Felice P, Bentivogli V, Mounssif I, Zucchelli G. Soft-tissue dehiscence coverage at peri-implant sites. *Periodontol 2000*. 2018;77(1):256–272.
25. Coppedê A, de Mayo T, de Sá Zamperlini M, Amorin R, de Pádua APAT, Shibli JA. Three-year clinical prospective follow-up of extrasinus zygomatic implants for the rehabilitation of the atrophic maxilla. *Clin Implant Dent Relat Res*. 2017;19(5):926–934.
26. Aparicio C, Manresa C, Francisco K, et al. Zygomatic implants: indications, techniques and outcomes, and the zygomatic success code. *Periodontol*. 2014;66(1):41–58.

How to cite this article: Aleksandrowicz P, Kusa-Podkańska M, Tomkiewicz W, Kotuła L, Perek J, Wysokińska-Miszczyk J. Platform switch hybrid zygoma implants improve prosthetics and marginal bone protection after extra-sinus placement. *Clin Implant Dent Relat Res*. 2020;22:186–192. <https://doi.org/10.1111/cid.12878>



Clinical outcome of 302 zygomatic implants in 110 patients with a follow-up between 6 months and 7 years

Funda Goker D.D.S., MSc., PhD.¹ | Emma Grecchi D.D.S., MSc¹ |
Massimo Del Fabbro MSc., PhD^{1,2} | Francesco Grecchi M.D.²

¹Department of Biomedical, Surgical and Dental Sciences, University of Milano, Milan, Italy

²IRCCS Orthopedic Institute Galeazzi, Milan, Italy

Correspondence

Massimo Del Fabbro, Department of Biomedical, Surgical and Dental Sciences, University of Milano, Milan, Italy.
Email: massimo.delfabbro@unimi.it

Abstract

Background: Zygomatic implant surgery is considered as a safe and successful alternative to the conventional implant surgery with bone grafts for patients with severe atrophic maxilla.

Purpose: The aim of this retrospective clinical case series was to report clinical outcome of zygomatic implants with a follow-up between 6 months and 7 years.

Materials and methods: A total of 110 patients with 302 zygomatic implants were included in this study. The intra and postoperative complications and survival rate of zygomatic implants were evaluated.

Results: The study included 110 consecutively treated patients with an age range of 21 to 76 years (mean 57.35 years, SD 10.42). The overall zygomatic implant survival rate was 98.34%. There were five implant failures in four patients. One intraoperative and 17 postoperative complications developed in 18 patients. There were no drop-outs and the median follow-up of the patients was 41.75 months (with a range of 6-89 months).

Conclusions: According to the results, in cases of severely atrophic posterior maxilla, zygomatic implant surgery can be considered as an effective and safe alternative to conventional implants and bone grafting procedures.

KEYWORDS

dental implants, maxillary atrophy, oral rehabilitation, retrospective study, Zygomatic implants

1 | INTRODUCTION

Zygomatic implant (ZI) surgery was reported by Brånemark, in the 1990s, as an alternative to conventional methods for patients with a severely resorbed maxilla. Since its introduction, this method has been shown to be a promising alternative with high success rates and reduced healing time.^{1,2} ZI is considered as an attractive option since it offers advantages such as reduced costs and low morbidity when compared to conventional bone augmentation procedures.³⁻⁵

ZIs can be inserted as bilateral two implants (quad), bilateral one implant per maxillary process, or unilateral 1 or 2 implants. They can also be utilized in combination with conventional implants.³ Initially, the success of ZI surgery with high primary stability was considered as a

consequence of engagement of the fixations through four cortices: the cortical floor of the maxillary sinus, the palatal cortex of the maxillary alveolar bone at the crest and two zygomatic bone cortices at the apex of the ZIs.⁶ Even in cases with an absence of cortical bone to engage the implant at the crestal level, it was reported that ZIs can be successful with good primary implant stability by engaging zygomatic bone cortices.⁷ However, alveolar bone support is considered beneficial by some authors, Freedman et al in 2015⁸ in a finite element analyses study reported that alveolar bone support for ZIs placed in an extra-sinus position can reduce the internal stresses generated by occlusal and lateral forces when compared to implants not supported by alveolar bone.⁸

The insertion of ZIs is a major and difficult surgery associated with some risks due to proximity of the critical anatomical structures

such as the infraorbital nerve, orbit, and the infratemporal fossa.⁶ In addition to the complex surgery, the region represents reduced visibility and instrument control during site preparation and the placement of relatively long (30–52.5 mm) implants.³ Traditionally, the ZI surgery is performed under general anesthetic or intravenous sedation.³

The postoperative complications are infrequent³ and the success rates of the ZI are high.^{9–12} However, even rare, ZI surgery can be associated with serious intra/postoperative complications and it is advisable that this kind of surgery should be performed by a highly experienced surgeon. Intraoperative complications of the technique include fracture of the zygomatic bone and perforation of the orbital cavity. Postoperative complications include sinusitis, mucositis, temporary or permanent neurosensory deficits, peri-orbital abscesses, peri-implantitis, oroantral communications and failure of the implant.

The aim of this single center retrospective consecutive case series study was to evaluate the clinical outcome of 302 ZIs in 110 patients with a follow-up between 6 months and 7 years.

2 | MATERIALS AND METHODS

The present article was written following the STROBE (Strengthening the Reporting of Observational Studies in Epidemiology) guidelines (<http://www.strobe-statement.org>).

This retrospective study was performed at the Department of Dentistry and Maxillofacial Surgery, University of Milan, (section of Galeazzi Hospital, Italy) between September 2012 and February 2020. This study protocol was approved by institutional scientific review board of Galeazzi Hospital (Milan, Italy; authorization no. 2552377-L2058. ("Implant rehabilitation of the partially or totally edentulous patient: evaluation of techniques and materials to improve predictability and maintenance"). All the patients signed an informed consent agreement form and the study protocol was in compliance with the principles laid down in the Declaration of Helsinki on medical protocol. The study population composed of 110 patients with 302 ZIs who had at least one ZI placed between September 2012 and August 2019. The patients were identified from the medical records as having consented to total edentulous maxillary rehabilitation with the use of implants inserted into the zygomatic bone.

Inclusion criterion was set as patients with severely atrophic edentulous maxilla with extreme horizontal and vertical bone loss and pneumatization of the maxillary sinuses¹³ (Class IV–V Cawood and Howell), who were in need of oral rehabilitation. Exclusion criteria were patients with active infection in oral maxillofacial region, emotionally instable patients, and patients with active radiotherapy or chemotherapy. The patients were rehabilitated either by only ZIs or by using ZIs in conjunction with conventional dental implants. The presurgical and surgical approach, the prosthetic procedure and the follow-up protocol were described in detail in a previous article by the same team.¹⁴ The representative preoperative and postoperative orthopantomographic images of one of the patients can be seen in Figures 1 and 2.

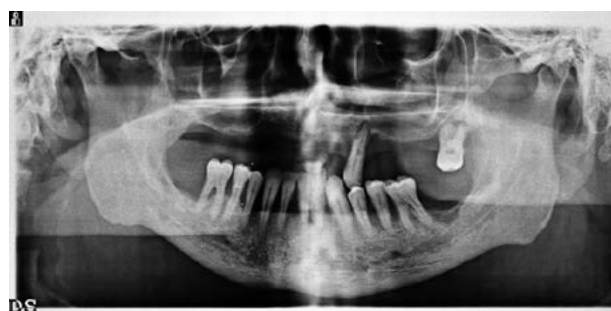

FIGURE 1 The representative preoperative panoramic radiographic image of the patient

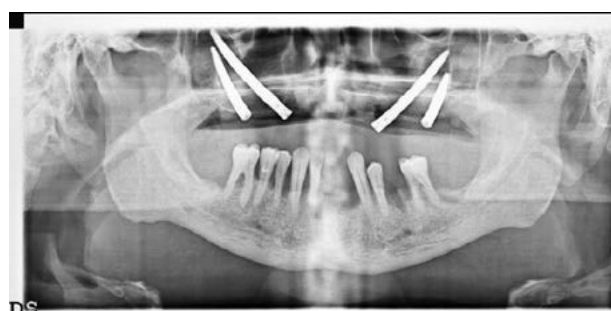


FIGURE 2 The representative postoperative panoramic radiographic image of the patient showing quad zygomatic implants inserted

2.1 | Presurgical protocol

Preoperative clinical examinations of the patients included preoperative cone beam computed tomography (CBCT) scans and orthopantomographs for the form and dimensions of the maxillary and zygomatic bone and for the maxillary sinus pathologies. General health status of the patients was evaluated by a blood test, electrocardiography, and chest radiography.

A week before surgery, a professional oral hygiene session was given to each patient and oral rinses with chlorhexidine digluconate 0.2% mouthwash. The patients were prescribed with pre- and postoperative antibiotics: Augmentin (amoxicillin and clavulanate potassium) at a dosage of 1-g tablet every 8 hours for a total of 6 days, starting from the evening before the surgery. In cases, when an allergy to penicillin was declared, Azithromycin 500 mg for 3 days was prescribed as an alternative.

2.2 | Surgical protocol

All surgeries were carried out by the same surgeon (Fr.G.) under local anesthesia (4% articaine with 1:100000 adrenalin) and general anesthetic or under sedation with blood pressure, pulse, and oximetric monitored by the anesthetist. All the ZIs were inserted with

"extrasinus technique." The ZIs used in this study were either partially threaded (unthreaded crestal long body with 12.5 mm apical threaded part) (Noris Medical Ltd., Israel) or totally threaded (ICX Zygoma implants, Medentis medical GmbH, Ahrweiler, Germany).

In brief; the operation started with a palatal incision in the maxillary crest with vertical posterior releasing incisions and the muco-periosteal flap reflections. After flap reflection, all the bone surgeries and the implant site preparations were performed using drills and burs according to the instructions from the manufacture firms. Finally, the ZIs were carefully inserted at a low speed (20-40 rpm), with a torque of 40 to 80 Ncm, and the final stabilization was performed manually with an extraoral screwdriver, or with the standard protocol of screwing that are used with conventional implants. The anterior implants that emerged from canine region, were always inserted before the posterior ones. The surgical sites were covered with resorbable equine collagen membrane (15 sites) (Condress, Smith&Nephew, Agrate Brianza, Italy) or with Bichat fat pad (45 sites) in cases of vestibular maxillary concavity. The wounds were repositioned and sutured using continuous resorbable sutures (Vicryl, Ethicon FS-2, Johnson & Johnson, New Brunswick, New Jersey). The representative intraoperative and intraoral view of a patient with quad partially threaded ZIs inserted can be seen in Figure 3.

2.3 | Prosthetic procedure and follow-up protocol

All the implants typically emerged the canine or the first molar region on the residual crest of the ridge and primary stability was achieved in all implants with minimum insertion torque of 40 Ncm. Ninety-one of the patients received immediate loading of the prosthesis while 19 of the prosthesis were done in a delayed approach. The decision for loading protocol based on the request of the each patient mostly due to economic reasons, independent of the primary stability of the ZI. The type of the prosthesis to be delivered was determined according to the anatomic and financial conditions of each patient, taking antagonist dentition in consideration as well. A total of 89 Toronto implant bridges in acrylic resin, one Toronto implant bridge in ceramic, three acrylic resin bridges, 10 ceramic bridges, five total fixed resin prostheses, and two removable prosthesis with bar were delivered.

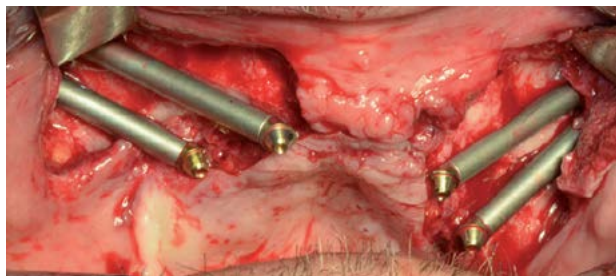


FIGURE 3 The representative intraoperative and intraoral view of the patient with partially threaded quad zygomatic implants inserted

The patients were recalled for clinical follow-up after 10 days, 1 month, and every 3 months for the first year, and then twice a year. The occlusion was examined carefully at the delivery of the final prostheses and at each follow-up. In the first year following ZI insertions, follow up criteria for the patients with toronto prosthesis included additional interventions. Every 6 months, Toronto prosthesis were unscrewed to check the status of the surrounding tissues.

2.4 | ZI outcome evaluation

Implant survival rates were evaluated based on the clinical and radiologic criteria as a primary outcome. Complications were evaluated as additional criteria.

Implant survival rates were evaluated based on the clinical criteria described by Albrektsson and his colleagues¹⁵ as listed below:

- absence of clinically detectable implant mobility;
- no evidence of peri-implant radiolucency;
- no spontaneous ZI failure;
- radiographic vertical bone loss less than 0.2 mm per annum;
- absence of pain and infections.

2.5 | Statistical analysis

Statistical analysis was performed using GraphPad Prism 5.03 (GraphPad Software, Inc., La Jolla, California). Descriptive statistics of the data was done using mean values and standard deviation (SD) for quantitative variables normally distributed. Normality of distributions was evaluated through the d'Agostino and Pearson omnibus test. The effect of each variables (gender, age, smoking habits, reason for ZI, type of antagonist dentition, number of ZIs per prosthesis, loading modality, ZI location, prosthesis type, implant design) on complications was evaluated by using the Fisher's exact test, given the low incidence of complications in each subgroup. When there were more than two categories for a given variable, the generalized Fisher exact test was used. Since the latter was not provided by GraphPad Prism 5.03, the test was performed using the online free package SISA (Simple Interactive Statistical Analysis, <http://www.quantitativeskills.com/sisa/>). The patient was considered as the unit of analysis. $P = .05$ was considered as the significance threshold.

3 | RESULTS

The study group of the present study included 110 consecutively treated patients (60 women and 50 men), with a total of 302 ZIs. The study population composed of patients aged from 21 to 76 (mean 57.35 years, SD 10.42) who had at least one ZI placed between September 2012 and February 2020. Final or provisional prosthesis were delivered on the same day of surgery. The median follow-up of the patients was 41.75 months (with a range of 6-89 months).

Thirty-two patients presented some systemic conditions which can be listed as follows: two gastritis, four depression, one sjogren syndrome, one pulmonary embolism, one osteoporosis, three rheumatoid arthritis, four hypothyroid, three hypertension, four hepatitis C virus (HCV), one hepatitis B virus (HBV), one cardiac stent, one

transcatheter aortic valve placement, one hyperuricemia, eight ectodermal dysplasia, two hypercholesterolemia, one anemia, one anorexia, one thrombocytopenia, one buccal palatal cleft operated, one benign prostatic hyperplasia, and one aspirin user for cardiologic purpose. There were 10 patients presenting more than one condition. There were no oncologic conditions in any of the patients. The systemic conditions of all patients were under control, so they were not accepted as major obstacles to perform surgical operations. As recorded from the history of the patients, two ex-periodontitis patient and three ex-smokers were present in the population. Nine patients were active smokers (one heavy smoker), and two patients declared allergy to penicillin. There were two bruxist patients and one of these patients lost an implant due to this condition.

In this present study, there were no drop outs and the implant survival rate was 98.34%. Five implants were lost in four patients (two in the first week, one in 3 months, and the other two after 1 year due to heavy bruxism and occlusal overload. Detailed data and results concerning gender, reason for ZI, age and smoking are listed in Table 1. Implant survival rates for comparison of antagonist dentition, ZI design, number and location are listed in Table 2. Data and results for comparison of loading and prosthesis type are listed in Table 3. Patient based survival rates comparison are listed in Table 4.

TABLE 1 Implant success rates for comparison of gender, reason for ZI, age, and smoking status

Patient	Characteristics	Failed implants/ total no of implants	Success %
Gender	Male	1/144	99.3
	Female	4/158	97.4
Reason for ZI	Severe atrophic maxilla	1/201	99.4
	Previous implant failure	4/101	96.0
Smoking habits	Smoking	1/11	90.9
	No smoking	4/291	98.6
Age	<60 years	4/59	93.2
	>60 years	0/243	100

TABLE 2 Implant success rates for comparison of antagonist dentition, ZI design, number, and location

Patient	Characteristics	Failed implants/total no of implants	Success %
Antagonist dentition	Total Removable prosthesis with bar	0/4	100
	Fixed/ natural teeth	5/280	98.2
	Partial removable prosthesis	0/8	100
	Total Removable prosthesis	0/10	100
ZI location	13 or 23 (canine)	1/94	98.9
	16 or 26 (first molar)	4/208	98.0
Total threaded design		0/41	100
Partial threaded design		5/261	98.0
Number of ZI + I	1ZI + 1I	1/9	88.8
	1ZI + 4I	0/1	100
	Total result for 1ZI	1/10	90.0
	2ZI + 2I	0/18	100
	2ZI + 3I	0/20	100
	2ZI + 4I	1/64	98.4
	Total result for 2 ZI	1/104	99.0
	3ZI	2/3	33.3
	3ZI + 1I	0/3	100
	3ZI + 2I	0/6	100
	Total result for 3 ZI	2/12	83.3
	4ZI	1/96	98.9
	4ZI + 1I	0/64	100
	4ZI + 2I	0/8	100
	4 ZI + 2P	0/8	100
	Total result for 4 ZI	1/176	99.4

TABLE 3 Implant success rates for comparison of loading and prosthesis type

Patient	Characteristics	Failed implants/ total no of implants	Success %
Loading	Immediate	5/254	98.0
	Delayed	0/48	100
Type of prosthesis	Removable prosthesis with bar	0/5	100
	Toronto	3/266	98.8
	Ceramic Toronto	0/4	100
	Total fixed resin	1/9	88.8
	Ceramic Bridge	1/15	93.3
	Resin bridge	0/3	100

According to the results, the implant survival was not influenced by gender, smoking, ZI location, and ZI design. No specific loading protocol, either immediate or delayed was beneficial in terms of implant survival.

There was no significant effect of using bilateral ZI insertion (2ZI or 4ZI) vs unilateral ZIs (3ZI and 1ZI) on implant survival (Table 4).

Patients with previous failure of conventional implants had greater probability of ZI failure respect to patients with atrophic maxilla receiving implant treatment for the first time, though it was not statistically significant. Age over 60 was found to be favorable in terms of implant survival.

In some of the groups, statistical calculations were not applicable (NA), due to great difference among sample size and number of events with no events in some cases (Table 4).

The details for timing and treatment modality for complications seen in 18 patients including 4 patients with 5 implant failures are listed in Table 5.

4 | DISCUSSION

In cases of extremely atrophic maxillary bone, zygomatic surgery approach is considered by several authors as less invasive and more predictable than conventional implant surgery with grafting procedures.⁴ Various studies have reported that the use of ZIs decreases the number of surgical steps, the length of treatment, and the costs, mainly due to the fact that, the insertion of ZIs does not require additional grafting.^{4,16-20}

The ZIs may be inserted in the zygomatic bone, alone or in combination with conventional implants.^{1,16,21} Indications, comparison of surgical protocols, prosthetic rehabilitation protocols, complications and survival rates for ZIs were evaluated in many clinical and review articles.^{3-5,7,10,11,22-24} According to the literature, the major complications associated with ZIs were reported as loss of integration, oral-antral communication, sinusitis, paresthesia, mucositis, periimplantitis, penetration of the orbital cavity during the drilling protocol, cutaneous fistula and failure of the implants.^{10,22}

According to a review by Candel-Marti 2012, maxillary sinusitis is the most frequent complication in ZI surgery.²¹ However, according to a retrospective cohort study by D'Agostino et al,²⁵ placement of ZIs is not associated with severe rhinosinusitis complications. Additionally, various authors have reported that extra-maxillary/extramaxillary approach in ZI insertion does not cause significant sinusitis, since most part of the implant is placed outside the maxillary sinus.^{2,11,26,27} In the present study, extra-maxillary approach was utilized without any sinusitis cases and this result is in accordance with the statement above.

The biological and prosthetic complications associated with ZIs include, infection following fistula, sinusitis, fracture of the abutment screw and fracture of the prosthesis.^{10,28} According to various reports, biological complications are rare and usually resolve in time. In the present study, one of the patients had inflammation of the soft tissues with a cutaneous fistula, the problem was resolved without major problems. The cutaneous fistula was treated by two stage surgical approach. Fistulotomy and simultaneous lipofilling were performed at the first stage. After 6 months, the patient was recalled and due to some aesthetic concerns an additional lipofilling was performed with success.

Nobre et al. evaluated clinical soft tissue parameters for extramaxillary ZIs and the results failed to identify compelling evidence to conclude that any particular implant or feature affects the outcome of the treatment of patients with fully edentulous maxilla.²⁹ In this study, three periimplant mucositis and two periimplantitis were seen in five patients. The three cases of peri-implant mucositis were diagnosed after 2 to 3 months and treatment modality included Diode laser applications (Doctor Smile Dental laser, Lambda S.p.A., Brendola, Italy). All of the mucositis conditions were resolved without any further complications. In two periimplantitis cases, two implants were removed by the surgeon, at the follow up visit due to mobility and their prosthesis was adjusted with replanning. The three cases of peri-implant mucositis were seen in totally threaded design, however when survival rates of the two designs were compared, there was no statistically significant difference between them for periimplantitis or mucositis.

The success of prostheses and bone-implant stress distribution can be influenced by implant length, number, position, inclination, and prosthetic protocol which includes; material properties, loading modality, prosthesis splinting protocols, and cantilever forces.³⁰ ZI are similar to angled implant applications in which, implant length, cortical anchorage and implant distribution within the arch are important factors on failures and success.³⁰ The ZI has an increased tendency to bend under horizontal loads,³¹ since ZIs are longer in length than conventional dental implants and there is limited bone support in the maxillary alveolar crest. Due to these reasons, additional attention should be given to the balanced load distribution by the prosthetic over-structure throughout the maxillary arch. Specially, in cases of heavy bruxism patients, the situation can be quite challenging. Several authors observed higher stress values in the molar region compared to more anterior regions and the increase in stress in implants is proportional to the increase in cantilever lengths.^{32,33} In the present

TABLE 4 : Patient based success rates comparison

Patient	Characteristics	Failed patients/total no of patients	Success %	P-value
Gender	Male	1/50	98.0	.30
	Female	3/60	95.0	
Reason for ZI	Severe atrophic maxilla	1/77	98.7	.016
	Previous implant failure	3/33	90.9	
Smoking habits	Smoking	1/ 6	83.3	.40
	No smoking	3/104	97.1	
Age	>60 years	0/49	100	.18
	<60 years	4/61	93.4	
Antagonist dentition	Removable prosthesis	0/10	100	NA
	Fixed prosthesis on implant and/or natural teeth)	4/95	95.7	
	Toronto resin	0/5	100	
Implant design	Total threaded	0/18	100	.97
	Partial threaded	4/92	95.6	
Number of ZI + I ^a	1ZI	0/1	100	.07
	1ZI + 1I	0/1	100	
	1ZI + 4I	1/9	88.8	
	Total result for 1ZI	1/11	90.9	
	2Z	0/4	100	
	2ZI + 2I	0/18	100	
	2ZI + 3I	0/9	100	
	2ZI + 4I	1/30	96.6	
	Total result for 2 ZI	1/52	98.0	
	3ZI	1/1	0	
	3ZI + 1I	0/1	100	
	3ZI + 2I	0/1	100	
	Total result for 3 ZI	1/3	66.6	
	4ZI	1/24	95.8	
	4ZI + 1I	0/16	100	
	4ZI + 2I	0/2	100	
	4 ZI + 2P	0/2	100	
	Total result for 4 ZI	1/44	97.7	
Loading	Immediate	4/92	95.6	.96
	Delayed	0/18	100	
Type of prosthesis	Removable prosthesis with bar	0/2	100	NA
	Toronto resin	2/89	97.7	
	Ceramic Toronto	0/1	100	
	Total fixed Resin	1/5	80.0	
	Ceramic Bridge	1/10	90.0	
	Resin bridge	0/3	100	

Abbreviation: NA, not applicable.

^aGeneralized Fisher exact test was used.

study, five implants were lost due to occlusal overload either because of heavy bruxism or occlusal overload by inappropriate unbalanced prosthetic over structure. Furthermore, when conducting the analysis using the patient as unit (Table 4), insertion of unilateral ZIs (3ZI and 1ZI) showed a slightly higher incidence of failure (2 patients with

failure out of 14 patients, 14.3%) as compared to bilateral ZI insertion (2 patients with failure out of 96 patients, 2.1%). This might suggest that the latter solution could be beneficial, though the results did not achieve statistical significance ($P = .07$). It could be hypothesized that an even number of implants would mean a better load distribution

TABLE 5 Complications and treatment modalities

Complication	Timing of complication	Treatment
One fracture of the zygomatic bone	Intraoperative	Repositioning of the zygomatic bone with fixation plate
Three mucositis	2-3 months	Laser treatment
Two temporary paresthesia	Early postsurgical complication	B12 vitamin supplement and resolution by time in 6 months
One permanent paresthesia	Postoperative	Under control
One zygomatic bone periostitis at the apex of ZI in first molar region	7-10 days	Reason was apical over-instrumentation of the implant site and the apex of the ZI was cut off under general anesthesia
One inflammation with cutaneous fistula	8 months	Fistulectomy and lipofilling
Two simultaneous failure of implant due to bruxism and overloading by the prosthetic over structure	3 months	Prosthetic replanning
Three oroantral sinus communications	7-10 days	Additional surgery with bichat flap
Two failure of implants due to periimplantitis	Removed by the surgeon after 2 weeks visit due to mobility	Prosthetic replanning
One of the implants was lost simultaneously due to overloading by the prosthetic over structure	20 months	Prosthetic replanning

and could be more favorable in terms of biomechanics. Hence, an uneven number could place the patient in greater biomechanical risk. A larger sample size is required to explore this hypothesis.

The Immediate loading modality of ZIs is reported as a predictable treatment option for the atrophic maxilla.²⁴ In this study, all the failures were observed in immediate loaded ZIs. However, there was no statistically difference among immediate or delayed loading protocols.

ZIs placed with a combination of 2 to 4 conventional implants inserted in premaxilla are accepted to be the most preferred protocol to reduce the load and create an even stress distribution around the implants by splinting.³⁴ The emergence of the ZIs are often 10 to 15 mm medial to the ridge, the prosthetic over structure should be designed to enable proper oral hygiene in the area. The head of the implant with adequate abutment type in length and angulation is also a crucial factor for positioning the screw emergence on the occlusal surfaces and for determining the final thickness of the prosthesis.³¹ In the present study, there was no statistically significant difference for ZI failures among groups concerning ZI location, ZI design, and loading protocol. However, the authors of this present work highly recommend giving special importance to the prosthetic phase, in order to prevent failures.

According to a clinical report by Pu et al,³⁵ the age-related linear and angular changes in the ZI insertion areas are factors that should be considered with regard to the safety of the four-implant protocol.³⁵ In this study, population group consisted of 110 patients aged from 21 to 76 (media 57.19—SD 10.63). Five implants were lost in four patients, which were under 60 years old. According to the results of this study, older age was found to be particularly favorable in terms of implant survival, according to the opinion of the authors, this result might be due to the fact that patients over 60 paid more attention to oral hygiene procedures.

Additionally, there were 11 smokers in the group with one ZI failure and one oroantral communication as complication. According to various authors relative contraindications include smoking more than 10 cigarettes a day.^{25,36} In this study, smoking did not have any significant effect on the failures and complications, however smoking should always be considered as a critical risk factor.

Since its first introduction by Brånemark for the oral rehabilitation of patients with serious and extended defects of the jaws caused by postoncological resections, trauma or congenital malformations, ZI have presented high success rates and are considered as a safe approach.^{7,9,11,12,22,37} The result of this study is in accordance with this statement showing high implant survival rate (98.38%) and low incidence of complications. However, ZI insertion is a major difficult surgery and is not risk-free due to reduced visibility and instrument control. Additionally, there are critical surrounding anatomical structures such as the infraorbital nerve, orbit, and the infratemporal fossa. Several complications related to ZIs were described in literature such as fracture of the zygomatic bone, paresthesia of the infraorbital or zygomatic and facial nerves, formation of oroantral fistula, and implant failures.^{10-12,22,25} The surgeon performing the surgery should be able the deal with the possible complications. In the present study, in one of the patients, zygomatic bone was accidentally fractured during surgery. The surgery continued with the repositioning of the zygomatic bone with fixation plate and insertion of the quad ZIs. Another patient represented a zygomatic bone periostitis at the apex of ZI in first molar region, due to apical over-instrumentation of the implant site. In this case, an additional surgery was performed for cutting off the apex of the ZI was under general anesthesia. Oroantral sinus communications and paresthesia were seen in a total of six patients, as postoperative major complications. Patients with oroantral sinus communications were treated with additional surgical operations by laterally positioned flaps. In cases

of temporary paresthesia, complete recovery was seen approximately after 6 months of ZI surgery. All the complications explained above were resolved without any major problems.

The limitations of the present study include a single center research with retrospective consequent case series. In cases when the patients failed to comply with the control appointments, each patient was contacted and the information about implant survival and complications were retrieved directly. However, the follow-up period and follow-up status for the estimation of ZI survival remained unchanged.

5 | CONCLUSION

The data from this previous study indicates that the oral rehabilitation of the severely atrophic maxilla utilizing one to four ZIs placed with an extramaxillary surgical protocol can be considered as an alternative to bone grafting, and sinus elevation procedures. In accordance with data in the literature, the results of this study show that placement of ZIs is a safe procedure with high survival rate and does not seem to be associated with severe complications. However, it should be considered that ZI insertion is a challenging procedure and prior specific training is recommended. Future studies should focus on the 10-year or more outcome of ZI implants with larger groups with different treatment protocols.

CONFLICT OF INTEREST

The authors declare no potential conflicts of interest with respect to the authorship and/or publication of this article.

ORCID

Funda Goker  <https://orcid.org/0000-0002-2354-361X>

Massimo Del Fabbro  <https://orcid.org/0000-0001-7144-0984>

REFERENCES

- Brånemark PI. *Surgery and Fixture Installation: Zygomaticus Fixture Clinical Procedures*. Göteborg, Sweden: Nobel Biocare; 1998:1.
- Maló P, de Araujo NM, Lopes I. A new approach to rehabilitate the severely atrophic maxilla using extramaxillary anchored implants in immediate function: a pilot study. *J Prosthet Dent*. 2008;100:354-366.
- Chana H, Smith G, Bansal H, Zahra D. A retrospective cohort study of the survival rate of 88 zygomatic implants placed over an 18-year period. *Int J Oral Maxillofac Implants*. 2019;34:461-470. <https://doi.org/10.11607/jomi.6790>.
- Aparicio C, Ouazzani W, García R, Arevalo X, Muela R, Fortes V. A prospective clinical study on titanium implants in the zygomatic arch for prosthetic rehabilitation of the atrophic edentulous maxilla with a follow-up of 6 months to 5 years. *Clin Implant Dent Relat Res*. 2006;8:114-122.
- Aparicio C, Manresa C, Francisco K, et al. The long-term use of zygomatic implants: a 10-year clinical and radiographic report. *Clin Implant Dent Relat Res*. 2014;16:447-459. <https://doi.org/10.1111/cid.12007>.
- Nkenke E, Hahn M, Lell M, et al. Anatomic site evaluation of the zygomatic bone for dental implant placement. *Clin Oral Implants Res*. 2003;14:72-79.
- Brånemark PI, Gröndahl K, Öhrnell LO, et al. Zygoma fixture in the management of advanced atrophy of the maxilla: technique and long-term results. *Scand J Plast Reconstr Surg Hand Surg*. 2004;38:70-85.
- Freedman MR, Stassen LFA. Effect of alveolar bone support on zygomatic implants in an extra-sinus position—a finite element analysis study. *Int J Oral Maxillofac Surg*. 2015;44:785-790. <https://doi.org/10.1016/j.ijom.2015.01>.
- Tolman DE, Desjardins RP, Jackson IT, Brånemark PI. Complex craniofacial reconstruction using an implant-supported prosthesis: case report with long-term follow-up. *Int J Oral Maxillofac Implants*. 1997;12:243-251.
- Maló P, Nobre MA, Lopes A, Ferro A, Moss S. Extramaxillary surgical technique: clinical outcome of 352 patients rehabilitated with 747 zygomatic implants with a follow-up between 6 months and 7 years. *Clin Imp Dent Rel Res*. 2015;17:153-162.
- Chrcanovic BR, Abreu MH. Survival and complications of zygomatic implants: a systematic review. *Oral Maxillofac Surg*. 2013;17:81-93. <https://doi.org/10.1007/s10006-012-0331-z>.
- Chrcanovic BR, Albrektsson T, Wennerberg A. Survival and complications of zygomatic implants: an updated systematic review. *J Oral Maxillofac Surg*. 2016;74:1949-1964. <https://doi.org/10.1016/j.joms.2016.06.166>.
- Cawood JI, Howell RA. A classification of the edentulous jaws. *Int J Oral Maxillofac Surg*. 1988;17:232-236.
- Grecchi F, Bianchi AE, Siervo S, Grecchi E, Lauritano D, Carinci F. A new surgical and technical approach in zygomatic implantology. *Oral Implantol (Rome)*. 2017;102:197-208. <https://doi.org/10.11138/orl/2017.10.2.197>.
- Albrektsson T, Zarb G, Worthington P, Eriksson AR. The long-term efficacy of currently used dental implants: a review and proposed criteria of success. *Int J Oral Maxillofac Implants*. 1986;1:11-25.
- Goiato MC, Pellizzer EP, Moreno A, et al. Implants in the zygomatic bone for maxillary prosthetic rehabilitation: a systematic review. *Int J Oral Maxillofac Surg*. 2014;43:748-757. <https://doi.org/10.1016/j.ijom.2014.01.004>.
- Malevez C, Abarca M, Durdu F, Daelemans P. Clinical outcome of 103 consecutive zygomatic implants: a 6–8 months follow-up study. *Clin Oral Implants Res*. 2004;15:18-22.
- Balshi SF, Wolfinger GJ, Balshi TJ. A retro-spective analysis of 110 zygomatic implants in a single-stage immediate loading protocol. *Int J Oral Maxillofac Implants*. 2009;24:335-341.
- Becktor JP, Isaksson S, Abrahamsson P, Sennerby L. Evaluation of 31 zygomatic implants and 74 regular dental implants used in 16 patients for prosthetic reconstruction of the atrophic maxilla with cross-arch fixed bridges. *Clin Implant Dent Relat Res*. 2005;7:159-165.
- Ahlgren F, Størksen K, Tornes K. A study of 25 zygomatic dental implants with 11 to 49 months' follow-up after loading. *Int J Oral Maxillofac Implants*. 2006;21:421-425.
- Candel-Martí E, Carrillo-García C, Penarrocha-Oltra D, Penarrocha-Diago M. Rehabilitation of atrophic posterior maxilla with zygomatic implants: review. *J Oral Implantol*. 2012;38:653-657. <https://doi.org/10.1563/AAID-JOI-D-10-00126>.
- Filho HN, Amaral WS, Curra C, dos Santos PL, Cardoso CL. Zygomatic implant: late complications in a period of 12 years of experience. *Rev Clin Periodoncia Implantol Rehabil Oral*. 2016;10:1-6. <https://doi.org/10.1016/j.piro.2016.03.007>.
- Yates JM, Brook IM, Patel RR, et al. Treatment of the edentulous atrophic maxilla using zygomatic implants: evaluation of survival rates over 5–10 years. *Int J Oral Maxillofac Surg*. 2014;43:237-242. <https://doi.org/10.1016/j.ijom.2013.08.012>.
- Miglioranza RM, Sotto-Maior BS, Mendes Senna P, Francischone CE, Del Bel Cury AA. Immediate occlusal loading of extrasinus zygomatic implants: a prospective cohort study with a follow-up period of 8 years. *Int J Oral Maxillofac Surg*. 2012;41:1072-1076.
- D'Agostino A, Trevisiol L, Favero V, Pessina M, Procacci P, Nocini PF. Are zygomatic implants associated with maxillary sinusitis? *J Oral Maxillofac Surg*. 2016;74:1562-1573. <https://doi.org/10.1016/j.joms.2016.03.014>.

26. Aparicio C, Ouazzani W, Aparicio A, et al. Extra- sinus zygomatic implants: three year experience from a new surgical approach for patients with pronounced buccal concavities in the edentulous maxilla. *Clin Implant Dent Relat Res*. 2010;12:55-61. <https://doi.org/10.1111/j.1708-8208.2008.00130.x>.
27. Chow J, Wat P, Hui E, Lee P, Li W. A new method to eliminate the risk of maxillary sinusitis with zygomatic implants. *Int J Oral Maxillofac Implants*. 2010;25:1233-1240.
28. Davò R, Pons O. Prostheses supported by four immediately loaded zygomatic implants: a 3-year prospective study. *Eur J Oral Implantol*. 2013;6:263-269.
29. Nobre MA, Maló P, Gonçalves I. Evaluation of clinical soft tissue parameters for extramaxillary zygomatic implants and conventional implants in all-on-4 hybrid rehabilitations: short-term outcome and proposal of clinical recommendations for intervention in recall appointments. *Impl Dent*. 2015;24:267-274. <https://doi.org/10.1097/ID.0000000000000253>.
30. Ishak MI, Abdul Kadir MR, Sulaiman E, Abu Kasim NH. Finite element analysis of different surgical approaches in various occlusal loading locations for zygomatic implant placement for the treatment of atrophic maxillae. *Int J Oral Maxillofac Surg*. 2012;41:1077-1089. <https://doi.org/10.1016/j.ijom.2012.04.010>.
31. Aparicio C, Manresa C, Francisco K, et al. Zygomatic implants: indications, techniques and outcomes, and the zygomatic success code. *Periodontology 2000*. 2014;66:41-58. <https://doi.org/10.1111/prd.12038>.
32. Bonnet AS, Postaire M, Lipinski P. Biomechanical study of mandible bone supporting a four-implant retained bridge: finite element analysis of the influence of bone anisotropy and foodstuff position. *Med Eng Phys*. 2009; 31:806-815. <https://doi.org/10.1016/j.medengphys.2009.03.004>.
33. Rubo JH, Capello Souza EA. Finite element analysis of stress on dental implant prosthesis. *Clin Implant Dent Relat Res*. 2010;12:105-113. <https://doi.org/10.1111/j.1708-8208.2008.00142.x>.
34. Atalay B, Doganay O, Saracoglu BK, Bultan O, Hafiz G. Clinical evaluation of zygomatic implant-supported fixed and removable prosthesis. *J Craniofac Surg*. 2017;28:185-189. <https://doi.org/10.1097/SCS.0000000000003204>.
35. Pu L-F, Tang C-B, Shi W-B, et al. Age-related changes in anatomic bases for the insertion of zygomatic implants. *Int J Oral Maxillofac Surg*. 2014;43:1367-1372.
36. Bothur S, Kullendorff B, Olsson-Sandin G. Asymptomatic chronic rhinosinusitis and osteitis in patients treated with multiple zygomatic implants: a long-term radiographic follow-up. *Int J Oral Maxillofac Implants*. 2015;30:161-168. <https://doi.org/10.11607/jomi.3581>.
37. Dos Santos PL, Silva GHS, Pereira FRS, et al. Zygomatic implant subjected to immediate loading for atrophic maxilla rehabilitation. *J Craniofac Surg*. 2016;27:734-736. <https://doi.org/10.1097/SCS.0000000000003063>.

How to cite this article: Goker F, Grecchi E, Del Fabbro M, Grecchi F. Clinical outcome of 302 zygomatic implants in 110 patients with a follow-up between 6 months and 7 years. *Clin Implant Dent Relat Res*. 2020;22:415-423. <https://doi.org/10.1111/cid.12909>

Zygomatic implant survival in 9 ectodermal dysplasia patients with 3.5- to 7-year follow-up

Funda Goker¹  | Emma Grecchi¹ | Evangelista Giovanni Mancini² | Massimo Del Fabbro^{1,2}  | Francesco Grecchi²

¹Department of Biomedical, Surgical and Dental Sciences, University of Milano, Milan, Italy

²IRCCS Orthopedic Institute Galeazzi, Milano, Italy

Correspondence

Massimo Del Fabbro, Department of Biomedical, Surgical and Dental Sciences, University of Milano, Milan, Italy.
Email: massimo.delfabbro@unimi.it

Abstract

Objective: Ectodermal dysplasia syndrome is a complex group of genetic disorders identified by the abnormal development of the ectodermal structures. The aim of this retrospective clinical case series report was to evaluate the outcomes of the ectodermal dysplasia syndrome patients that underwent zygomatic implant surgery.

Materials and Methods: A total of 9 ectodermal dysplasia syndrome patients aged between 21 and 56 years (mean age 36.8) with severely atrophic maxilla were included in this study. All the patients were treated with a total of 19 zygomatic implants. The mean follow-up of the patients was 55 months (with a range of 44–84 months). The implant survival rate was evaluated as a primary outcome. The intra- and postoperative complications were evaluated as additional criteria for success.

Results: The overall implant survival rate was 100% without any complications. Final or provisional prosthesis was delivered on the same day of surgery, which resulted in an improvement of the quality of life of the patients.

Conclusion: According to the results of this study, zygomatic surgery can be considered as a viable and safe alternative to conventional treatment modalities for oral rehabilitation of ectodermal dysplasia syndrome patients.

KEYWORDS

atrophic maxilla, bone atrophy, dental implants, ectodermal dysplasia syndrome, oral rehabilitation, zygomatic implants

1 | INTRODUCTION

Ectodermal dysplasia (ED) was first defined by Charles Darwin in 1860s (Balshi & Wolfinger, 2002). ED is a syndrome of a complex group of hereditary or congenital malformations identified by the abnormal development of the ectodermal structures (Itin & Fistarol, 2004; Lypka, Yarmand, Burstein, Tso, & Yamashita, 2008). The transmission of the ED can be either autosomal dominant or recessive. The characteristics of the condition include abnormal development of the skin, sweat glands, sebaceous glands, hair,

nails, and teeth (Itin, 2013; Itin & Fistarol, 2004; Lypka et al., 2008). Additionally, ED syndrome can affect other organs, which develop from ectoderm such as nervous system, tooth enamel, and mammary glands. In general, ED can occur in isolation or in association with other more complex clinical manifestations involving the mesodermal and endodermal structures (Carvalho et al., 2013; Itin, 2013).

Dental dystrophies of the ED contain complete anodontia, hypodontia, and oligodontia (Deshpande & Kumar, 2010a). The clinical oral manifestations of ED patients include maxillary hypoplasia, mandibular protrusion, and developmental defects of the

alveolar ridges (Bani, Tezkirecioglu, Akal, & Tuzuner, 2010; Wang et al., 2019).

Oral rehabilitation in ED patients represents a major surgical challenge (Deshpande & Kumar, 2010a). This difficulty is primarily due to anatomical problems, such as the shape and density of the edentulous jawbones and secondly due to the poor quality of the oral soft tissue with limited attached gingiva. These factors are usually considered as unfavorable for the prognostic of healing in cases of bone grafts and dental implants. Ectodermal dysplasia has a negative impact on the oral health-related quality of life of patients (Hanisch, Sielker, Jung, Kleinheinz, & Böhner, 2019). According to a systematic review by Wang et al in 2016, dental implants with or without bone augmentation are commonly used methods for oral rehabilitation of ED syndrome (Deshpande & Kumar, 2010a; Wang, He, Decker, Hu, & Zou, 2016). The insertion of conventional dental implants in patients with ectodermal dysplasia syndrome was reported in literature with high survival rates by several authors (Chrcanovic, 2018).

Zygomatic implants (ZI) were introduced by Branemark as a successful and promising alternative for oral rehabilitation of the patients with extremely atrophic maxillary bone (Branemark, 1998; Maló, de Araujo Nobre, & Lopes, 2008). The advantages of the technique include reduced number of surgeries, reduced time, decreased need for additional bone grafting, and less expenses when compared to conventional implant procedures (Aparicio, Manresa, Francisco, Claros, et al., 2014; Aparicio et al., 2006; Chana, Smith, Bansal, & Zahra, 2019). Dental rehabilitation of ED patients with zygomatic implant fixations and maxillary prosthesis were reported in literature, although with very limited numbers (Balshi & Wolfinger, 2002; Peñarrocha-Diago, Uribe-Origone, Rambla-Ferrer, & Guarinos-Carbó, 2004). Wang et al in a radiographic study evaluated the anatomical features of ED patients and reported that the development of zygomatic thickness and length in ED patients with oligodontia can be limited and can represent some difficulties for zygomatic implant insertions (Wang et al., 2019).

The oral rehabilitation of ED patients is quite challenging with conventional implants and prosthesis in terms of function and esthetics. One of the major limitations is the severe maxillary hypoplasia, and success might decrease critically due to insufficient retention and stability of the prosthesis. Integration of zygomatic implant surgery with implant-supported prosthetic rehabilitation can significantly optimize the quality of life of the ED patients. The aim of this retrospective clinical case series report was to evaluate the outcomes of ectodermal dysplasia syndrome patients that underwent oral rehabilitation with zygomatic implant surgery.

2 | MATERIALS AND METHODS

This retrospective study consisted of 9 ectodermal dysplasia syndrome patients with severely atrophic maxilla that were treated with zygomatic implants at the Department of Dentistry and Maxillofacial Surgery, University of Milan, (section of Galeazzi Hospital, Italy)

between March 2013 and March 2016 (out of 76 ED patients that received oral rehabilitation in the same section). A signed informed consent agreement form was obtained from all the patients, and the study protocol was in compliance with the principles laid down in the Declaration of Helsinki on medical protocol. This study was approved by institutional scientific review board of Galeazzi Hospital (Milan, Italy; authorization no. 2552377-L2058. "Implant rehabilitation of the partially or totally edentulous patient: evaluation of techniques and materials to improve predictability and maintenance"). The data of the patients were identified from the medical records as ectodermal dysplasia syndrome patients with severely atrophic maxilla that were treated with the use of implants inserted into the zygomatic bone.

Inclusion criterion was ectodermal dysplasia syndrome patients with severely atrophic maxilla and failure of previous bone grafting procedures that were treated with zygomatic implants. No additional exclusion criterion was set. The surgical, prosthetic and the follow-up protocol was described in detail in a previous article by the same team (Goker, Grecchi, Del Fabbro, & Grecchi, 2020).

Presurgical protocol included clinical examinations with preoperative cone beam computed tomography (CBCT) scans and panoramic radiographs. A professional oral hygiene session was given to each patient 1 week before the surgical operations. All the patients were prescribed with preoperative and postoperative antibiotics (Augmentin at a dosage of 1-g tablet every 8 hr for a total of 6 days or Azithromycin 500 mg for 3 days in cases of allergy to penicillin).

All surgeries were carried out by the same surgeon (Fr.G.) under general and with local anesthesia (4% articaine with 1:100,000 adrenalin). "Extra- sinus approach" was utilized in all patients for insertion of zygomatic implants (Noris Medical Ltd. or Medentis Medical ICX GmbH). In brief; the operation started with a palatal incision in the maxillary crest with vertical posterior releasing incisions and the muco-periosteal flap reflections. After flap reflection, all the bone surgeries and the implant site preparations were performed using drills and burs according to the instructions from the manufacturer. Finally, the ZIs were carefully inserted at a low speed (max 40 rpm), with a torque of 40–80 Ncm. The last 360 turn is done manually with an extraoral screwdriver. The surgical sites were covered with resorbable membrane or with Bichat fat pad, and the wounds were repositioned and sutured using continuous resorbable sutures (Vicryl, Ethicon FS-2, Johnson & Johnson).

Final or provisional prosthesis was delivered on the same day of surgery, which resulted in an improvement of the quality of life of the patients. The patients were recalled for clinical follow-up after 10 days, 1 month and every 3 months for the first year, and then twice a year. The occlusion was examined carefully at the delivery of the final prostheses and at each follow-up. In the first year following ZI insertions, follow-up criteria for the patients with Toronto bridge prosthesis included additional interventions. Every 6 months, Toronto bridge prosthesis was unscrewed to check the status of the surrounding tissues.

Implant survival rate was the primary outcome. Intra-operative and postoperative complications were evaluated as additional

criteria for survival. Implant survival rate was evaluated according to the following clinical and radiological criteria:

- absence of clinically detectable implant mobility;
- no evidence of peri-implant radiolucency;
- no spontaneous ZI failure;
- absence of pain and infections.

The representative preoperative intraoral and panoramic X-ray views of one of the ED patients can be seen in Figures 1 and 2. The representative intraoral and panoramic X-ray views of the same patient with zygomatic implants inserted can be seen in Figures 3 and 4. Figures 5 and 6 are intraoral views at 18 months follow-up. Figure 7 shows the panoramic X-ray image from 26 months after insertion of implants, which was taken at the last follow-up appointment.

This article was written following the STROBE (Strengthening the Reporting of Observational Studies in Epidemiology) guidelines (<http://www.strobe-statement.org>, von Elm et al., 2008).

2.1 | Statistical analysis

Given the small sample size, descriptive statistics was done using mean values and range for quantitative variables. The effect of the different variables (gender, age, antagonist dentition, reason for

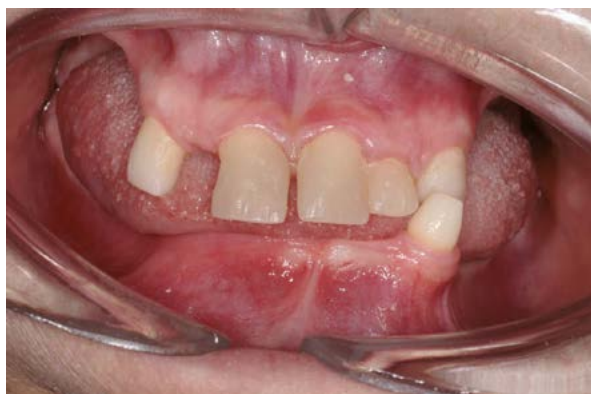

FIGURE 1 The initial intraoral image of an ectodermal dysplasia patient [Colour figure can be viewed at wileyonlinelibrary.com]

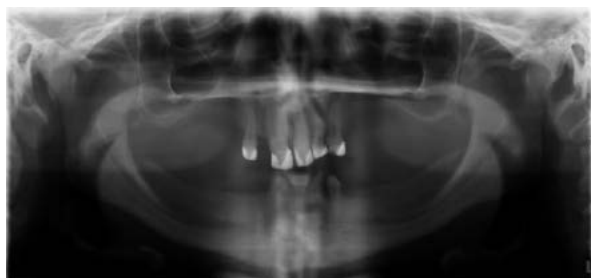


FIGURE 2 The initial panoramic X-ray image of the patient

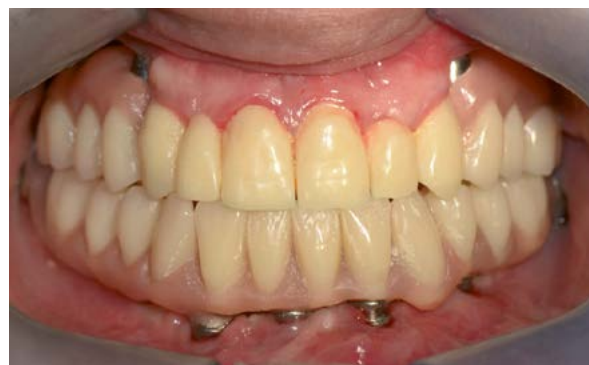

FIGURE 3 The post-prosthetic intraoral image of the patient [Colour figure can be viewed at wileyonlinelibrary.com]

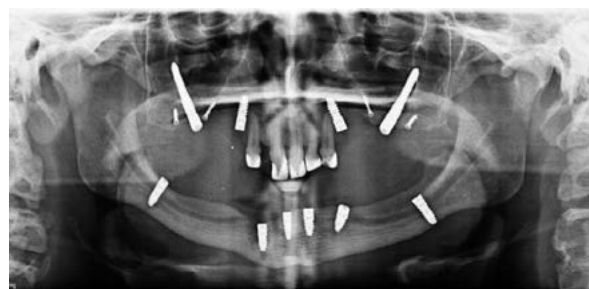

FIGURE 4 The panoramic X-ray image of the same ectodermal dysplasia patient 18 months after implant insertion surgery. Note: The conventional implants in the lower jaw of this patient were inserted using the technique of bypass of the inferior alveolar nerve. In this case, the position of the nerve was superficial, situated rather buccally in the mandibular bone and insertion of the implant was possible without damaging the nerve

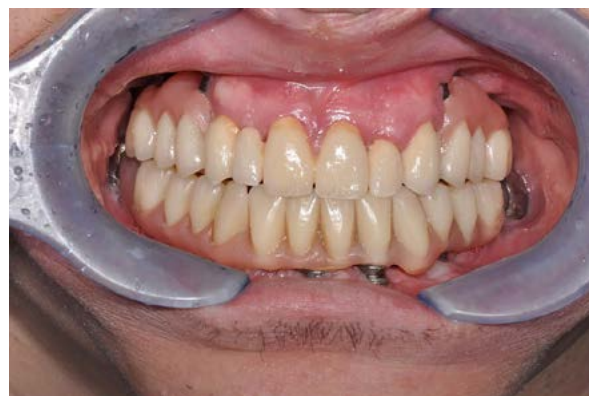

FIGURE 5 The intraoral view of the patient 18 months after implant surgery. Front view [Colour figure can be viewed at wileyonlinelibrary.com]

ZI, number of zygomatic and conventional implants, loading mode, prosthesis type, and ZI location) on implant survival was not evaluated, because no failures occurred in this study. Statistical analysis was performed using GraphPad Prism 5.03 (GraphPad Software, Inc., La Jolla, CA, USA).

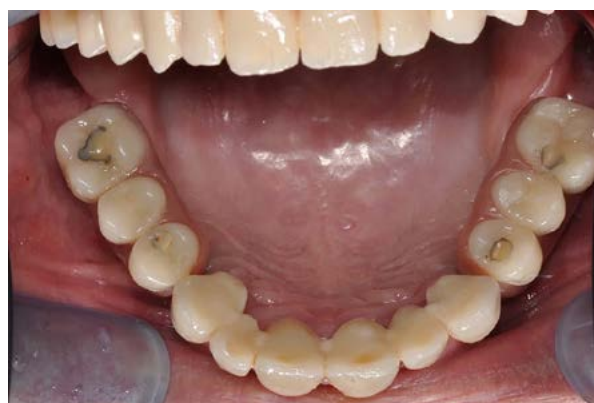

FIGURE 6 The intraoral view of the patient 18 months after implant surgery. Occlusal view [Colour figure can be viewed at wileyonlinelibrary.com]

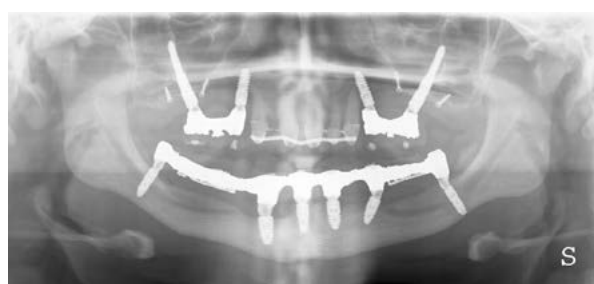

FIGURE 7 The panoramic X-ray image of the patient 26 months after implant surgery

3 | RESULTS

A total of 9 ectodermal dysplasia syndrome patients aged between 21 and 56 years (mean age 36.8) with severely atrophic maxilla were included in this study. In the population, one of the patients had diabetes and no other patient had any additional chronic or other health condition.

All the included patients were Class VI-V Cawood and Howell. The quality of bone of all patients was D1 and D2, which can be assumed to be mainly due to the total absence of the teeth.

Eight patients had severe oligodontia (with six or more teeth missing):

1. Maxilla (2 incisors + 2 canine + 2 molar) Mandible(none)
2. Maxilla (none) Mandible (4 incisors + 2 canine + 4 premolar + 1 molar)
3. Maxilla (3 incisors) Mandible (none)
4. Maxilla (3 incisors) Mandible (none)
5. Maxilla (4 incisors + 2 canine) Mandible (none)
6. Maxilla (3 incisors) Mandible (none)
7. no teeth in maxilla and mandible
8. Maxilla (4 incisors) Mandible (2 canine + 2 molar)
9. Maxilla (4 incisors + 1 premolar) Mandible (2 molar)

All the patients had severely atrophic maxilla (6 patients with atrophic maxilla, 3 patients with atrophic maxilla and failures of previous bone grafting procedures (2)/implants (1)). Three of the patients had additional orthognathic surgery (Le Fort 1 osteotomy), and only one patient had orthodontic treatment with braces before zygomatic implant surgery. All the other patients had oral rehabilitation with zygomatic implant surgical management without any additional treatment modalities.

Two of the patients had failures from previous grafts. One of these was failures was due to a dehiscence in iliac flap. One patient had a failure of previous conventional implants (two implants were lost due to peri-implantitis), and insertion of zygomatic implants was considered.

All the patients were treated with a total of 19 zygomatic implants. The mean follow-up of the patients was 55 months (with a range of 44–84 months).

Primary stability was achieved in all implants with minimum insertion torque of 40 Ncm. Five of the patients received immediate loading of the prosthesis while four of the prosthesis were done in a delayed approach. The decision for loading protocol based on the

TABLE 1 Patient demographics and data regarding the implant success

Patient	Age	Gender	N. ZI	N. CI	ZI location	Total follow-up	ZI survival %	Complications
1	51	F	2	4	16, 26	52	100	None
2	47	F	2	4	16, 26	60	100	None
3	21	F	2	4	16, 26	55	100	None
4	56	F	2	4	16, 26	46	100	None
5	25	M	2	2	16, 26	65	100	None
6	52	M	4	2	16, 26, 13, 23	44	100	None
7	27	M	2	2	16, 26	84	100	None
8	23	M	2	3	16, 26	77	100	None
9	29	F	1	4	26	51	100	None

Abbreviations: CI, Conventional implants; N, Number; ZI, Zygomatic implant.

request of each patient was mostly due to economic reasons, independent of the primary stability of the ZI.

The overall implant survival rate in this study was 100% without any complications and without any dropouts. Eight of the patients had acrylic resin Toronto bridge prosthesis, and one patient had metal-acrylic resin prostheses. Details on antagonist dentition can be listed as follows: one patient with acrylic resin Toronto bridge prosthesis, one patient with fixed metal-acrylic resin prosthesis on natural teeth, one patient with removable prosthesis, two patients with natural teeth, three patients with implants with fixed metal-acrylic resin prosthesis, and one patient with natural teeth plus implants with fixed metal-acrylic resin prosthesis.

Additional data of the study group concerning age, gender of the patients, number of zygomatic and conventional implants, ZI location are listed in Table 1. Type of prosthesis, loading protocol, and antagonist dentition are listed in Table 2.

4 | DISCUSSION

The reconstruction of oral function in ectodermal dysplasia syndrome patients is a challenging situation for the oral and maxillofacial surgeon (Deshpande & Kumar, 2010b). Oral rehabilitation of ED patients with dental implants is a common treatment modality, as reported by various authors (Chrcanovic, 2018; Lypka et al., 2008; Wang et al., 2016). However, ED patients usually have reduced residual alveolar bone with "knife-edge" morphology, making implant reconstruction a challenge (Deshpande & Kumar, 2010b). ED patients usually need additional interventions including bone grafting and/or sinus augmentation procedures (Guckes, Brahim, McCarthy, Rudy, & Cooper, 1991; Worsaae, Jensen, Holm, & Holsko, 2007). Additionally, limitations in soft tissues can compromise the esthetic results and can present a higher risk for possible biologic complications (Salinas, Sheridan, Castellon, & Block, 2005).

Oral rehabilitation can afford ED patients, the opportunity to have normal phonation, mastication, swallowing, and esthetics in means of facial support (Grecchi, Pagliani, Pagliani, Mancini, Zollino,

& Carinci, 2010; Grecchi, Zingari, et al., 2010). The typical old-age appearance of the face can be decreased by increasing the vertical dimension of the lower face. Consequently, the temporomandibular joint functions can be improved (Grecchi, Pagliani, et al., 2010; Grecchi, Zingari, et al., 2010).

In ED patients, sufficient bone may be available only at the mid-symphysial area in the mandible, where one implant could provide stability for a mandibular denture (Kearns et al., 1999). The maxilla is relatively more retruded than the mandible. Additionally, the nasal alar width and mouth width are usually significantly smaller than normal patients (Dellavia, Catti, Sforza, Tommasi, & Ferrario, 2010; Sforza, Dellavia, Vizzotto, & Ferrario, 2003). Total or partial removable prosthesis or overdentures is often the first treatment choice in most cases (Garagiola et al., 2007). However, prosthetic solutions using dental implants should be considered (Grecchi, Pagliani, et al., 2010; Grecchi, Zingari, et al., 2010; Kearns et al., 1999). Dental implants with/without bone grafts can be valuable devices with no difference compared with unaffected patients (Grecchi, Zingari, et al., 2010).

Zygomatic implant (ZI) surgery can be considered as a treatment option for ED syndrome patients and was tested by researchers with positive results (Balshi & Wolfinger, 2002; Peñarrocha-Diogo et al., 2004). However, data concerning the outcome of this approach in such patients are currently very limited. According to the successful results obtained from this study, the oral rehabilitation of ED patients can be a valuable treatment option.

ZI is considered as a successful alternative for rehabilitation of patients with severe maxillary atrophy; however, ZI insertion is a major surgery and can represent some risks (Aparicio, Manresa, Francisco, Ouazzani, et al., 2014; Brånemark et al., 2004; Candel-Martí, Carrillo-García, Penarrocha-Oltra, & Penarrocha-Diogo, 2012; Chrcanovic & Abreu, 2013; Chrcanovic, Albrektsson, & Wennerberg, 2016; D'Agostino et al., 2016; Grecchi et al., 2017; Goker et al., 2020; Yates et al., 2014). The possible complications of ZI surgery include sinusitis, soft tissue infections, paresthesia, and oroantral fistula, penetration of the orbital cavity during the drilling protocol, and failure of the implants (Filho, Amaral, Curra, dos Santos, & Cardoso, 2016; Maló, Nobre, Lopes, Ferro, & Moss, 2015; Nobre, Maló, & Gonçalves, 2015).

TABLE 2 Data regarding the prosthetic treatment

Patient	Loading	Prosthesis type	Antagonist dentition	Prosthesis survival %	Complications
1	Immediate	Toronto (resin)	Implant-supported fixed prosthesis	100	None
2	Immediate	Toronto (resin)	Natural teeth	100	None
3	Immediate	Toronto (resin)	Natural teeth	100	None
4	Immediate	Fixed (resin)	Implant-supported fixed prosthesis	100	None
5	Delayed	Toronto (resin)	Toronto resin	100	None
6	Delayed	Toronto (resin)	Implant-supported fixed prosthesis	100	None
7	Delayed	Toronto (resin)	Removable prosthesis	100	None
8	Delayed	Toronto (resin)	Implant-supported fixed prosthesis and natural teeth	100	None
9	Delayed	Toronto (resin)	Natural teeth-supported fixed prosthesis	100	None

According to an anatomical analysis of zygomatic bone by Wang et al in 2019, zygomatic thickness and length in EC patients are usually limited and insufficient. This can represent some limitations, especially for quad (4 ZIs) zygomatic implantations (Wang et al., 2019). However, where the anatomy is appropriate, the quad zygomatic protocols can be used. In the present study, the insertion of quad (four) ZIs was possible just in one patient. Seven patients received bilateral 2 zygomatic implants (in the molar region), while one patient received unilateral 1 ZI.

The incidence of EDs is approximately 7 in 10,000 (Bani et al., 2010) physiological and esthetic considerations in such patients are compromised due to the condition (Carvalho et al., 2013). The clinical manifestations of ED cause considerable social problems in individuals affected by the condition (Carvalho et al., 2013). Patients with ectodermal dysplasia rate their quality of life worse than is usually prevalent in the normal population (Hanisch et al., 2019). Currently, long-term data outcome reports based on clinical evidence for conventional implant and bone augmentation procedures and or zygomatic implant interventions in ED patients are very limited.

In the present study, the decision for loading protocol for prosthetic over-structure was discussed by each patient. The primary stability of the ZI was present in all the cases, and the choice mostly was based on economic reasons.

5 | CONCLUSIONS

This retrospective clinical case series evaluated the outcomes of the ectodermal dysplasia syndrome patients that underwent zygomatic implant surgery with at least 3-year follow-up. Limited outcomes per se were reported. High success rate reported is mostly dependent on the experience of the single surgeon that performed all ZI surgeries. The limitations of the present study include a single-center retrospective report with no control groups. Future studies should focus on case-control studies with longer follow-up periods and larger groups.

According to the results of this study, zygomatic surgery can be considered as a viable and safe alternative to conventional treatment modalities for oral rehabilitation of ectodermal dysplasia syndrome patients. However, clinicians must be aware that zygomatic implant insertion is a challenging procedure and is not risk free. Highly experienced surgeon with prior special training is crucial for safe procedures and successful outcomes.

CONFLICT OF INTEREST

The authors declare no potential conflicts of interest with respect to the authorship and/or publication of this article.

AUTHOR CONTRIBUTIONS

Funda Goker: Conceptualization; data curation; formal analysis; methodology; validation; writing – original draft; writing – review & editing. **Emma Grecchi:** Conceptualization; data curation; formal analysis; methodology; validation; writing – original draft; writing

– review & editing. **Evangelista Giovanni Mancini:** Conceptualization; data curation; formal analysis; validation; writing – review & editing. **Massimo Del Fabbro:** Conceptualization; data curation; formal analysis; investigation; methodology; project administration; software; supervision; validation; writing – original draft; writing – review & editing. **Francesco Grecchi:** Conceptualization; data curation; investigation; methodology; project administration; resources; supervision; validation; writing – original draft; writing – review & editing.

ORCID

Funda Goker  <https://orcid.org/0000-0002-2354-361X>

Massimo Del Fabbro  <https://orcid.org/0000-0001-7144-0984>

REFERENCES

- Aparicio, C., Manresa, C., Francisco, K., Claros, P., Alandez, J., Gonzalez-Martin, O., & Albrektsson, T. (2014). Zygomatic implants: Indications, techniques and outcomes, and the Zygomatic Success Code. *Periodontology* 2000, 66(1), 41–58. <https://doi.org/10.1111/prd.12038>
- Aparicio, C., Manresa, C., Francisco, K., Ouazzani, W., Claros, P., Potau, J. M., & Aparicio, A. (2014). The long-term use of zygomatic implants: A 10-year clinical and radiographic report. *Clinical Implant Dentistry and Related Research*, 16(3), 447–459. <https://doi.org/10.1111/cid.12007>
- Aparicio, C., Ouazzani, W., Garcia, R., Arevalo, X., Muela, R., & Fortes, V. (2006). A prospective clinical study on titanium implants in the zygomatic arch for prosthetic rehabilitation of the atrophic edentulous maxilla with a follow-up of 6 months to 5 years. *Clinical Implant Dentistry and Related Research*, 8(3), 114–122. <https://doi.org/10.1111/j.1708-8208.2006.00009.x>
- Balshi, T. J., & Wolfinger, G. J. (2002). Treatment of congenital ectodermal dysplasia with zygomatic implants: A case report. *International Journal of Oral and Maxillofacial Implants*, 17(2), 277–281.
- Bani, M., Tezkirecioglu, A. M., Akal, N., & Tuzuner, T. (2010). Ectodermal dysplasia with anodontia: A report of two cases. *European Journal of Dentistry*, 4(2), 215–222. <https://doi.org/10.1055/s-0039-1697832>
- Branemark, P. I. (1998). *Surgery and fixture installation: Zygomaticus fixture clinical procedures* (1st ed.). Goteborg, Sweden: Nobel Biocare.
- Brånemark, P. I., Gröndahl, K., Öhrnell, L. O., Nilsson, P., Petruson, B., Svensson, B., ... Nannmark, U. (2004). Zygoma fixture in the management of advanced atrophy of the maxilla: Technique and long-term results. *Scandinavian Journal of Plastic Reconstructive Surgery Hand Surgery*, 38(2), 70–85. <https://doi.org/10.1080/02844310310023918>
- Candel-Marti, E., Carrillo-Garcia, C., Penarrocha-Oltra, D., & Penarrocha-Diago, M. (2012). Rehabilitation of atrophic posterior maxilla with zygomatic implants: Review. *Journal of Oral Implantology*, 38(5), 653–657. <https://doi.org/10.1563/AAID-JOI-D-10-00126>
- Carvalho, M. V., de Sousa, S. J. R., de Melo, F. P. C., Faro, T. F., Santos, A. C. N., Carvalho, S., & Sobral, A. P. V. (2013). Hypohidrotic and hidrotic ectodermal dysplasia: A report of two cases. *Dermatology Online Journal*, 19(7), 1–7.
- Chana, H., Smith, G., Bansal, H., & Zahra, D. (2019). A retrospective cohort study of the survival rate of 88 zygomatic implants placed over an 18-year period. *International Journal of Oral and Maxillofacial Implants*, 34(2), 461–470. <https://doi.org/10.11607/jomi.6790>
- Chrcanovic, B. R. (2018). Dental implants in patients with ectodermal dysplasia: A systematic review. *Journal of Cranio-Maxillo-Facial Surgery*, 46, 1211–1217. <https://doi.org/10.1016/j.jcms.2018.05.038>
- Chrcanovic, B. R., & Abreu, M. H. (2013). Survival and complications of zygomatic implants: A systematic review. *Oral and Maxillofacial Surgery*, 17(2), 81–93. <https://doi.org/10.1007/s10006-012-0331-z>
- Chrcanovic, B. R., Albrektsson, T., & Wennerberg, A. (2016). Survival and complications of zygomatic implants: An updated systematic review.

- Journal of Oral Maxillofacial Surgery*, 74(10), 1949–1964. <https://doi.org/10.1016/j.joms.2016.06.166>
- D'Agostino, A., Trevisiol, L., Favero, V., Pessina, M., Procacci, P., & Nocini, P. F. (2016). Are zygomatic implants associated with maxillary sinusitis? *Journal of Oral Maxillofacial Surgery*, 74(8), 1562–1573. <https://doi.org/10.1016/j.joms.2016.03.014>
- Dellavia, C., Catti, F., Sforza, C., Tommasi, D. G., & Ferrario, V. F. (2010). Craniofacial growth in ectodermal dysplasia. An 8-year longitudinal evaluation of Italian subjects. *Angle Orthodontist*, 80(4), 733–739. <https://doi.org/10.2319/101909-584.1>
- Deshpande, S. N., & Kumar, V. (2010). Ectodermal dysplasia - Alveolar reconstruction and rehabilitation. *Indian Journal of Plastic Surgery*, 43(1), 92–96. <https://doi.org/10.4103/0970-0358.63969>
- Deshpande, S. N., & Kumar, V. (2010b). Ectodermal dysplasia - Maxillary and mandibular alveolar reconstruction with dental rehabilitation: A case report and review of the literature. *Indian Journal of Plastic Surgery*, 43(1), 92–96. <https://doi.org/10.4103/0970-0358.63969>
- Filho, H. N., Amaral, W. S., Curra, C., dos Santos, P. L., & Cardoso, C. L. (2016). Zygomatic implant: Late complications in a period of 12 years of experience. *Revista Clinica de Periodontia Implantologia y Rehabilitacion Oral*, <https://doi.org/10.1016/j.piro.2016.03.007>
- Garagiola, U., Maiorana, C., Ghiglione, V., Marzo, G., Santoro, F., & Szabò, G. (2007). Osseointegration and guided bone regeneration in ectodermal dysplasia patients. *Journal of Craniofacial Surgery*, 18(6), 1296–1304. <https://doi.org/10.1097/01.scs.0000246497.62065.5a>
- Goker, F., Grecchi, E., Del Fabbro, M., & Grecchi, F. (2020). Clinical outcome of 302 zygomatic implants in 110 patients with a follow-up between 6 months and 7 years. *Clinical Implant Dentistry and Related Research*, 2020, 1–9. <https://doi.org/10.1111/cid.12909>
- Grecchi, F., Bianchi, A. E., Siervo, S., Grecchi, E., Lauritano, D., & Carinci, F. (2017). A new surgical and technical approach in zygomatic implantology. *Oral & Implantology*, 102, 197–208. <https://doi.org/10.11138/orl/2017.10.2.197>
- Grecchi, F., Pagliani, L., Mancini, G., Zollino, I., & Carinci, F. (2010). Implant treatment in grafted and native bone in patients affected by ectodermal dysplasia. *Journal of Craniofacial Surgery*, 21(6), 1776–1780. <https://doi.org/10.1097/SCS.0b013e3181f40378>
- Grecchi, F., Zingari, F., Bianco, R., Zollino, I., Casadio, C., & Carinci, F. (2010). Implant rehabilitation in grafted and native bone in patients affected by ectodermal dysplasia: Evaluation of 78 implants inserted in 8 patients. *Implant Dentistry*, 19(5), 400–408. <https://doi.org/10.1097/ID.0b013e3181e40609>
- Guckes, A. D., Brahim, J. S., McCarthy, G. R., Rudy, S. F., & Cooper, L. F. (1991). Using endosseous dental implants for ectodermal dysplasia. *Journal of American Dental Association*, 122(10), 59–62. <https://doi.org/10.14219/jada.archive.1991.0307>
- Hanisch, M., Sielker, S., Jung, S., Kleinheinz, J., & Böhner, L. (2019). Self-assessment of oral health-related quality of life in people with ectodermal dysplasia in Germany. *International Journal of Environmental Research and Public Health*, 16(11), 1933. <https://doi.org/10.3390/ijerph16111933>
- Itin, P. H. (2013). Ectodermal dysplasia: Thoughts and practical concepts concerning disease classification - The role of functional pathways in the molecular genetic diagnosis. *Dermatology*, 226(2), 111–114. <https://doi.org/10.1159/000346613>
- Itin, P. H., & Fistarol, S. K. (2004). Ectodermal dysplasias. *American Journal of Medical Genetics C Seminars in Medical Genetics*, 131(1), 45–51. <https://doi.org/10.1002/ajmg.c.30033>
- Kearns, G., Sharma, A., Perrot, D., Smith, B., Kaban, L., & Vargervik, K. (1999). Placement of an endosseous implants in children and adolescents with hereditary ectodermal dysplasia. *Oral Surgery Oral Medicine Oral Pathology Oral Radiology*, 88(1), 5–10. [https://doi.org/10.1016/S1079-2104\(99\)70185-X](https://doi.org/10.1016/S1079-2104(99)70185-X)
- Lypka, M., Yarmand, D., Burstein, J., Tso, V., & Yamashita, D. D. (2008). Dental implant reconstruction in a patient with ectodermal dysplasia using multiple bone grafting techniques. *Journal of Oral and Maxillofacial Surgery*, 66(6), 1241–1244. <https://doi.org/10.1016/j.joms.2008.01.004>
- Maló, P., de Araujo Nobre, M., & Lopes, I. (2008). A new approach to rehabilitate the severely atrophic maxilla using extramaxillary anchored implants in immediate function: A pilot study. *Journal of Prosthetic Dentistry*, 100, 354–366. [https://doi.org/10.1016/S0022-3913\(08\)60237-1](https://doi.org/10.1016/S0022-3913(08)60237-1)
- Maló, P., Nobre, M. A., Lopes, A., Ferro, A., & Moss, S. (2015). Extramaxillary surgical technique: Clinical outcome of 352 patients rehabilitated with 747 zygomatic implants with a follow-up between 6 months and 7 years. *Clinical Implant Dentistry and Related Research*, 17, 153–162. <https://doi.org/10.1111/cid.12147>
- Nobre, M. A., Maló, P., & Gonçalves, I. (2015). Evaluation of clinical soft tissue parameters. *Implant Dentistry*, 24(3), 267–274. <https://doi.org/10.1097/ID.0000000000000253>
- Peñarrocha-Diago, M., Uribe-Origone, R., Rambla-Ferrer, J., & Guarinos-Carbó, J. (2004). Fixed rehabilitation of a patient with hypohidrotic ectodermal dysplasia using zygomatic implants. *Oral Surgery Oral Medicine Oral Pathology Oral Radiology Endodontology*, 98(2), 161–165. <https://doi.org/10.1016/j.tripleo.2003.12.043>
- Salinas, T. J., Sheridan, P. J., Castellon, P., & Block, M. S. (2005). Treatment planning for multiunit restorations: The use of diagnostic planning to predict implant and esthetic results in patients with congenitally missing teeth. *Journal of Oral Maxillofacial Surgery*, 63(9), 45–58. <https://doi.org/10.1016/j.joms.2005.05.155>
- Sforza, C., Dellavia, C., Vizzotto, L., & Ferrario, V. F. (2003). Variations in facial soft tissues of Italian individuals with ectodermal dysplasia. *Cleft Palate Craniofacial Journal*, 41(3), 62–67. <https://doi.org/10.1597/03-033.1>
- von Elm, E., Altman, D. G., Egger, M., Pocock, S. J., Gøtzsche, P. C., & Vandenbroucke, J. P. (2008). STROBE Initiative. The strengthening the reporting of observational studies in epidemiology (STROBE) statement: Guidelines for reporting observational studies. *Journal of Clinical Epidemiology*, 61, 344–349. <https://doi.org/10.1016/j.jclinepi.2007.11.008>
- Wang, H., Hung, K., Zhao, K., Wang, Y., Wang, F., & Wu, Y. (2019). Anatomical analysis of zygomatic bone in ectodermal dysplasia patients with oligodontia. *Clinical Implant Dentistry and Related Research*, 21(2), 310–316. <https://doi.org/10.1111/cid.12731>
- Wang, Y., He, J., Decker, A. M., Hu, J. C., & Zou, D. (2016). Clinical outcomes of implant therapy in ectodermal dysplasia patients: A systematic review. *International Journal of Oral and Maxillofacial Surgery*, 45(8), 1035–1043. <https://doi.org/10.1016/j.ijom.2016.03.011>
- Worsaae, N., Jensen, B. N., Holm, B., & Holsko, J. (2007). Treatment of severe hypodontia-oligodontia: An interdisciplinary concept. *International Journal of Oral and Maxillofacial Surgery*, 36(6), 473–480. <https://doi.org/10.1016/j.ijom.2007.01.021>
- Yates, J. M., Brook, I. M., Patel, R. R., Wrang, P. F., Atkins, S. A., El-Awa, A., ... Bolt, R. (2014). Treatment of the edentulous atrophic maxilla using zygomatic implants: Evaluation of survival rates over 5–10 years. *International Journal of Oral and Maxillofacial Surgery*, 43(2), 237–242. <https://doi.org/10.1016/j.ijom.2013.08.012>

How to cite this article: Goker F, Grecchi E, Mancini EG, Del Fabbro M, Grecchi F. Zygomatic implant survival in 9 ectodermal dysplasia patients with 3.5- to 7-year follow-up. *Oral Dis*. 2020;26:1803–1809. <https://doi.org/10.1111/odi.13505>

Insertion of Zygomatic Implants with a Technical Modification of the Extrasinus Protocol: A Retrospective Case Series

Funda Goker, DDS, MSc, PhD¹/Francesco Grecchi, MD, OMFS²/Emma Grecchi, DDS, MSc³/
Alessandro R. Bolzoni, MD, OMFS⁴/Massimo Del Fabbro, MSc, PhD⁵

Purpose: The aim of this retrospective clinical case series report was to evaluate the outcomes of patients who underwent zygomatic implant surgery with a recent technical modification of the extrasinus surgical protocol. **Materials and Methods:** The implant system presented in this study had a novel designed unthreaded body with a 12.5-mm sharp threaded apical end for obtaining maximum retention to the zygomatic bone. A total of 92 patients with severely atrophic maxillae were included in this study. All the patients were treated with a modification of the extrasinus protocol for insertion of 261 zygomatic implants. The mean follow-up of the patients was 34.5 ± 17.1 (SD) months (range: 6 to 72 months). The implant survival rate was the primary outcome. The intraoperative and postoperative complications were evaluated as additional criteria for success. **Results:** The cumulative implant survival rate was 97.99%. Definitive or provisional prostheses were delivered on the same day of surgery, which resulted in an improvement in the quality of life of the patients. Five implants failed in four patients. No sinusitis or mucositis was seen in any of the patients. Eleven postoperative complications occurred in seven patients. **Conclusion:** The novel zygomatic surgery protocol introduced in this study can be an effective alternative to augmentation procedures and conventional implants, especially in cases of extremely atrophic posterior maxillae. *Int J Oral Maxillofac Implants* 2020;35:974–981. doi: 10.11607/jomi.8328

Keywords: atrophic maxilla, bone atrophy, dental implants, oral rehabilitation, zygomatic implants

Oral rehabilitation of patients with edentulous and severely resorbed posterior maxillae represents a special challenging condition for maxillofacial surgeons. The posterior maxillary ridge undergoes a rapid and progressive atrophy following tooth loss, and quantity of bone decreases dramatically. In addition to poor bone volume, this region usually presents poor bone quality, excessive occlusal forces, and hyperpneumatization of the sinus, which consequently may increase the risk of implant failures.¹ As a solution for this compromised situation, many treatment modalities

have been proposed in the literature, such as sinus elevation operation, onlay bone augmentation, angled implants, short implants, or zygomatic implants.^{2–5} Zygomatic implants were introduced by Brånemark in the 1990s⁶ as a major breakthrough in the rehabilitation of the atrophic posterior maxilla for eliminating or minimizing the need for bone grafting^{6,7} and for obtaining a steady anchorage in the zygomatic bone in cases when rehabilitation by conventional oral implants is unfeasible.^{8,9} Even in complicated cases, such as large maxillary defects due to oncologic resections, trauma, and congenital diseases, the complete rehabilitation of the total maxilla can be possible with the insertion of zygomatic implants.^{1,10}

Since their first introduction, the main indication for zygomatic implants is the rehabilitation of a severe edentulous atrophic maxilla after tumor resection or trauma. However, indications for zygomatic implants also include failure of previous bone grafts and/or implants and failure of sinus augmentation. Contraindications for the use of zygomatic implants include acute infection in the maxillary sinus and uncontrolled systemic diseases. Special attention should always be paid to eliminate any existing acute infection of the maxillary sinus before placement of the zygomatic implants in order to prevent possible future complications.^{11–14}

Zygomatic implants were proposed as a valid alternative to bone augmentation procedures considering the reduced cost and time.^{6,13–16} Zygomatic implants

¹Department of Biomedical, Surgical and Dental Sciences, University of Milano, Milan, Italy.

²IRCCS Orthopedic Institute Galeazzi, Milan, Italy.

³Oral Surgery Unit, IRCCS Ca' Granda Ospedale Maggiore Policlinico di Milano, Milan, Italy.

⁴Department of Biomedical, Surgical and Dental Sciences, University of Milano, Milan, Italy; Dental and Maxillo-Facial Surgery Unit, IRCCS Ca' Granda Ospedale Maggiore Policlinico di Milano, Milan, Italy.

⁵Department of Biomedical, Surgical and Dental Sciences, University of Milano, Milan, Italy; IRCCS Orthopedic Institute Galeazzi, Milano, Italy.

Correspondence to: Dr Massimo Del Fabbro, University of Milano, Department of Biomedical, Surgical and Dental Sciences, IRCCS Orthopedic Institute Galeazzi, Via Riccardo Galeazzi, 4, 20161 Milano, Italy. Email: massimo.delfabbro@unimi.it

Submitted February 7, 2020; accepted March 30, 2020.

©2020 by Quintessence Publishing Co Inc.

can provide the surgeon the possibility of obtaining a firm anchorage to the zygomatic bone,^{13–16} and the overall operating and office time decreases, with lower costs and high success rates.^{5,8,9,12,16–18}

The additional anchorage on the zygomatic bone plays an important role in the high percentage of successful results for this procedure, and the quality of life of patients dramatically increases.^{15–19} Insertion of a zygomatic implant is a major surgical procedure, which should be performed by a properly trained surgeon. The main disadvantages of zygomatic implants include the risk of soft tissue complications around the abutments, sinusitis, and the risk of damage to surrounding complex anatomical structures.^{19,20} In recent publications on zygomatic implants, the importance of reducing the therapeutic time is frequently emphasized by comparing zygomatic implants and conventional methods, with the conclusion of an advantage for zygomatic implants.²¹ Overall, the unsatisfactory results of any therapy, in fact, do not just depend on inadequate surgical skills but on the excessive and incorrect demands that might have been placed on the technique itself as incorrect indications.

The surgical technique reported in the present study is a modification of the extrasinus protocol, which utilizes implants of a specific design with an unthreaded long body and a 12.5-mm apical thread (Fig 1). A bypass of the maxillary sinus prevents any possible additional postoperative complications caused by damage to the sinus membrane. The prosthetic platform being shifted more buccally allows for a more appropriate position of the emergence close to the alveolar crest, a less bulky restoration, and a better design for the prosthesis.²² The aim of this retrospective study was to evaluate the clinical outcome of zygomatic implants inserted in severely resorbed maxillae using a recent technical modification of the extrasinus protocol.

MATERIALS AND METHODS

The study was designed as a retrospective clinical case series with 92 patients, who were referred to the Department of Dentistry and Maxillofacial Surgery at the University of Milano (section of Galeazzi Hospital, Italy). All the patients signed an informed consent form, and the study protocol was in compliance with the principles of the Declaration of Helsinki on medical protocol. Institutional review board approval was obtained for retrospective studies on implants, with protocol number 2552377-L2058 ("Riabilitazione implantare del paziente parzialmente o totalmente edentulo: Valutazione delle tecniche e dei materiali per migliorare la predicibilità e il mantenimento"—"Implant rehabilitation of the partially or totally edentulous patient: Evaluation of



Fig 1 Conical bur with nonworking tip.

techniques and materials to improve predictability and maintenance").

All the patients presented in this study were treated with a modification of the extrasinus protocol with a specially designed zygomatic implant (Noris Medical). Seventy-nine of the patients received immediate loading of the prosthesis, while 13 of the prosthetic rehabilitations were functionalized in a delayed approach. The decision for immediate loading was not based on a scientific indication but was given upon the request of each patient, mostly due to economic reasons, independent of the primary stability of the zygomatic implant, which was present in all the cases.

The inclusion criterion was total edentulism in severely atrophic maxillae Class IV-V Cawood and Howell.²³ The exclusion criteria were: major systemic health conditions (Patients ASA-3 and 4 according to the American Society of Anesthesiologists), active infection in the oral and maxillofacial region, radiotherapy or chemotherapy in the 12 months prior to surgery, and inability or unwillingness to follow the instructions for the follow-up. The population of the patients presented some systemic conditions, which can be listed as follows: two depression, one Sjogren syndrome, one pulmonary embolism, one osteoporosis, two arthrosis, one heavy smoker, two hypothyroid, two hypertension, and four patients with ectodermal dysplasia. All these conditions were under control, so they were not accepted as major obstacles to performing surgical operations. There were two bruxist patients, and one of them lost an implant due to this condition.

The patients were radiologically evaluated with preoperative panoramic radiographs and CBCT scans for the form and dimensions of the maxillary and zygomatic bone and for any infections or pathologies in the maxillary sinus. A blood test, electrocardiography, and chest radiography for all the patients were obtained in order to evaluate general health status. A week before surgery, a professional session of oral hygiene was provided to each patient with oral rinses (chlorhexidine digluconate 0.2% mouthwash, which was started 3 days prior to the surgery). The patients were prescribed with preoperative and postoperative antibiotics: augmentin

(amoxicillin and clavulanate potassium) at a dosage of a 1-g tablet every 8 hours for a total of 6 days, starting from the day before the surgery. In cases when an allergy to penicillin was declared by the patient, azithromycin 500 mg for 3 days was prescribed as an alternative.

All surgeries were carried out under general anesthesia by the same surgeon (F.G.). Local anesthesia (4% articaine with 1:100,000 adrenalin) was also administered to each patient. The surgical approach as well as the presurgical procedure, the prosthetic procedure, and the follow-up protocol were described in detail in a previous article by the same team.²²

In brief, a palatal incision was made in the maxillary crest with bilateral vertical posterior releasing incisions, and the mucoperiosteal flap was reflected to expose the alveolar crest, the piriform opening, the central and posterior part of the zygomatic complex, the lateral wall of the maxillary sinus, and the infraorbital nerve emergence. In cases of quad-zygoma surgery, the mucoperiosteal flap reflection reached the lower orbital rim. Special attention was paid to the emergence of the infraorbital nerve during the whole surgical operation, in order to position the anterior zygomatic implant at a safe distance. The implant site preparation was performed with drills and burs that were mounted on a contra-angle handpiece, which allowed easier positioning of zygomatic implants distal to the maxillary second premolar region. After the reflection of the mucoperiosteal flap, corticotomy of the anterolateral wall of the sinus was prepared with a round (4 mm in diameter) diamond bur.

In order to determine the correct intraoral emergence of the zygomatic implant, these holes were then connected, creating grooves by using diamond cylindrical body burs with no working tips and with three different levels of grits (fine, medium, coarse). The conical bur with a nonworking tip provided a valid point of support and fulcrum for the subsequent bone preparation (Fig 1). In fact, this procedure, when correctly performed, also protects the integrity of the sinus membrane. Small possible accidental perforations of the sinus mucosa in the region of the zygomatic recess are not of significant importance in terms of sinusitis sequelae. The preparation of the zygomatic implant site was continued using a sequence of drills (2.5 cm long and 2 to 3.2 mm in diameter) with the final conical cutting tips. A depth indicator was then used to determine the correct length of the zygomatic implant with its tip located on the external zygomatic bone. Starting the preparation from the most anterior zygomatic implant is always advisable since it is the more complicated and dangerous one. The preparation of the distal implant was done as posteriorly and vertically as possible so that the apexes of the zygomatic implants were convergent and did not interfere between them.

Finally, the zygomatic implants were positioned with an extraoral screwdriver, or with the standard protocol of screwing that is used with conventional implants. The flaps were repositioned and sutured using resorbable sutures.

The patients were recalled for clinical follow-up after 10 days, 1 month, and every 3 months for the first year, and then twice a year. The occlusion was examined carefully at the delivery of the definitive prostheses and at each follow-up. In the first year following zygomatic implant insertion, the follow-up criteria for the patients with Toronto prostheses (a permanent prosthesis that is fixed on implants by screws) included additional interventions that can be described as follows. Every 6 months, the Toronto prostheses were unscrewed to check the status of the surrounding tissues. Implant success and survival rates were evaluated based on the clinical and radiologic criteria as a primary outcome. Complications were evaluated as additional criteria for success.

Zygomatic implants were considered to be successful according to the criteria described by Aparicio et al as follows.¹⁵

Successful:

- Stable zygomatic implant with no mobility and no pain
- No associated sinus pathology
- Healthy peri-implant tissue condition

Unsuccessful:

- Clear clinical mobility with evidence of disintegration of the apical part of the implant
- Rotation of the implant
- Persistent pain
- Sinus pathology
- Recession of the tissues with more than seven exposed threads of the implants

Statistical Analysis

Descriptive statistics were done using mean values and SD for quantitative variables normally distributed. Normality of distributions was assessed using the d'Agostino and Pearson omnibus test. The cumulative implant survival rate was assessed using the Kaplan-Meier analysis, and the results were presented with a life table analysis. The effect of the different variables (sex, reason for zygomatic implant, number of zygomatic and conventional implants, loading, prosthesis type, and zygomatic implant location) on implant survival was evaluated using the Fisher exact test, given the low incidence of failures in each subgroup. The implant was the unit of analysis. $P = .05$ was considered

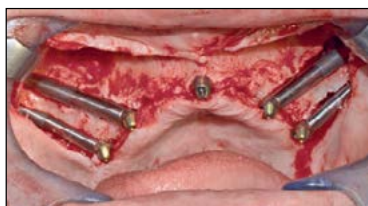

Fig 2 Intraoperative image of a patient showing zygomatic implants and an additional conventional implant in position. The original design of the implant, which has an unthreaded body with a 12.5-mm sharp threaded apical end for obtaining maximum retention to the zygomatic bone, can be seen clearly in the image.

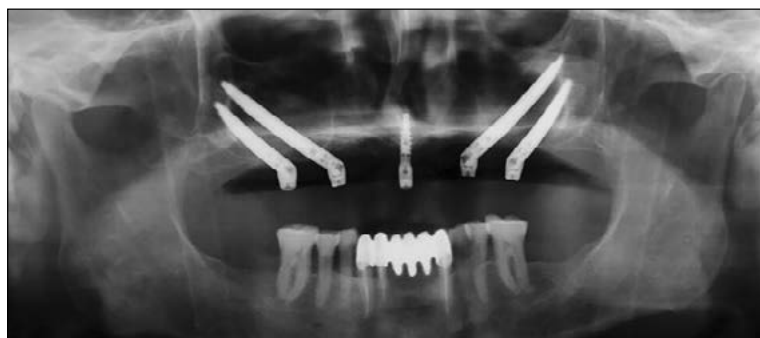


Fig 3 Postoperative panoramic radiograph of the same patient.

Table 1 Life Table Analysis

	Implants at risk	Lost to follow-up	Failed implants	Implant survival %	CSR%
0–12 mo	261	51	4	98.47	98.47
12–24 mo	206	39	1	99.51	97.99
24–36 mo	166	30	0	100.0	97.99
36–48 mo	136	88	0	100.0	97.99
48–60 mo	48	28	0	100.0	97.99
60–72 mo	20	20	0	100.0	97.99

CSR = cumulative implant survival rate; mo = months.

as the significance threshold. Statistical analysis was performed using GraphPad Prism 5.03 (GraphPad Software).

RESULTS

The study population was composed of patients aged from 21 to 76 years (mean: 58.2 years; SD: 9.28) who had at least one zygomatic implant placed between January 2014 and January 2020. The intraoperative view and postoperative panoramic radiograph of a representative case can be seen in Figs 2 and 3.

In the present study, the overall implant survival rate was 98.08%. The cumulative implant survival rate according to Kaplan-Meier analysis was 97.99%. Table 1 shows the life table analysis for the zygomatic implants, up to the 6-year follow-up. Detailed data concerning sex, reason for zygomatic implant, number of zygomatic and conventional implants, loading, prosthesis type, and zygomatic implant location are listed in Table 2. No statistically significant difference in implant survival rate was found among the groups for any of the factors evaluated. The significance resulting for the number of zygomatic implants placed is not relevant, as there were very few patients with an odd number

of zygomatic implants. Definitive or provisional prostheses were delivered on the same day of surgery, and all the patients benefited from improvements in their quality of life following surgery. There was one intraoperative complication (fracture of the zygomatic bone). Five implants were lost in four patients (2 in the first week, 1 in 3 months; the other 2 implants were lost after 11 and 19 months due to occlusal overload caused by heavy bruxism). No sinusitis and no peri-implant mucositis were seen in any of the patients. Eleven postoperative complications developed in 7 patients: 3 oroantral sinus communications, 1 cutaneous fistula, 1 abscess around zygomatic bone, 1 infection around the apical part of the zygomatic implant (due to apical overinstrumentation of the implant site), 1 permanent paresthesia, 3 temporary neurosensory deficits (3 hypoesthesia), and 1 fracture of the abutment screw.

DISCUSSION

Zygomatic implants are currently one of the outstanding popular options in which the stable retention of the prosthesis can be achieved by the insertion of two to four implants with reduced costs and time for the patient.^{9,10} The classical approach for zygomatic implant

Table 2 Implant Success Rates for Comparison of Different Characteristics

Patient	Characteristics	Failed implants/Total no. of implants	Success %	P value*
Sex	Male	1/119	99.1	.20
	Female	4/142	97.1	
Reason for ZI	Severe atrophic maxilla	1/160	99.3	.18
	Ectodermal dysplasia	0/8	100	
	Previous implant failure	4/93	95.6	
Antagonist dentition	Total removable prosthesis with bar	0/4	100	NA
	Fixed/natural teeth	5/239	97.9	
	Partial removable prosthesis	0/8	100	
	Total removable prosthesis	0/10	100	
No. of ZI + I	1 ZI + 1 I	1/9	88.8	.002
	1 ZI + 4 I	0/1	100	
	Total result for 1 ZI	1/10	90	
	2 ZI + 2 I	0/10	100	
	2 ZI + 3 I	0/12	100	
	2 ZI + 4 I	1/52	98	
	Total result for 2 ZI	1/74	98.6	
	3 ZI	2/3	33.3	
	3 ZI + 1 I	0/3	100	
	3 ZI + 2 I	0/3	100	
	Total result for 3 ZI	2/9	77.8	
	4 ZI	1/92	98.9	
	4 ZI + 1 I	0/64	100	
	4 ZI + 2 I	0/4	100	
	4 ZI + 2 I	0/8	100	
	Total result for 4 ZI	1/168	99.4	
Loading	Immediate	5/227	97.7	.49
	Delayed	0/34	100	
ZI location	13 or 23 (canine)	1/89	98.8	.32
	16 or 26 (first molar)	4/172	97.6	
Type of prosthesis	Removable prosthesis with bar	0/5	100	NA
	Toronto	3/234	98.7	
	Ceramic Toronto	0/4	100	
	Total fixed resin	1/9	88.8	
	Ceramic bridge	1/6	83.3	
	Resin bridge	0/3	100	

ZI = zygomatic implant, I = conventional dental implant; NA = not applicable. *Results of Fisher exact test.

surgery introduced by Brånemark was a pioneering technique that has been used by several clinicians worldwide with successful results.^{9,17,18,24} The zygomatic implants ranging from 30 to 52.5 mm in length

are placed in the second premolar region through the palatal bone and are fixed into the zygomatic bone.^{14,20}

Since its introduction, several protocol alternatives have been specified for zygomatic implant surgery by

other authors with variations. The sinus slot technique was the first to be introduced as a safer option.²⁵ In this technique, a lateral guide window is made directly through the buttress wall of the maxilla, which allows a direct view to the base of the zygomatic bone and implant position. In comparison with the classical protocol, the dissection used is narrower and less than half the amount of implant is exposed, which allows a greater bone-to-implant interface and more buccal position of the implant and results in better alignment with the definitive prosthesis.^{20,25} Boyes-Varley et al later criticized this technique due to the lack of direct visualization of the entrance of the implant into the zygomatic bone, which is crucial to minimize complications.¹⁸

Another alternative to the classical protocol is the extrasinus technique.²⁶ In this approach, most of the implants are placed externally to the maxillary sinus, and anchorage is obtained through the zygomatic bone, which makes this technique an alternative for all types of atrophic maxilla patients. With the use of the extrasinus technique, the need for maxillary antrostomy or the creation of a slot is eliminated, which results in improved direct visualization.²⁰ The emergence of the zygomatic implant is on the alveolar crest, which permits better biomechanics for prosthesis design. This technique also offers the advantages of fewer surgical steps, reduced surgical time, and a shorter cantilever, and it is less invasive than the other methods.^{20,27}

The extrasinus technique uses a one-stage surgical approach, thus reducing the risk of peri-implantitis and mucositis, which is of paramount importance in cases with a two-stage protocol in implant dentistry (the two-stage implant dentistry approach includes two separate surgeries, one for bone augmentation and another for implant insertion).^{28,29} The technique used in the present study, which is a technical modification of the extrasinus protocol, implies the use of a special kit designed for zygomatic implant surgery (Fig 4). This kit is composed of a round diamond bur, three diamond cylindrical body burs with nonworking tips and different levels of grits (fine, medium, coarse), a depth indicator, and a sequence of drills (2.5 cm long and 2 to 3.2 mm in diameter). The zygomatic implant that was used has an unthreaded long body ending with a particularly aggressive threaded 12.5-mm apical segment. The zygomatic site preparation and implant has a complete extrasinus path for preserving the sinus membrane and avoiding any postsurgical sinus sequelae. In addition to the optimal position of the implant, an ideal emergence of the implant on the alveolar crest is provided with the use of angled multiunit abutments from 17 to 60 degrees.

In zygomatic implants, the prosthesis plays a key role in success. In the present study, three failed implants were lost due to inappropriate prostheses for




Fig 4 Surgical kit composed of a set of drills for zygomatic implant site preparation. In the lower part of the image, a support guide system for zygomatic guided surgery is visible.

distribution of forces on the zygomatic implants. In one patient, two zygomatic implants were lost due to deep peri-implantitis (in this study, mucositis was considered to be a minor infection of the mucosal soft tissue, while oroantral fistula was considered to be the communication between the oral cavity and the maxillary sinus, and deep peri-implantitis represented a serious infection including soft and hard tissues around implants). Such peri-implantitis was caused by the overloading of the implants due to the incorrect positioning of the definitive prosthesis and poor oral hygiene of the patient, who did not come to the follow-ups. In particular, in patients with heavy bruxism, special care should be given to the prosthetic planning in order to distribute the forces equally on the supporting implants. In the present study, the other zygomatic implant was lost in a patient that presented heavy bruxism. The overloading of the forces by the prosthesis on the zygomatic implant from bruxism resulted in the loss of the implant. In more detail, in one of these bruxist patients, there was clear clinical mobility with evidence of disintegration of the apical part of the implant, which was removed with an additional surgical intervention. This patient had received four zygomatic implants, and as a solution, the definitive prosthesis was successfully adjusted to three zygomatic implants.

The postoperative complications seen in seven patients were treated and solved by additional interventions with success. Oroantral communications (oral cavity and maxillary sinus communications) of the three patients were treated by additional surgical operations with the use of local anesthesia. For this purpose, a Bichat fat pad flap was used to cover the unthreaded part of the zygomatic implant. The mucoperiosteal flap

extending over the Bichat fat pad was sutured over, in order to cover and securely close the previous oroantral sinus communication.

In cases of active sinusitis, an additional surgery was done under general anesthesia with a simultaneous functional endoscopic sinus surgery. In the present study, the cutaneous fistula was treated by a two-stage surgical approach. The first surgery was done under general anesthesia. Functional endoscopic sinus surgery, fistulectomy, and simultaneous lipofilling were performed at this stage. After 6 months, another lipofilling intervention under local anesthesia was done in order to adjust some remaining esthetic imperfections.³⁰ Another complication seen in this study was zygomatic bone periostitis, due to the overpreparation of the zygomatic implant site by the final drill, which was inserted too deeply over the zygomatic cortical bone. Consequently, the zygomatic implant was inserted too deeply and the apex was located 1.5 mm over the zygomatic cortical bone. In this case, the periostitis was treated successfully by cutting the apex of the zygomatic implant under general anesthesia.

CONCLUSIONS

Oral rehabilitation of the maxilla with zygomatic implants significantly shortens the time of rehabilitation with a reduction of adverse effects and complications. However, the placement of zygomatic implants is a major surgical procedure that has risks because of the surrounding anatomical structures and should be performed in selected patients. Additionally, surgical and prosthetic planning experience is highly required in order to overcome the possible complications.

According to the data obtained from this study, insertion of zygomatic implants with a technical modification of the extrasinus protocol is an effective and safe alternative to conventional protocols in the literature with a high success rate and few complications, especially in patients with an extremely atrophic posterior maxilla.

ACKNOWLEDGMENTS

The authors declare no potential conflicts of interest with respect to the authorship and/or publication of this article.

REFERENCES

1. Stiévenart M, Malevez C. Rehabilitation of totally atrophied maxilla by means of four zygomatic implants and fixed prosthesis: A 6-40-month follow up. *Int J Oral Maxillofac Surg* 2010;39:358–363.

2. Albrektsson T, Brånemark P-I, Hansson HA, Lindström J. Osseointegrated titanium implants: Requirements for ensuring a long-lasting, direct bone-to-implant anchorage in man. *Acta Orthop Scand* 1981;52:155–170.
3. Misch CE, Hahn J, Judy KW, et al. Workshop guidelines on immediate loading in implant dentistry. *J Oral Implantol* 2004;30:283–288.
4. Aparicio C, Perales P, Rangert B. Tilted implants as an alternative to maxillary sinus grafting: A clinical, radiologic, and periosteal study. *Clinic Implants Dent Relat Res* 2001;3:39–49.
5. Brånemark PI, Gröndahl K, Öhrnell LO, et al. Zygoma fixture in the management of advanced atrophy of the maxilla: Technique and long-term results. *Scand J Plast Reconstr Surg Hand Surg* 2004;38:70–85.
6. Brånemark PI. Surgery and fixture installation. In: *Zygomatic Fixture Clinical Procedures*. 1st ed. Gothenburg, Sweden: Nobel Biocare AB, 1998.
7. Nkenke E, Hahn M, Lell M, et al. Anatomic site evaluation of the zygomatic bone for dental implant placement. *Clin Oral Implants Res* 2003;14:72–79.
8. Davo R, Malevez C, Rojas J. Immediate function in the atrophic maxilla using zygoma implants: A preliminary study. *J Prosthet Dent* 2007;97(suppl):s44–s51.
9. Becktor JP, Isaksson S, Abrahamsson P, Sennerby L. Evaluation of 31 zygomatic implants and 74 regular dental implants used in 16 patients for prosthetic reconstruction of the atrophic maxilla with cross-arch fixed bridges. *Clin Implant Dent Relat Res* 2005;7:159–165.
10. Balshi TJ, Wolfinger GJ. Treatment of congenital ectodermal dysplasia with zygomatic implants: A case report. *Int J Oral Maxillofac Implants* 2002;17:277–281.
11. Salvatori P, Mincione A, Rizzi L, et al. Maxillary resection for cancer, zygomatic implants insertion, and palatal repair as single-stage procedure: Report of three cases. *Maxillofac Plast Reconstr Surg* 2017;39:13.
12. Aparicio C, Manresa C, Francisco K, et al. The long-term use of zygomatic implants: A 10-year clinical and radiographic report. *Clinic Implant Dent Relat Res* 2014;16:447–459.
13. Aparicio C, Ouazzani W, Hatano N. The use of zygomatic implants for prosthetic rehabilitation of the severely resorbed maxilla. *Periodontol* 2000 2008;47:162–171.
14. Lombardo G, D'Agostino A, Trevisiol L, et al. Clinical, microbiologic and radiologic assessment of soft and hard tissues surrounding zygomatic implants: A retrospective study. *Oral Surg Oral Med Oral Pathol Oral Radiol* 2016;122:537–546.
15. Aparicio C, Manresa C, Francisco K, et al. Zygomatic implants: Indications, techniques and outcomes, and the zygomatic success code. *Periodontol* 2000 2014;66:41–58.
16. Hirsch JM, Öhrnell LO, Henry PJ, et al. A clinical evaluation of the zygoma fixture: One year of follow-up at 16 clinics. *J Oral Maxillofac Surg* 2004;62(suppl):22–29.
17. Malevez C, Abarca M, Durdu F, Daelemans P. Clinical outcome of 103 consecutive zygomatic implants: A 6–48 months follow-up study. *Clin Oral Implants Res* 2004;15:18–22.
18. Boyes-Varley JG, Howes DG, Lownie JF. The zygomatic implant protocol in the treatment of the severely resorbed maxilla. *SADJ* 2003;58:106–109, 113–114.
19. Chow J, Wat P, Hui E, Lee P, Li W. A new method to eliminate the risk of maxillary sinusitis with zygomatic implants. *Int J Oral Maxillofac Implants* 2010;25:1233–1240.
20. Chrcanovic BR, Pedrosa AR, Neto Custódio AL. Zygomatic implants: A critical review of the surgical techniques. *Oral Maxillofac Surg* 2013;17:1–9.
21. Esposito M, Felice P, Worthington HV. Interventions for replacing missing teeth: Augmentation procedures of the maxillary sinus. *Cochrane Database Syst Rev* 2014;CD008397.
22. Grecchi F, Bianchi AE, Siervo S, Grecchi E, Lauritano D, Carinci F. A new surgical and technical approach in zygomatic implantology. *Oral Implantol (Rome)* 2017;10:197–208.
23. Cawood JI, Howell RA. A classification of the edentulous jaws. *Int J Oral Maxillofac Surg* 1988;17:232–236.
24. Bedrossian E. Rehabilitation of the edentulous maxilla with the zygoma concept: A 7-year prospective study. *Int J Oral Maxillofac Implants* 2010;25:1213–1221.

25. Stella JP, Warner MR. Sinus slot technique for simplification and improved orientation of zygomatic dental implants: A technical note. *Int J Oral Maxillofac Implants* 2000;15:889–893.
26. Aparicio C, Ouazzani W, Aparicio A, et al. Extrasinus zygomatic implants: Three-year experience from a new surgical approach for patients with pronounced buccal concavities in the edentulous maxilla. *Clin Implant Dent Relat Res* 2010;12:55–61.
27. Corvello PC, Montagner A, Batista FC, Smidt R, Shinkai RS. Length of the drilling holes of zygomatic implants inserted with the standard technique or a revised method: A comparative study in dry skulls. *J Craniomaxillofac Surg* 2011;39:119–123.
28. Chrcanovic BR, Albrektsson T, Wennerberg A. Survival and complications of zygomatic implants: An updated systematic review. *J Oral Maxillofac Surg* 2016;74:1949–1964.
29. Gargari M, Comuzzi L, Bazzato MF, et al. Treatment of peri-implantitis: Description of a technique of surgical detoxification of the implant. A prospective clinical case series with 3-year follow-up. *ORAL Implantol* 2015;8:1–11.
30. Haggerty CJ, Laughlin RM. Zygomatic implants. In: *Atlas of Operative Oral and Maxillofacial Surgery*, ed 1. Oxford, UK: Wiley, 2015:42–48.



Article

Accuracy of Zygomatic Implant Placement Using a Full Digital Planning and Custom-Made Bone-Supported Guide: A Retrospective Observational Cohort Study

Francesco Gallo ¹, Francesco Zingari ², Alessandro Bolzoni ³ , Selene Barone ^{4,*} and Amerigo Giudice ⁴

¹ Istituto Stomatologico Italiano, Via Pace, 21, 20161 Milano, Italy

² Ospedale Galeazzi-Sant'Ambrogio, Via Belgioioso 173, 20161 Milano, Italy

³ Private Practice, Via Francesco Sforza, 35, 20123 Milano, Italy

⁴ Unit of Oral Surgery and Pathology, Department of Health Sciences, Magna Graecia University of Catanzaro, Viale Europa, 88100 Catanzaro, Italy

* Correspondence: selene.barone@unicz.it

Abstract: The aim of the study was to evaluate the accuracy of zygomatic implant placement using customized bone-supported laser-sintered titanium templates. Pre-surgical computed tomography (CT) scans allowed to develop the ideal virtual planning for each patient. Direct metal laser-sintering was used to create the surgical guides for the implant placement. Post-operative CT scans were taken 6 months after surgery to assess any differences between the planned and placed zygomatic implants. Qualitative and quantitative three-dimensional analyses were performed with the software Slicer3D, recording linear and angular displacements after the surface registration of the planned and placed models of each implant. A total of 59 zygomatic implants were analyzed. Apical displacement showed a mean movement of 0.57 ± 0.49 mm on the X-axis, 1.1 ± 0.6 mm on the Y-axis, and 1.15 ± 0.69 mm on the Z-axis for the anterior implant, with a linear displacement of 0.51 ± 0.51 mm on the X-axis, 1.48 ± 0.9 mm on the Y-axis, and 1.34 ± 0.9 mm on the Z-axis for the posterior implant. The basal displacement showed a mean movement of 0.33 ± 0.25 mm on the X-axis, 0.66 ± 0.47 mm on the Y-axis, and 0.58 ± 0.4 mm on the Z-axis for the anterior implant, with a linear displacement of 0.39 ± 0.43 mm on the X-axis, 0.42 ± 0.35 mm on the Y-axis, and 0.66 ± 0.4 mm on the Z-axis for the posterior implant. The angular displacements recorded significant differences between the anterior implants (yaw: $0.56 \pm 0.46^\circ$; pitch: $0.52 \pm 0.45^\circ$; roll: $0.57 \pm 0.44^\circ$) and posterior implants (yaw: $1.3 \pm 0.8^\circ$; pitch: $1.3 \pm 0.78^\circ$; roll: $1.28 \pm 1.1^\circ$) ($p < 0.05$). Fully guided surgery showed good accuracy for zygomatic implant placement and it should be considered in the decision-making process.

Keywords: zygomatic implants; accuracy; data; computer-assisted surgery; maxillary atrophy; guided zygomatic implant surgery; denture; implant-supported



Citation: Gallo, F.; Zingari, F.; Bolzoni, A.; Barone, S.; Giudice, A. Accuracy of Zygomatic Implant Placement Using a Full Digital Planning and Custom-Made Bone-Supported Guide: A Retrospective Observational Cohort Study. *Dent. J.* **2023**, *11*, 123. <https://doi.org/10.3390/dj11050123>

Academic Editor: Paolo Pesce

Received: 27 February 2023

Revised: 25 April 2023

Accepted: 28 April 2023

Published: 4 May 2023



Copyright: © 2023 by the authors. Licensee MDPI, Basel, Switzerland. This article is an open access article distributed under the terms and conditions of the Creative Commons Attribution (CC BY) license (<https://creativecommons.org/licenses/by/4.0/>).

1. Introduction

The generalized resorption of the alveolar process can produce severe resorption at the maxillary and mandibular bones, and in some cases, it may prevent the use of traditional implant treatment. Since 1989, zygomatic implants (ZI) have been used in severe maxillary atrophies as an alternative therapy to bone augmentation techniques. However, it is mandatory that the apex of this long implant is precisely positioned in the zygomatic bone.

As is widely known, in dental implant surgery, accurate three-dimensional positioning is essential to obtaining optimal results for a proper prosthetic rehabilitation [1]. In recent years, the combination of cone beam computed tomography (CBCT) and computer-aided design/computer-aided manufacturing (CAD/CAM) technology began to play an important role in the field of oral implantology [2]. This technology allows the production of

different types of static surgical guides, using 3D printing technology [3,4]. As reported in a recent review, the accuracy of implant placement with computer-guided surgery has been reported in many studies (47) of traditional implantology [5]. Deviations between the virtually planned and the placed implants might represent an aggregate of errors, from imaging through data processing to guiding the placement during surgery [6,7]. However, different authors reported that digital surgical guides can improve the accuracy of implant placement [5–9].

Zygomatic implant rehabilitation is an alternative treatment for patients with severe maxillary atrophy to avoid bone-lifting or grafting procedures [10]. These long implants are inserted in a region with limited space and visibility. The implant's apex must lie completely in the zygomatic bone both to respect many anatomical limitations and to achieve the maximum bone-implant contact [11]. Hung et al. identified the posterior superior region and the central region of the zygomatic bone as suitable areas for implant tip placement [12]. In this technique, a proper position is crucial to place the ZI without functional and aesthetic complications [13]. The accuracy of the diagnostic and planning phases and the skill and experience of the operators are key factors in this surgery [14–16].

To date, guided surgery for the conventional implant is widely accepted as high-precision surgery [17–19]. For the same reason, guided surgery for the ZI based on bone-supported drill templates appears to be useful for increasing safety and accuracy [6]. Obtaining the correct implant angulation is so crucial, especially for the multiple and contemporary ZI placements to achieve a complete restoration of the upper atrophic maxilla [20]. Discrepancies between the planned and the real implant position have become a critical point in this advanced implant surgery. Consequently, an assessment of clinical accuracy is required to determine whether guided surgery errors are clinically acceptable [21,22].

The aim of this study was to perform a three-dimensional (3D) analysis to investigate the accuracy of a novel static surgical guide applied to zygomatic implant placement using a reliable transfer guide from a planned cooperating theatre. The primary outcome was to compare the planned and the post-operative implant positions, evaluating angular discrepancies and linear deviations in all three spatial axes. No discrepancy between the planned and placed ZIs was considered as the null hypothesis.

2. Materials and Methods

2.1. Study Design

A retrospective observational cohort study was designed, following the STROBE guidelines. The medical protocol and ethics followed the Declaration of Helsinki to promote and ensure respect and benefits for all enrolled subjects, protecting their health and rights. The Ethical committee of Central Region of Calabria approved the study (n° 252/15 July 2021).

2.2. Study Sample

The study sample included CBCTs of patients who underwent ZI rehabilitation, collected from July 2021 to November 2022. To use radiologic data for scientific purposes, a specific informed consent form was signed by all patients.

Selecting the database of subjects treated with dental rehabilitation supported by zygomatic implants, all patients who completed the digital protocol were considered for enrollment. The following inclusion criteria were established: (1) patients with an extreme maxillary atrophy that interfered with conventional implant placement; (2) patients treated with a full digital planning and guided surgery; (3) treatment planning with one or two (anterior implant, AI; posterior implant, PI) zygomatic implants for each side; (4) good general health.

The exclusion criteria included patients treated without pre-operative digital planning or with free-hand surgery, or patients with incomplete radiographic records.

2.3. Data Collection Method

All patients were submitted to pre-operative CBCT scans (T1) and post-surgical CBCT scans six months after surgery (T2) (slice thickness 0.5 mm; scan time 0.4 s; 8.0 mA; 105.0 kVc peak; 7.2 s; field of view: 15 × 13 mm). The indication for the post-operative CBCT focused on the necessity to objectively assess the post-surgical health of the maxillary sinus. To avoid errors due to an inadequate number of teeth, for some patients a stereolithographic (SLA) radiographic template with radiopaque fiducial markers was designed and fabricated according to the plate. Six fiducial markers were distributed on each side (buccal and lingual) of the radiographic template. According to the surgical objectives, pre-operative digital planning was performed for each patient using the EZplan Real Guide software (Noris Medical Ltd., Nesher, Israel) to determine the ideal position of each ZI and to design the CBCT-derived bone-assisted surgical guide (Figure 1). The EZgoma[®] guide (Noris Medical Ltd., Nesher, Israel) was exported as a standard triangulation language (STL) file and then fabricated with the metal 3D printing process (SLM Technology Sisma MySint 100 Titanium Degree23, Sisma SRL, Italy).

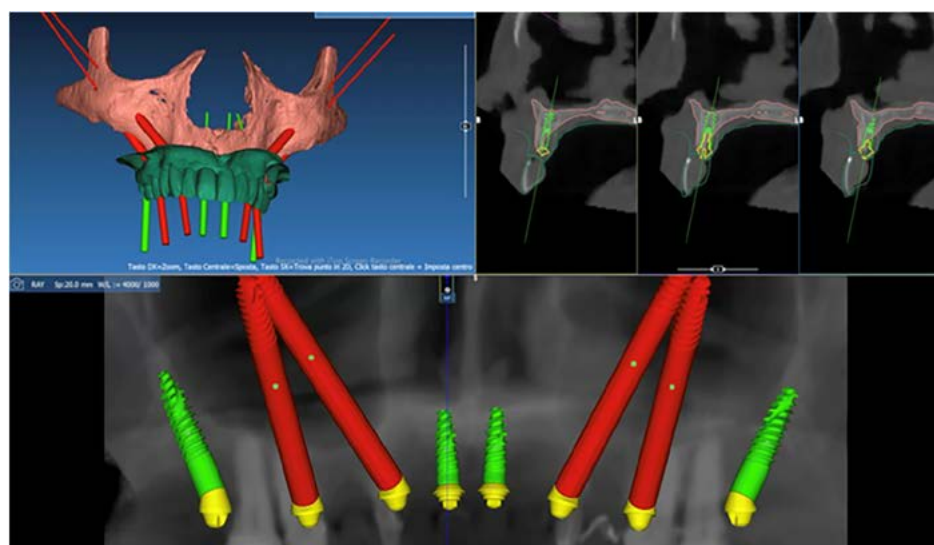


Figure 1. Pre-operative digital planning using the EZplan Real Guide software (Noris Medical Ltd., Nesher, Israel).

2.4. Surgical Procedure

The same expert surgeon (FG) performed the 3D planning and the surgical treatment for all patients. After the incision of the palatal mucosa and reflection of the soft tissues up to the level of the zygoma, and after drilling through a prefabricated slide as indicated by the pre-operative virtual surgical plan, the zygomatic fixture was placed following the manufacturer's instructions (Noris Medical Ltd., Nesher, Israel).

During installation, different drills were used, starting with a circular cutter, then switching to a 2 mm-diameter drill, continuing with a 2.9 mm drill and ending with a 3.5 mm-diameter drill that was 45 mm in length to allow the insertion of a 45 mm zygomatic implant. This specific zygomatic fixture had two diameters on the same fixture: 3.9 mm at the top and 4.5 mm at the level of the upper jaw. The surgery minimally involved the maxillary sinus. The drilling was performed with a small sinus cleft in the outer cortex of the sinus. This procedure is commonly performed for the installation of extra-sinus zygomatic implants (Figure 2A–C).

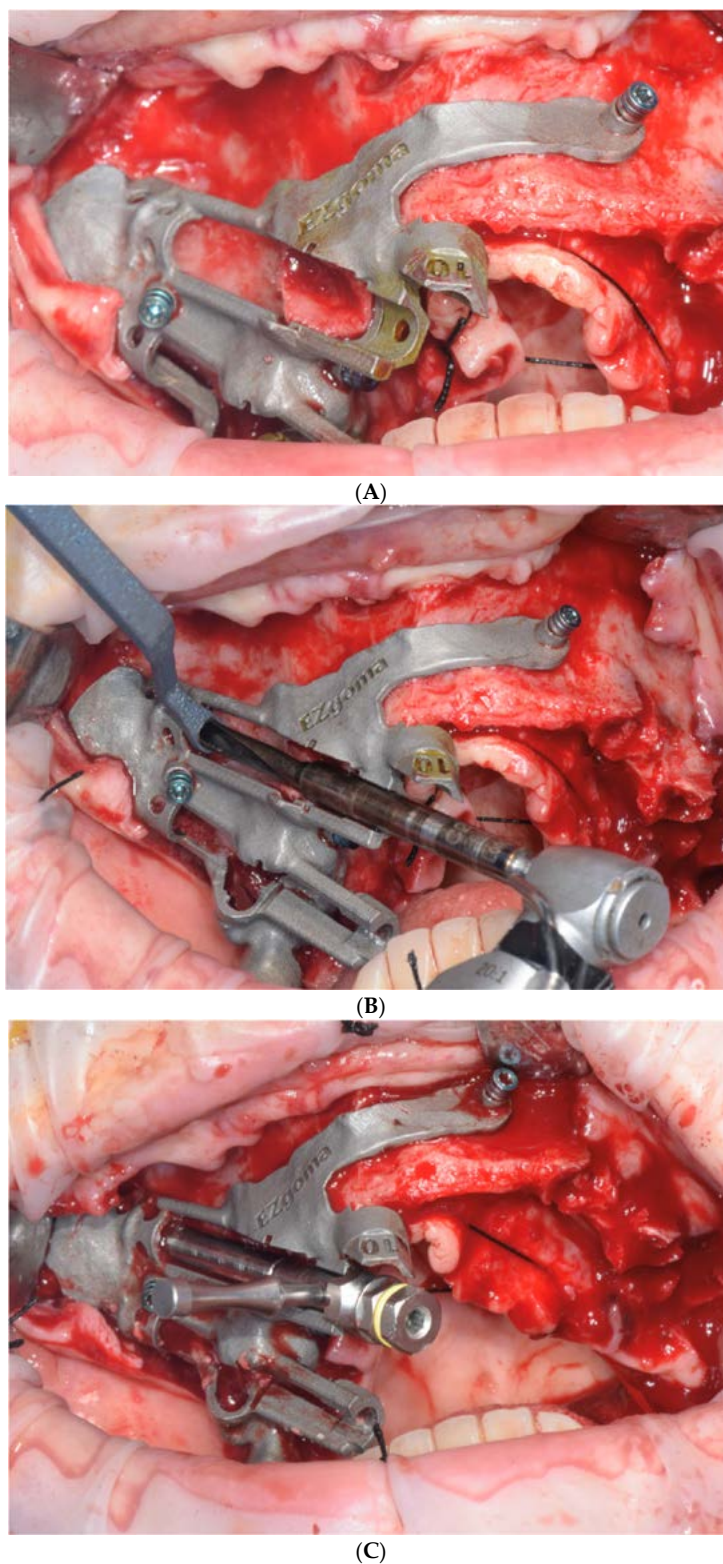


Figure 2. (A) Full thickness flap and fixation of EZgoma[®] guide; (B) Implant site preparation with dedicated drills for the zygomatic fixture; (C) The zygomatic implant was screwed in place by a dedicated mounter.

2.5. Comparative 3D Analysis

The resulting STL files of the planned ZI were exported for the analysis. The post-operative CBCT was processed, and a tissue density segmentation was performed to isolate the ZI from the surrounding bone using the ITK-SNAP software (version 3.8.0; <http://www.itksnap.org>).

The morphometric analysis was conducted on the 3DSlicer software (version 4.13.0; <http://www.slicer.org>) to compare digitally planned and post-surgical 3D reconstructions of the ZI. Using the “Model Maker” tool, the 3D surface models of each segmentation were developed. Using the “EasyClip” tool, the models of the planned and placed ZIs were cut, dividing the right and left side. The surface registration of the planned and placed ZI models was performed to superimpose the models before the following analyses.

2.6. Qualitative Analysis

Using the “Model-to-Model Distance” and “Shape Population Viewer” tools, colormaps were created to visualize any displacement between the digitally planned and T2 models. The absence of clinical surgical displacement (0 to 1 mm) is indicated by green.

2.7. Quantitative Analysis

Quantitative analysis was performed by an independent operator (SB). The examiner repeated the measurements after 2 weeks, and an intra-reliability value of 0.93 was recorded. The “Mesh Statistics” tool was used to quantify the mean difference between the surface meshes of the digitally planned and T2 models. Additionally, landmark-based quantitative assessments were obtained by the “Q3DC” tool. Linear deviations (in millimeters, mm) between digitally planned and T2 models were calculated in the three spatial axes, placing two points on the 3D models of each implant: the center of the apical surface (A) and the center of the basal surface (B). Angular deviations (degrees, °) between the long axis of digitally planned and T2 models were recorded.

2.8. Study Variables and Outcomes

The primary outcome variable was the displacement between the planned and post-surgical ZI models. The following target deviations were defined and calculated (Figure 3):

- An operator-independent calculation recorded the mean displacement between the planned and T2 ZIs comparing the 3D surface meshes.
- Linear differences at the implant’s apex and base were recorded in anteroposterior (X-axis), upper–lower (Y-axis), and medio-lateral (Z-axis) directions in mm.
- The angular deviation between the planned and T2 ZIs was determined, calculating yaw, pitch, and roll of the long axis of each implant (°).

Other study variables recorded: patients’ age and gender, and number of placed implants.

2.9. Statistical Analysis

The database was created using a dedicated Excel file (Microsoft, Redmond, WA, USA). Statistical analysis was performed using the software STATA (STATA 11, StataCorp, College Station, TX, USA).

Descriptive statistics recorded mean and standard deviation for continuous quantitative variables, absolute and relative frequencies for categorical data. Box plots were used to estimate data outliers.

To compare the planned and post-surgical implants, the analysis of variance was performed, using the two-tailed Student *t*-test for normal distributions and Wilcoxon test for asymmetrical distributions. The Shapiro–Wilk test allowed an evaluation of the type of distribution for each variable. The level of significance was set at $\alpha = 0.05$.

A power analysis was finally performed to guarantee at least a level of 80% (effect size 0.3; $\alpha = 0.05$; sample size = 59).

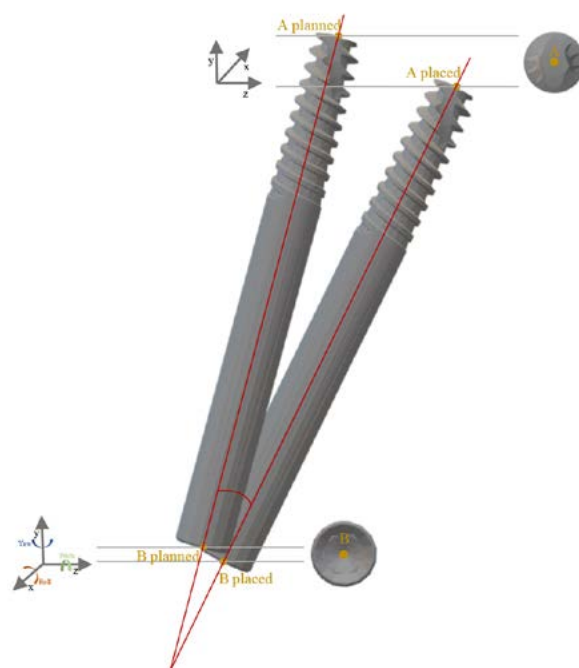


Figure 3. Measurement of deviation between planned and placed implants.

3. Results

Nineteen patients were included in the study and a total of 59 implants were examined. Details of the study sample are reported in Table 1.

Table 1. Descriptive statistics of the study sample.

Demographic Variables	Study Sample
Patients	19
Implants	59
Sex	
Female (%)	11 (57.9)
Age (years)	61 ± 3
Number of placed implants for each patient (%)	
2	6 (31.5)
3	1 (5.3)
4	12 (63.2)

In all cases, implant placement was performed using a bone-supported surgical guide that showed a stable fit with no need of bone adjustments. To fix the surgical guide, metal screws were inserted in all templates. No lesion of the surgical template nor bone fractures occurred during the surgeries.

All patients were rehabilitated with almost one zygomatic implant placement. Most of them received four ZIs (63.2%). No implants were lost, indicating a survival rate of 100% at 6 months follow-up.

3.1. Qualitative Analysis

Qualitative analysis recorded semitransparent overlays of the placed and planned zygomatic implants (Figure 4).

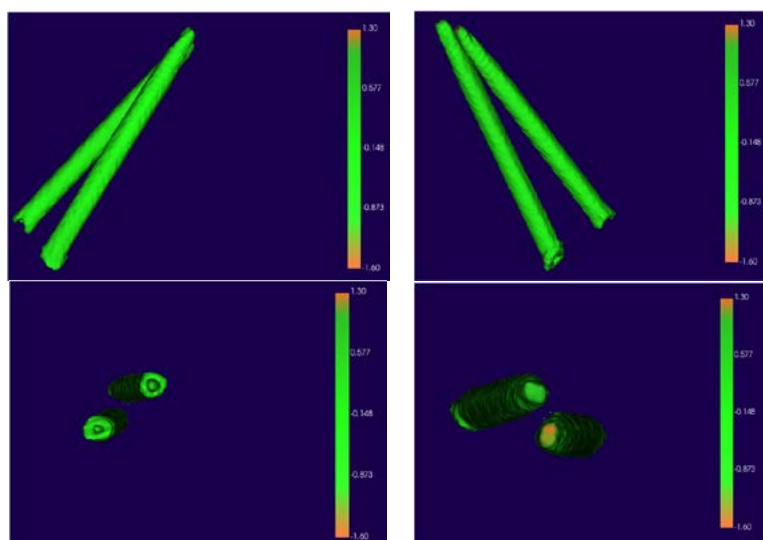


Figure 4. Automated colormaps generated by the software. Different visualizations were recorded: anterior view; posterior view; implant base; implant apex.

3.2. Quantitative Analysis

Descriptive statistics of linear implant displacements are reported in Table 2.

Table 2. Linear measurements of planned and placed implants.

	Min	Q1	Q2	Q3	Max	Mean	SD
Surface displacement							
Right	0.042	0.2	0.26	0.31	0.48	0.26	0.12
Left	0.014	0.15	0.23	0.3	0.49	0.22	0.15
X-axis							
A_R_AI	0.03	0.25	0.41	0.58	1.96	0.52	0.51
A_R_PI	0.013	0.21	0.37	0.58	2.5	0.58	0.7
B_R_AI	0.01	0.06	0.3	0.57	0.81	0.34	0.26
B_R_PI	0.04	0.09	0.22	0.52	0.63	0.31	0.23
A_L_AI	0.06	0.18	0.63	0.84	1.57	0.63	0.48
A_L_PI	0.14	0.24	0.39	0.59	1.04	0.45	0.27
B_L_AI	0.008	0.15	0.21	0.45	0.9	0.32	0.25
B_L_PI	0.07	0.17	0.29	0.47	2.1	0.47	0.56
Y-axis							
A_R_AI	0.21	0.54	1.04	1.68	2.2	1.12	0.63
A_R_PI	0.63	1.26	1.9	2.04	3.35	1.78	0.8
B_R_AI	0.006	0.2	0.46	0.75	1.7	0.54	0.46
B_R_PI	0.06	0.16	0.43	0.68	1.2	0.47	0.38
A_L_AI	0.27	0.58	0.97	1.45	2.34	1.04	0.57
A_L_PI	0.07	0.73	0.84	1.64	3	1.2	0.95
B_L_AI	0.036	0.44	0.77	0.94	1.69	0.78	0.48
B_L_PI	0.08	0.12	0.29	0.5	1.05	0.38	0.34
Z-axis							
A_R_AI	0.02	0.65	1.05	1.63	2.6	1.14	0.76
A_R_PI	0.32	0.9	1.55	1.98	4.1	1.63	1.12
B_R_AI	0.02	0.26	0.5	0.57	1.09	0.48	0.32
B_R_PI	0.23	0.38	0.62	0.9	1.5	0.72	0.43
A_L_AI	0.1	0.7	0.99	1.6	2.7	1.17	0.65
A_L_PI	0.14	0.7	0.93	1.36	2.36	1.07	0.6
B_L_AI	0.02	0.36	0.7	0.89	1.89	0.68	0.45
B_L_PI	0.08	0.23	0.66	0.8	1.22	0.62	0.38

Table 2. Cont.

	Min	Q1	Q2	Q3	Max	Mean	SD
3D distance							
A_R_AI	0.46	1.14	1.65	2.3	3.66	1.78	0.92
A_R_PI	0.96	2.16	2.44	3.28	4.62	2.67	1.16
B_R_AI	0.23	0.6	0.79	1.13	2.03	0.89	0.47
B_R_PI	0.3	0.62	0.8	1.25	1.98	0.97	0.5
A_L_AI	0.56	1.2	1.56	2.2	3.83	1.75	0.87
A_L_PI	1	1.2	1.48	2.4	3.6	1.84	0.85
B_L_AI	0.31	0.88	1.03	1.3	2.65	1.15	0.59
B_L_PI	0.1	0.57	0.8	1.14	2.4	0.95	0.63

R = right; L = left; A = apical; B = base; AI = anterior implant; PI = posterior implant; Q1 = first quartile, 25th percentile; Q2 = second quartile, 50th percentile; Q3 = third quartile, 75th percentile.

The surface displacement at T2 compared to the planned model showed a mean difference of 0.26 ± 0.12 mm on the right side and 0.22 ± 0.15 mm on the left side ($p = 0.16$).

According to the different coordinates, on X-axis the apical displacement showed a mean movement of 0.57 ± 0.49 mm and 0.51 ± 0.51 mm for the AI and PI, respectively ($p > 0.05$). The upper-lower component (Y-axis) showed an upper position of the AI at T2 with a mean discrepancy of 1.1 ± 0.6 mm, while a lower position (1.48 ± 0.9 mm) was recorded for the Pis ($p > 0.05$). On the Z-axis, a lateral displacement occurred at T2 compared to the planned models, both for the Ais (1.15 ± 0.69 mm) and Pis (1.34 ± 0.9 mm) ($p > 0.05$).

Basal displacement of the Ais and Pis showed a mean anterior displacement on the X-axis of 0.33 ± 0.25 mm and of 0.39 ± 0.43 mm, respectively ($p > 0.05$). Comparing the T2 models with respect to the planned models in the upper-lower component (Y-axis), a significative difference between the Ais (0.66 ± 0.47 mm) and Pis (0.42 ± 0.35 mm) was recorded ($p = 0.037$). On the Z-axis, a lateral displacement occurred both for the Ais (0.58 ± 0.4 mm) and Pis (0.66 ± 0.4 mm) ($p > 0.05$).

Table 3 reports the angular displacement of implant orientation between the planned and placed models. A significative difference was recorded comparing the mean discrepancy between the Ais (yaw: $0.56 \pm 0.46^\circ$; pitch: $0.52 \pm 0.45^\circ$; roll: $0.57 \pm 0.44^\circ$) and Pis (yaw: $1.3 \pm 0.8^\circ$; pitch: $1.3 \pm 0.78^\circ$; roll: $1.28 \pm 1.1^\circ$) in all directions of rotation ($p < 0.05$).

Table 3. Angular measurements of planned and placed implants.

	Min	Q1	Q2	Q3	Max	Mean	SD
Yaw							
R_AI	0.12	0.27	0.33	0.74	1.76	0.56	0.45
R_PI	0.62	1.1	1.28	1.8	2.58	1.45	0.6
L_AI	0.12	0.23	0.4	0.8	1.9	0.56	0.49
L_PI	0.2	0.42	0.96	1.95	2.83	1.22	0.98
Pitch							
R_AI	0.03	0.19	0.21	0.46	1.99	0.43	0.5
R_PI	0.12	0.64	1.04	1.73	2.24	1.18	0.7
L_AI	0.12	0.36	0.5	0.83	1.45	0.61	0.4
L_PI	0.27	0.89	1.4	2.35	2.65	1.49	0.84
Roll							
R_AI	0.02	0.16	0.35	0.78	1.46	0.53	0.49
R_PI	0.08	0.5	0.83	2.67	3.28	1.41	1.23
L_AI	0.16	0.37	0.44	0.64	1.6	0.6	0.4
L_PI	0.06	0.68	1.02	1.3	4.18	1.16	1.07

R = right; L = left; AI = anterior implant; PI = posterior implant; Q1 = first quartile, 25th percentile; Q2 = second quartile, 50th percentile; Q3 = third quartile, 75th percentile.

4. Discussion

The purpose of this study was to evaluate the accuracy of a guided surgical protocol for ZI placement by analyzing data obtained from the superimposition between the pre-operative digital planning and the post-operative CBCT scan of the treated patients. Currently, many authors consider guided surgery to increase surgical accuracy and reduce the risks of implant placement [3,5]. The primary goal is to minimize neurological issues and preserve critical anatomical features such as the orbit. To date, one of the most used procedures in ZI placement is the extra-sinus insertion, which minimizes the involvement of the maxillary sinus respiratory space and eliminates the need for membrane elevation. Additionally, thanks to this approach, the implant head is positioned at or near the top of the remaining crest, in a more favorable prosthetic position [14,15]. Pre-operative radiological measurements between anatomical landmarks can be inaccurate, posing a danger, particularly in the case of blind surgery [15]. In order to increase the accuracy in the comparison between the virtual planning with the post-operative outcomes, a 3D imaging analysis was implemented. Post-surgical CBCT allowed for a follow-up of the post-operative health of the maxillary sinus, also representing the best radiological exam to assess the implant position [16]. To our knowledge, this is one of the first in vivo studies analyzing the accuracy of ZI placement through bone-supported templates with a 3D assessment.

Our study included 59 ZIs, most of them in a quad approach with the guidance of a bone-supported guide. As already specified, in this technique, a bone-supported surgical guide must be placed after reflecting a full-thickness flap. Compared to non-guided surgery, in the case of the ZI procedure, there is no need for more invasive maneuvers to be placed in the surgical guide. Indeed, the presence of fixation screws may help in the precision and stabilization of the template; however, due to the need for a wide normal exposure of the zygoma, the procedure may be comparable to traditional non-guided surgery.

Following the initial hypothesis, the results of this study confirmed a negligible difference between the virtually planned and the post-operative placed implants. The primary findings emphasized the accuracy of this bone support device consisting of a single sintered titanium template placed during all the surgical procedures. The qualitative and quantitative outcomes showed a significant overlapping of the post-operative implants compared to the planned ones. The surface displacement recorded a mean difference of 0.26 ± 0.12 mm on the right-side implants and 0.22 ± 0.15 mm on the left side. Analyzing the quantitative discrepancies on the three spatial axes, the mean lateral deviation was under 0.50 mm at the apex and the base of the anterior implants. Although the posterior implants showed a slightly higher mean lateral displacement, this data, even if not significant, could be due to the greater difficulty in inserting the posterior implant in the limited space and mouth opening. The data recorded in the study showed very close linear distance values between the guided zygomatic surgery and the standard guided implant surgery.

Analyzing the accuracy of the virtual surgical planning in zygomatic implant insertion, Xing Gao, B. et al. reported a significant difference between the planned and the final implant position with a free-hand traditional surgery, especially in the angular position [23]. The study demonstrated how the transfer error from the pre-operative planning to the surgical field is a critical factor and surgical experience is still mandatory. In traditional implant surgery, the acceptable transfer error ranges from 0.3 to 0.6 mm. Naitoh et al. found that transferring the VPS to surgery using conventional teeth-supported guides resulted in an angular deviation between the planned and real position ranging from 0.5° to 14° with an average of 5.0° [24].

In the case of ZI surgery, the literature described different results, probably due to the complexity of the procedure and the length of the implants. The mean difference reported by Van Steenberghe et al. was 2.0–2.5 mm for linear discrepancies and 3 degrees for angular displacements [6]. In the systematic review by Van Assche and colleagues, the mean deviations at entry, at the apex and the angular deviation were $0.73 \text{ mm} \pm 0.16$, $0.98 \text{ mm} \pm 0.20$ and $3.08^\circ \pm 0.37$, respectively [25].

More recently, Grecchi et al. published a cadaver study testing a titanium laser-sintered bone-supported guide in zygomatic and pterygoid implant surgery. The authors tested its accuracy on a total of 40 zygomatic and 20 pterygoid implants. They reported that the mean deviations between the planned and the placed zygomatic and pterygoid implants were, respectively: 1.69 ± 1.12 mm and $4.15 \pm 3.53^\circ$ for the angular deviation. Linear distance deviations: 0.93 ± 1.23 mm and 1.35 ± 1.45 mm at the platform depth, 1.35 ± 0.78 mm and 1.81 ± 1.47 mm at the apical plane, and 1.07 ± 1.47 mm and 1.22 ± 1.44 mm for the apical depth [26].

The results obtained in this study are comparable with reports of traditional tooth or bone-supported guided surgery. In the case of ZI rehabilitation, few effective methods have been reported to transfer virtual planning to the surgical field. For this reason, the surgery is mostly performed conventionally, causing some discrepancies between the virtually planned and final position of the implant. Static or navigation-guided surgery may be an efficient tool to accurately transfer VSP to the surgical field.

Concerning surgical insertion guides, several studies have described different materials to produce this intraoperative device, including silicone, synthetic resin, thermoforming films, or titanium [27]. According to their elastic characteristics, the results might change, adding errors to the attained insertion depth or angulation. Tatakis et al. explored another possible cause of mistakes that produce inaccuracies in the final implant location [28]. They suggested that one potential reason might be the space that exists between the system's drill and the guiding unit of the insertion guides [28]. Their research revealed that differences between the inner and outer diameters of the blade and the guide sleeve have a direct impact on the accuracy [28]. Laederach et al. pointed out that a small gap cannot be avoided since significant mechanical frictional forces can develop [28]. The polymeric guides are usually easier to fabricate but with the disadvantage of being larger and sometimes having a mixed anchorage. On the contrary, the titanium guide is smaller and with a bone screw anchorage can precisely fit the planned position. Unlike other guides, zygomatic implant placement can also be completed without removing it, so the final exit point and angulation control are fully provided by the device [27,28]. Moreover, the proposed bone-supported titanium guide can offer the possibility to plan a guided conventional implant placement in the same guide. The results showed how an accurate definition of the implant starting point, trajectory, and exit point was achieved and ZI placement was associated with a more predictable implant position.

There are some limitations that should be considered. First, a relevant impact of surgical experience on the accuracy of implant placement is to be expected, mainly for the adequate placement of the bone-supported surgical guide. In this study, all patients had been treated by one experienced clinician. Second, this study may have been underpowered by the lack of a control group treated with free-hand surgery. Third, image error, technological error, registration, calibration error, and human error are all factors that can affect guided implant surgery [29]. The imaging model and associated imaging parameters have a significant impact on image quality. The CBCT, rather than CT, may influence the accuracy of planning ZI surgery [29]. The pixel size and slice thickness may influence the planning-related software associated with the printing algorithm within and may generate a technical error. Image importation, image reconstruction, occlusion plane definition, arch curve drawing of the prosthesis-driven implant planning, and fine implant adjustment were performed with different types of pre-operative planning software. Moreover, the use of long drills instead of short traditional ones may lead to a minimal loss of precision. However, this effect should be minimized by the titanium sintered guide compared to free-hand surgery, due to guide's specific design. In the same way, the guide may reduce the effect of a surgeon in an uncomfortable position handling rotary instruments.

5. Conclusions

The results obtained with this surgical procedure appear to be promising. The findings of this study may help clinicians in selecting a more accurate technique for placing ZIs.

This study shows that with a bone-supported guide, the surgery may achieve a high level of accuracy even in fully edentulous patients. Despite the inherent difficulties of osteotomy driving the angle formation due to the length of the zygomatic implant, the guided ZI surgery showed a minimal difference between the planned and positioned implants. Additional studies and randomized clinical trials comparing guided versus free-hand surgery are required to assess the predictability of this procedure. As a result, when the zygomatic implant is necessary, fully guided surgery should be considered in the decision-making process for the surgical approach.

Author Contributions: Conceptualization, A.G. and F.G.; methodology, A.G. and S.B.; software, S.B.; validation, A.G., F.G., F.Z., A.B. and S.B.; formal analysis, S.B.; investigation, A.G.; resources, F.G., F.Z. and A.B.; data curation, S.B.; writing—original draft preparation, A.G. and S.B.; writing—review and editing, A.G.; supervision, A.G.; project administration, A.G. and F.G. All authors have read and agreed to the published version of the manuscript.

Funding: This research received no external funding.

Institutional Review Board Statement: The study was conducted according to the guidelines of the Declaration of Helsinki and approved by the Ethical committee of Central Region of Calabria (n° 252/15 July 2021).

Informed Consent Statement: Informed consent to use the CBCTs for study, training and scientific research, was obtained from all the patients involved in the study.

Data Availability Statement: The data presented in this study are available on request from the corresponding author.

Conflicts of Interest: The authors declare no conflict of interest.

References

- Block, M.S.; Emery, R.W. Static or Dynamic Navigation for Implant Placement—Choosing the Method of Guidance. *J. Oral Maxillofac. Surg.* **2016**, *74*, 269–277. [\[CrossRef\]](#) [\[PubMed\]](#)
- Geng, W.; Liu, C.; Su, Y.; Li, J.; Zhou, Y. Accuracy of different types of computer-aided design/ computer-aided manufacturing surgical guides for dental implant placement. *Int. J. Clin. Exp. Med.* **2015**, *8*, 8442–8449. [\[PubMed\]](#)
- Varga, E., Jr.; Antal, M.; Major, L.; Kiscsatári, R.; Braunitzer, G.; Piffkó, J. Guidance means accuracy: A randomized clinical trial on freehand versus guided dental implantation. *Clin. Oral Implant. Res.* **2020**, *31*, 417–430. [\[CrossRef\]](#) [\[PubMed\]](#)
- Besimo, C.E.; Lambrecht, J.T.; Guindy, J.S. Accuracy of implant treatment planning utilizing template-guided reformatted computed tomography. *Dentomaxillofacial Radiol.* **2000**, *29*, 46–51. [\[CrossRef\]](#) [\[PubMed\]](#)
- Colombo, M.; Mangano, C.; Mijiritsky, E.; Krebs, M.; Hauschild, U.; Fortin, T. Clinical applications and effectiveness of guided implant surgery: A critical review based on randomized controlled trials. *BMC Oral Health* **2017**, *17*, 150. [\[CrossRef\]](#)
- Van Steenberghe, D. Accuracy of drilling guides for transfer from three-dimensional CT-based planning to placement of zygoma implants in human cadavers. *Clin. Oral Implant. Res.* **2023**, *14*, 131–136. [\[CrossRef\]](#)
- Chow, J. A novel device for template-guided surgery of the zygomatic implants. *Int. J. Oral Maxillofac. Surg.* **2016**, *45*, 1253–1255. [\[CrossRef\]](#)
- Birkfellner, W.; Solar, P.; Gahleitner, A.; Huber, K.; Kainberger, F.; Kettenbach, J.; Homolka, P.; Diemling, M.; Watzek, G.; Bergmann, H. In-vitro assessment of a registration protocol for image guided implant dentistry. *Clin. Oral Implant. Res.* **2001**, *12*, 69–78. [\[CrossRef\]](#)
- Ozan, O.; Turkyilmaz, I.; Ersoy, A.E.; McGlumphy, E.A.; Rosenstiel, S.F. Clinical Accuracy of 3 Different Types of Computed Tomography-Derived Stereolithographic Surgical Guides in Implant Placement. *J. Oral Maxillofac. Surg.* **2009**, *67*, 394–401. [\[CrossRef\]](#)
- Schiroli, G.; Angiero, F.; Silvestrini-Biavati, A.; Benedicenti, S. Zygomatic implant placement with flapless computer-guided surgery: A proposed clinical protocol. *J. Oral Maxillofac. Surg.* **2011**, *69*, 2979–2989. [\[CrossRef\]](#)
- Tahmaseb, A.; Wismeijer, D.; Coucke, W.; Derksen, W. Computer Technology Applications in Surgical Implant Dentistry: A Systematic Review. *Int. J. Oral Maxillofac. Implants* **2014**, *29*, 25–42.
- Hung, K.F.; Ai, Q.Y.; Fan, S.C.; Wang, F.; Huang, W.; Wu, Y.Q. Measurement of the zygomatic region for the optimal placement of quad zygomatic implants. *Clin. Implant Dent. Relat. Res.* **2017**, *19*, 841–848. [\[CrossRef\]](#)
- Chrcanovic, B.R.; Oliveira, D.R.; Custódio, A.L. Accuracy evaluation of computed tomography-derived stereolithographic surgical guides in zygomatic implant placement in human cadavers. *J. Oral Implantol.* **2010**, *36*, 345–355. [\[CrossRef\]](#)
- Cassetta, M.; Di Mambro, A.; Giansanti, M.; Stefanelli, L.V.; Cavallini, C. The intrinsic error of a stereolithographic surgical template in implant guided surgery. *Int. J. Oral Maxillofac. Surg.* **2013**, *42*, 264–275. [\[CrossRef\]](#)

15. Flügge, T.V.; Nelson, K.; Schmelzeisen, R.; Metzger, M.C. Three-dimensional plotting and printing of an implant drilling guide: Simplifying guided implant surgery. *J. Oral Maxillofac. Surg.* **2013**, *71*, 1340–1346. [\[CrossRef\]](#)
16. Pellegrino, G.; Bellini, P.; Cavallini, P.F.; Ferri, A.; Zacchino, A.; Taraschi, V.; Marchetti, C.; Consolo, U. Dynamic Navigation in Dental Implantology: The Influence of Surgical Experience on Implant Placement Accuracy and Operating Time. An in Vitro Study. *Int. J. Environ. Res. Public Health* **2020**, *17*, 2153. [\[CrossRef\]](#)
17. Salmi, M.; Paloheimo, K.S.; Tuomi, J.; Wolff, J.; Mäkitie, A. Accuracy of medical models made by additive manufacturing (rapid manufacturing). *J. Cranio-Maxillofac. Surg.* **2013**, *41*, 603–609. [\[CrossRef\]](#)
18. Lal, K.; White, G.S.; Morea, D.N.; Wright, R.F. Use of stereolithographic templates for surgical and prosthodontic implant planning and placement. Part I. The concept. *J. Prosthodont.* **2006**, *15*, 51–58. [\[CrossRef\]](#)
19. Grecchi, E.; Stefanelli, L.V.; Grecchi, F.; Grivetto, F.; Franchina, A.; Pranno, N. A novel guided zygomatic implant surgery system compared to free hand: A human cadaver study on accuracy. *J. Dent.* **2022**, *119*, 103942. [\[CrossRef\]](#)
20. Mediavilla Guzmán, A.; Riad Deglow, E.; Zubizarreta-Macho, Á.; Agustín-Panadero, R.; Hernández Montero, S. Accuracy of Computer-Aided Dynamic Navigation Compared to Computer-Aided Static Navigation for Dental Implant Placement: An In Vitro Study. *J. Clin. Med.* **2019**, *8*, 2123. [\[CrossRef\]](#)
21. D’haese, J.; Van De Velde, T.; Komiyama, A.; Hultin, M.; De Bruyn, H. Accuracy and Complications Using Computer-Designed Stereolithographic Surgical Guides for Oral Rehabilitation by Means of Dental Implants: A Review of the Literature. *Clin. Implant Dent. Relat. Res.* **2012**, *14*, 321–335. [\[CrossRef\]](#) [\[PubMed\]](#)
22. Chen, X.; Ye, M.; Lin, Y.; Wu, Y.; Wang, C. Image guided oral implantology and its application in the placement of zygoma implants. *Comput. Methods Programs Biomed.* **2009**, *93*, 162–173.
23. Xing Gao, B.; Iglesias-Velázquez, O.; GF Tresguerres, F.; Rodríguez González Cortes, A.; FTresguerres, I.; Ortega Aranegui, R.; López-Pintor, R.M.; López-Quiles, J.; Torres, J. Accuracy of digital planning in zygomatic implants. *Int. J. Implant Dent.* **2021**, *7*, 65. [\[CrossRef\]](#) [\[PubMed\]](#)
24. Naitoh, M.; Arijji, E.; Okumura, S.; Ohsaki, C.; Kurita, K.; Ishigami, T. Can implants be correctly angulated based on surgical templates used for osseointegrated dental implants? *Clin. Oral Implant. Res.* **2000**, *11*, 409–414. [\[CrossRef\]](#)
25. Van Assche, N.; Vercruyssen, M.; Coucke, W.; Teughels, W.; Jacobs, R.; Quirynen, M. Accuracy of computer-aided implant placement. *Clin. Oral Implant. Res.* **2012**, *23*, 112–123. [\[CrossRef\]](#)
26. Grecchi, F.; Stefanelli, L.V.; Grivetto, F.; Grecchi, E.; Siev, R.; Mazor, Z.; Del Fabbro, M.; Pranno, N.; Franchina, A.; Di Lucia, V.; et al. A novel guided zygomatic and pterygoid implant surgery system: A human cadaver study on accuracy. *Int. J. Environ. Res. Public Health* **2021**, *18*, 6142. [\[CrossRef\]](#)
27. Laederach, V.; Mukaddam, K.; Payer, M.; Filippi, A.; Kühl, S. Deviations of different systems for guided implant surgery. *Clin. Oral Implant. Res.* **2017**, *28*, 1147–1151. [\[CrossRef\]](#)
28. Tatakis, D.N.; Chien, H.H.; Parashis, A.O. Guided implant surgery risks and their prevention. *Periodontology 2000* **2019**, *811*, 194–208. [\[CrossRef\]](#)
29. Widmann, G.; Stoffner, R.; Bale, R. Errors and error management in image-guided craniomaxillofacial surgery. *Oral Surg. Oral Med. Oral Pathol. Oral Radiol. Endodontology*. **2009**, *107*, 701–715. [\[CrossRef\]](#)

Disclaimer/Publisher’s Note: The statements, opinions and data contained in all publications are solely those of the individual author(s) and contributor(s) and not of MDPI and/or the editor(s). MDPI and/or the editor(s) disclaim responsibility for any injury to people or property resulting from any ideas, methods, instructions or products referred to in the content.



Surface Treatment of Dental Implants



Comparison of Implant Stability Quotient of sand blasted large-grit acid etched (SLA) & biological calcium phosphate surface treated (RBM) dental implants using Resonance Frequency Analysis - A Parallel Arm Double Blinded Randomized Controlled Trial

ABSTRACT

Background: Sand blasted large-grit aluminum oxide acid etched (SLA) and biological calcium phosphate surface treated Resorbable Blast Medium (RBM) mechanism leads to wettability of surfaces of dental implants which helps in osseointegration. The present study was conducted to discern the Implant Stability Quotient (ISQ) of SLA and RBM chemically modified dental implants.

Materials & Methods: The present study was conducted on 34 patients (males- 16, females- 18) of age ranged 18-54 years. Dental implants (Tuff Noris Medical) treated with SLA (Group I) and RBM (Group II) were inserted in patients using standardized clinical protocols. Resonance Frequency Analysis (RFA) was done immediately after implant insertion, after 1 week, 2 weeks, 6 weeks, 8 weeks and 12 weeks to discern the ISQ and hence predict the implant stability.

Results: Age group 18-30 and 31-54 years had 17 patients each. There was no absolute reported case of peri-implantitis or dental implant failure. Maximum mean RFA value in Group I was 85.6 and minimum was 43.2. In group II, maximum mean RFA value was 87.4 and minimum 31.8.

Conclusion: There is fastest osseointegration in implants with RBM group than with SLE surfaces. ISQ was higher than 80 in both groups which indicate higher implant stability.

Clinical Significance: It can be observed that surface treatment of dental implants shows higher implant -bone osseointegration.

Key words: Dental implant, Osseointegration, Implant Stability Quotient.

Introduction

Dental implants are being used aggressively in world. Dental implants of numerous companies are available to us.¹ The success of any dental implant is based on its ability to show osseointegration. Various factors are responsible for survival of dental implant. It is divided into host related factors and dental implant related.² Host related factors include systemic conditions and local factors.³ Literature revealed that acid etched or sandblasted implant offer high osseointegration in comparison to machined implants. Dental implant related factors are considered more important before inserting dental implants. Chemical modified Sand blasted large-grit aluminum oxide acid etched (SLA) and biological calcium phosphate surface treated Resorbable Blast Medium (RBM) mechanism leads to wettability of surfaces of dental implants which helps in osseointegration.^{4,5} It has been seen that hydroxylation of oxide layer improves the wettability of titanium oxide surface and absorption of proteins on surface of dental implants by increasing interaction between water and implant surfaces.⁶

Resonance Frequency Analysis (RFA) is the method of checking the stability or osseointegration of dental implants. It is represented as Implant Stability Quotient (ISQ). RFA helps in judging the level of osseointegration after insertion of implant or during healing period. This guides dentist to place prosthetic part after obtaining high ISQ value.⁷ The method is done by sending magnetic pulses to a small metal rod temporarily attached to the implant. As the rod vibrates, the probe reads its resonance frequency and translates it into an ISQ value. SLA implants have similar microstructure and roughness surface.⁸ The present study was conducted in the department of Prosthodontics to determine the ISQ of SLA and RBM chemically modified dental implants.

Materials & Methods

The present study was conducted in the Mumbai, India (Aesthetic Smiles Dental Clinic). It comprised of a convenience sample of 34 patients (males- 16, females- 18) of age ranged 18-54 years who were a part of the regular pool of patients at the study setting.

All patients were informed regarding the study and written consent was obtained from all those recruited. This randomized controlled clinical trial was a parallel arm double blinded study, with the patient and the statistician unaware of the allotment.

The patients were allocated in the two arms of the trial with an allocation ratio of 1:1. Thus, each group comprised of 17 participants each who fulfilled the inclusion and exclusion criteria. Tuff Noris Dental implants (Noris Medical Pvt. Ltd) treated with SLA (Group I) and RBM (Group II) were inserted in patients using standardized clinical protocols. All implants were placed in the mandibular region (having D1/ D2 type of bone quality) to maintain uniformity. Patients without systemic diseases and edentulous area in posterior mandible were included while patients with insufficient bone height, systemic diseases and pregnant women were excluded. In all patients, bone height was, measured with intraoral radiographs and bone height above 8mm was considered. Patients suffering from Type II Diabetes Mellitus were not taken in the purview of the study. Patients with bone height < 8mm and those unwilling to give written informed consent were not considered in the study.

In all patients assessment was performed with clinical examination, intraoral radiographic examination and CT scan of the implant site.

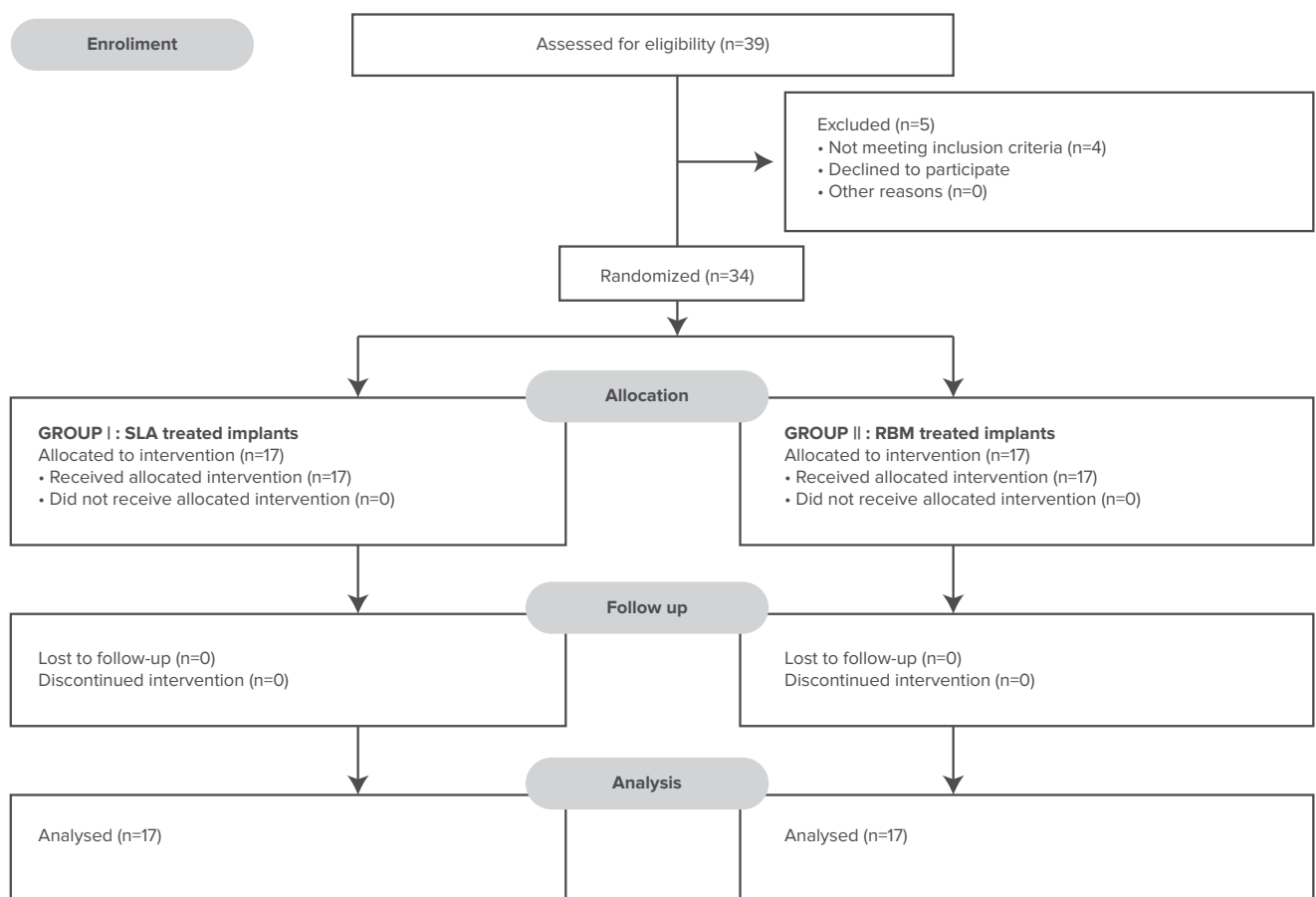
In all patients, implants with 10 mm height and 4.20 mm width were inserted. The ISQ was measured by a single standardized calibrated machine (Mega ISQ Implant Stability System, Megagen, Korea). RFA was done immediately after implant insertion, after 1 week, 2 weeks, 6 weeks, 8 weeks and 12 weeks.

Each of the readings were verified three times and the mean value was recorded during each visit. Results thus obtained were subjected to statistical analysis using SPSS Software (Version 19.0, IBM USA) That distribution of the variables were normal, as discerned by the Shapiro Wilk's test.

Parametric test of independent unpaired Student t-test was used for intergroup comparison and Repeated Measures Analysis of variance (ANOVA) followed by post-hoc Bonferroni correction was performed to compare the groups over the scheduled study period intervals.

Descriptive statistics and Chi Square test was used for association. Alpha error was set at 5% which corresponded to a p-value of less than 0.05 yielding statistically significant results.

CONSORT Flow Diagram



Results

Age group 18-30 years had 8 males and 7 females, 31-40 years had 6 males and 9 females and 41-54 years had 2 males and 2 females (Table I). The difference was non- significant ($P > 0.05$). The maximum mean RFA value in group I was 85.6 and minimum was 43.2. In group II, maximum mean RFA value was 87.4 and minimum 31.8. Graph I elucidates the RFA values of the two groups at the specified time intervals. Table II depicts the intergroup comparison between the intervention groups. There was a statistically significant difference between the RFA values recorded in the SLA and RBM groups in the first, sixth, eighth and twelfth week.

Mauchly's test of sphericity displayed a statistically significant result, pointing towards a jeopardized F-ratio value interpretation in both the groups. Hence, the Epsilon test statistic was performed to discern further departure from the degree of sphericity.

Since epsilon was >0.75 , the Huynh- Fieldt correction was applied. The multivariate statistic Wilks' Lamda yielded a statistically significant result for both the groups. (Tables III and IV).

Pairwise comparisons were performed by the repeated measures ANOVA Bonferroni correction post-hoc test. The within group differences showed statistically significant results ($P < 0.05$) (Table V). Graph II shows that torque value in group I was 34.2 and in group II was 36.4. The difference was non- significant ($P > 0.05$).

Tables

Table I: Association between Age & gender distribution of participants.

Age group (years)	Males	Females	P value
18-30	8	7	0.5
31-40	6	9	
41-54	2	2	

Chi Square test. ($p < 0.05$ indicates statistical significance)

Table II : Intergroup comparison of RFA values .

Time duration	Resonance Frequency Analysis (RFA) value		P value
	Group I (SLA)	Group II (RBM)	
Immediate post- op (0 weeks)	43.2	31.8	0.23
One Week	50.4	51.5	0.003*
Two Weeks	53.7	55.3	0.06
Six Weeks	46.5	54.6	0.001*
Eight Weeks	77.1	81.5	0.001*
Twelve Weeks	85.6	87.4	0.001*

Unpaired Student t-Test. (p<0.05 indicates statistical significance)

Table III : Mauchly's Test of Sphericity.

Within subjects effect (Design Intercept)	Mauchly's W	p-value	Epsilon		
			Greenhouse- Geisser	Huynh- Feldt	Lower bound
Group I (Time)	0.487	0.002*	0.663	0.675	0.510
Group II (Time)	0.412	0.001*	0.597	0.688	0.523

Indicates Statistical Significance (p<0.05)

Table IV : Multivariate Tests

Effect	Value	F- Value	p-value
Group I (Time) Wilks' Lambda	0.471	23.612	<0.001*
Group II (Time) Wilks' Lambda	0.419	24.021	<0.001*

*Indicates Statistical Significance (p<0.05)

Table V : Pairwise Comparisons

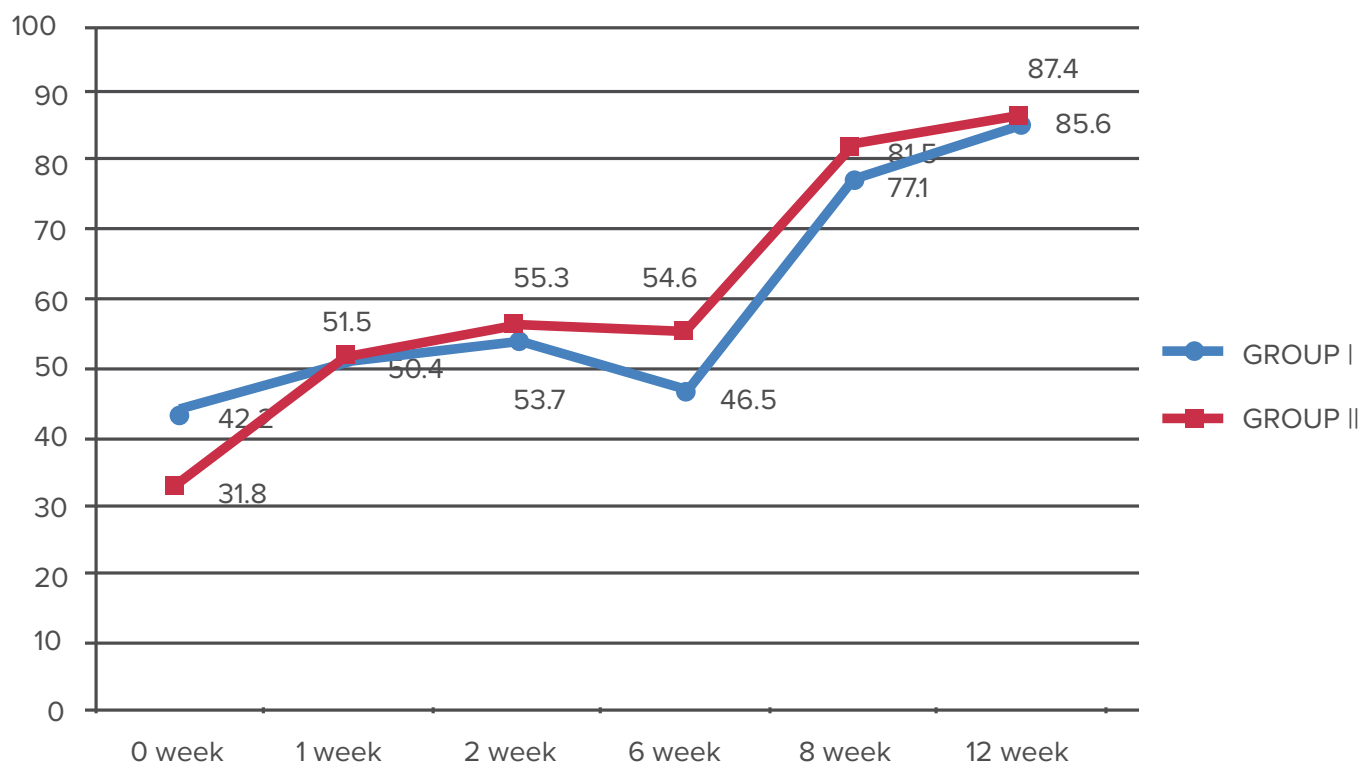
	GROUP I (SLA)			GROUP II (RBM)		
		Mean Difference	p-value		Mean Difference	p-value
Immediate post- op (0 weeks)	1 Week	-7.2	<0.001*	1 Week	-19.7	<0.001*
	2 Weeks	-10.5		2 Weeks	-23.5	
	6 Weeks	-3.3		6 Weeks	-22.8	
	8 Weeks	-33.9		8 Weeks	-49.7	
	12 Weeks	-42.4		12 Weeks	-55.6	
1 Week	Immediate post- op (0 weeks)	7.2	<0.001*	Immediate post- op (0 weeks)	19.7	<0.001*
	2 Weeks	-3.3		2 Weeks	-3.8	
	6 Weeks	3.9		6 Weeks	-3.1	
	8 Weeks	-26.7		8 Weeks	-30.0	
	12 Weeks	-35.2		12 Weeks	-35.9	
2 Weeks	Immediate post- op (0 weeks)	10.5	<0.001*	Immediate post- op (0 weeks)	23.5	<0.001*
	2 Weeks	3.3		2 Weeks	3.8	
	6 Weeks	7.2		6 Weeks	0.7	
	8 Weeks	-23.4		8 Weeks	-26.2	
	12 Weeks	-31.9		12 Weeks	-32.1	
6 Weeks	Immediate post- op (0 weeks)	3.3	<0.001*	Immediate post- op (0 weeks)	22.8	<0.001*
	2 Weeks	-3.9		2 Weeks	3.1	
	6 Weeks	-7.2		6 Weeks	-0.7	
	8 Weeks	-30.6		8 Weeks	-26.9	
	12 Weeks	-39.1		12 Weeks	-32.8	

	GROUP I (SLA)			GROUP II (RBM)		
8 Weeks	Immediate post- op (0 weeks)	33.9	<0.001*	Immediate post- op (0 weeks)	49.7	<0.001*
	2 Weeks	26.7		2 Weeks	30.0	
	6 Weeks	23.4		6 Weeks	26.2	
	8 Weeks	30.6		8 Weeks	26.9	
	12 Weeks	-8.5		12 Weeks	-5.9	
12 Weeks	Immediate post- op (0 weeks)	42.4	<0.001*	Immediate post- op (0 weeks)	55.6	<0.001*
	2 Weeks	35.2		2 Weeks	35.9	
	6 Weeks	31.9		6 Weeks	32.1	
	8 Weeks	39.1		8 Weeks	32.8	
	12 Weeks	8.5		12 Weeks	5.9	

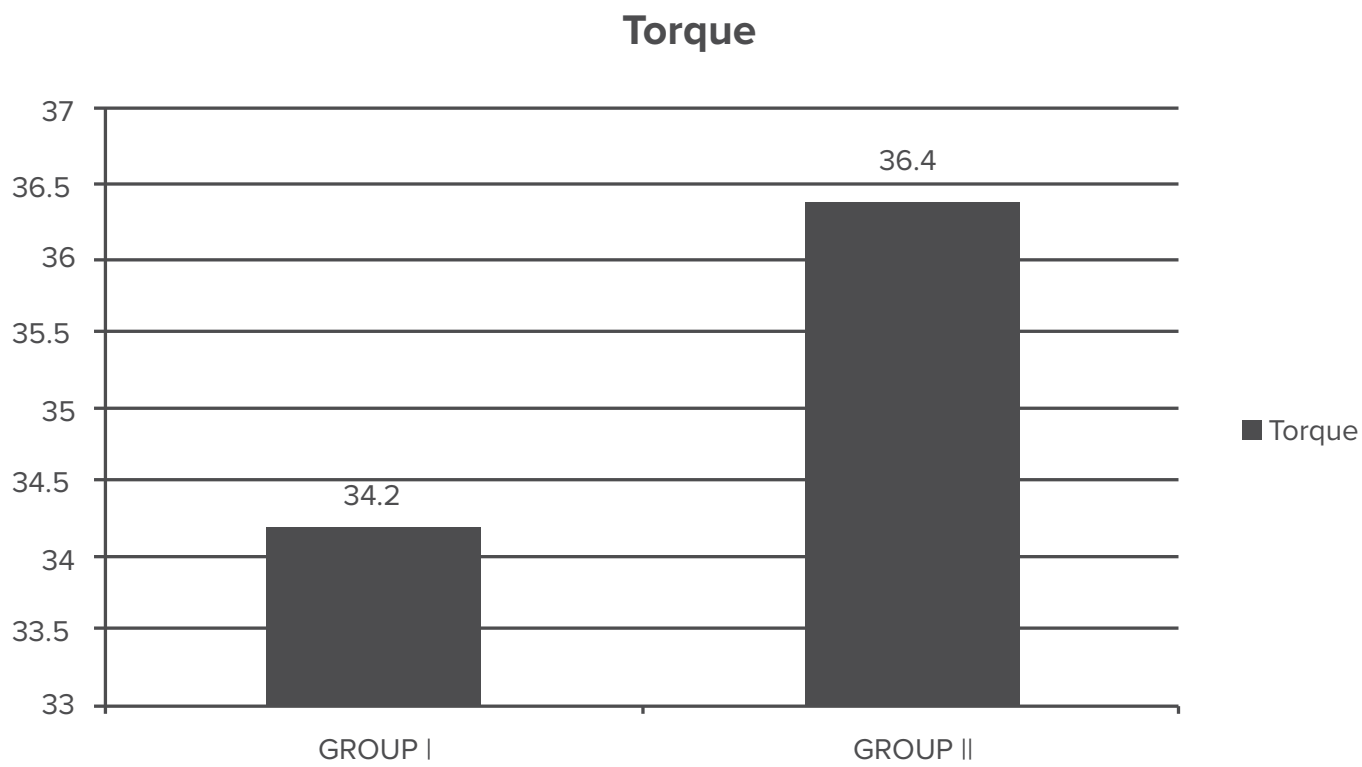
Post-hoc Bonferroni correction based on estimated marginal means.

*Indicates Statistical Significance (p<0.05)

Graph I : Resonance Frequency Analysis in both groups



Graph II Torque during implant placement in both groups



Discussion

The success of dental implant is affected by various factors. The general and oral health of the patient, presence of systemic diseases, diabetes mellitus, osteoporosis, bleeding disorders etc. determine the future outcome of dental implant therapy.⁹

The diameter, length, site and design of dental implant also affects the stability of dental implant. The quality of bone affects the osseointegration process. Implant placed at D1 and D2 bones are more likely to show better osseointegration as compared to D3 and D4 bone.¹⁰

In present study we compared ISQ of two similar design implants but treated with Sand blasted large-grit aluminum oxide acid etched (SLA) and biological calcium phosphate surface treated Resorbable Blast Medium (RBM) mechanism. Sim CP et al¹¹ in their study evaluated the factors such as length of dental implant, quality of bone and instrument positioning on RFA. They suggested that ISQ is affected by bone quality and implant length. Implant placed in D1 and D2 bone is highly stable and shows better osseointegration.

Atieh et al¹² revealed that RFA greatly determines the success and failure rate of dental implants. This technique may be used in healing period to assess the stability of dental implant. Bone deposition at the interface of implant- bone can be evaluated by increasing ISQ.

In present study we found that in case of group I, minimum mean ISQ was 43.2 and maximum was 85.6. In case of group II, maximum value was 87.4 and minimum was 31.8. Our results are in agreement with the results of Han et al¹³ who found lowest ISQ as 55 and highest as 85. Ersanli et al¹⁴ observed highest ISQ value in type I and II bone than type III and IV bone.

It was observed that ISQ level at all weeks in both groups increased significantly with the progression of time. This may be due to difference in primary and secondary stability between weeks.

At initial weeks, low ISQ may indicate loss of primary stability and increase in value indicates secondary stability. Simunek et al¹⁵ in their study concluded that during early healing of immediately loaded implant, there is minimum stability at 3rd and 4th weeks. Similarly, in our study, it was quite lower at both weeks as compared to subsequent weeks in both groups.

We observed that the ISQ value increased significantly from 4th week to 12th weeks and at the end both the groups. Gahona et al¹⁶ in their study evaluated ISQ of dental implants placed in maxilla and mandible. This comprised of 29 implants in mandibular arch and 31 in maxillary arch. It was seen that in implants with ISQ more than 60, there was successful osseointegration than those less than 60. Similarly, better osseointegration was observed in implants with torque insertion 35 or above.

We observed that torque value in group I was 34.2 and in group II was 36.4. Sarfaraz et al¹⁷ conducted a study on 37 patients. ISQ was measured in 3rd, 7th, 11th and

15th week. Author evaluated RFA, ISQ and insertion torque value. There was positive correlation between ISQ and ITV.

Bornstein et al¹⁸ in their study assessed the ISQ in 3 years prospective study. A comparison was done between acid-etched surface implant and chemically modified sandblasted implant. They suggested that hydrophilic implants have 2 times faster and better osseointegration. SLA implants had ability to be loaded in 3 weeks than 7-8 weeks.

Rocuzzo et al¹⁹ in their study demonstrated that SLA implants can be best placed at 3rd week especially in maxillary posterior teeth region. Maxillary posterior region has type III or IV bone which shows higher implant failure rates. However, surfaced modified dental implants are effectively placed in this bone with higher survival rate. In present study, we used SLA and RBM chemically modified dental implants. Active surface treatment of dental implants makes it efficient for osseointegration even in bone with poor density.

Kokovic V et al²⁰ in their study of immediate vs. early loading of SLA implants in the posterior mandibular region suggested that ISQ >70 is the indicator of higher implant stability. In both groups, we observed ISQ above 80 which is predictor of implant success.

Park et al²¹ in their study on rabbit tibia found a correlation between ISQ and BIC after 4 weeks of healing. We observed that stability increased with time in both groups. Chambrone et al²² suggested that surface treated implants may more effectively inserted in poor quality bone and one can expect better results in such cases.

The shortcoming of the study is that small sample was utilized for the study. Long term follow up was not done in present study. Only maxillary posterior region was considered whereas in cases of other parts of jaw bones could have resulted in different findings. Other causes of implant failure such as poor oral hygiene, smoking etc might be the reason for poor osseointegration.

Conclusion

There is fastest osseointegration in implants with RBM surfaces than with SLA surfaces. ISQ was higher than 80 in both groups which indicate higher implant stability. However large scale studies are required to substantiate the results obtained in this study.

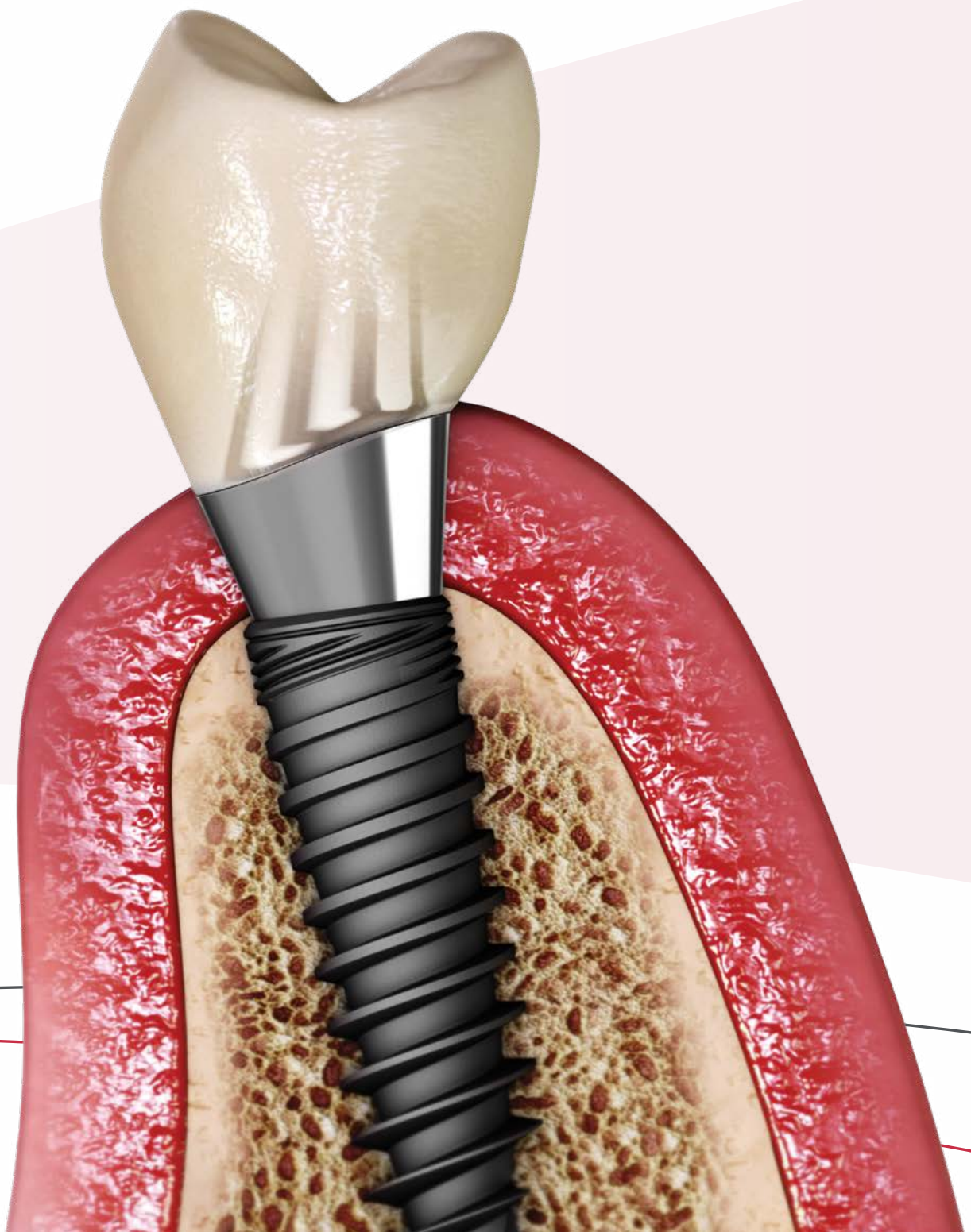
Clinical Significance

Surface treatment of dental implants offers higher implant bone osseointegration.

References

1. Testori T, Galli F. Immediate non-occlusal versus early loading of dental implants in practically edentulous patients. *Int J Oral Maxillofac Implants* 2007; 22:815-22.
2. Friberg B, Sennerby L, Meredith N, Lekholm U. A comparison between cutting torque and resonance frequency measurements of maxillary implants. A 20-month clinical study. *Int J Oral Maxillofac Surg* 1999; 28:297-303.
3. Testori T, Del Fabbro M, Szmukler-Moncler S, Francetti L, Weinstein RL. Immediate occlusal loading of osseointegrated implants in the completely edentulous mandible. *Int J Oral Maxillofac Implants* 2003; 18:544-51.
4. Meredith N, Alleyne D, Cawley P. Quantitative determination of the stability of the implant-tissue interface using resonance frequency analysis. *Clin Oral Implants Res* 1996; 7:261-7.
5. Balleri P, Cozzolino A, Ghelli L, Momicchioli G, Varriale A. Stability measurements of osseointegrated implants using osstell in partially edentulous jaws after 1 year of loading: A pilot study. *Clin Implant Dent Relat Res* 2002; 4:128-32.
6. Javed F, Ahmed HB, Crespi R, Romanos GE. Role of primary stability for successful osseointegration of dental implants: Factors of influence and evaluation. *Interv Med Appl Sci* 2013; 5:162-7.
7. Lozano-Carrascal N, Salomó-Coll O, Gilabert-Cerdà M, Farré-Pagés N, Gargallo-Albiol J, Hernández-Alfaro F, et al. Effect of implant macro-design on primary stability: A prospective clinical study. *Med Oral Patol Oral Cir Bucal* 2016; 21:214-21.
8. Ostman PO, Hellman M, Sennerby L. Direct implant loading in the edentulous maxilla using a bone density-adapted surgical protocol and primary implant stability criteria for inclusion. *Clin Implant Dent Relat Res*. 2005; 7(suppl 1):60-69.
9. Rodrigo D, Aracil L, Martin C, Sanz M. Diagnosis of implant stability and its impact on implant survival: a prospective case series study. *Clin Oral Implants Res*. 2010; 21(3):255-261.
10. Sennerby L, Meredith N. Implant stability measurements using resonance frequency analysis: biological and biomechanical aspects and clinical implications. *Periodontol* 2000 2008; 47:51-66.
11. Sim CP, Lang NP. Factors influencing resonance frequency analysis assessed by Osstell mentor during implant tissue integration: I. Instrument positioning, bone structure, implant length. *Clin Oral Implants Res*. 2010;21(6):598-604.
12. Atieh MA, Alsabeeha NH, Payne AG. Can resonance frequency analysis predict failure risk of immediately loaded implants? *Int J Prosthodont*. 2012; 25(4):326-339.
13. Han J, Lulic M, Lang NP. Factors influencing resonance frequency analysis assessed by Osstell mentor during implant tissue integration: II. Implant surface modifications and implant diameter. *Clin Oral Implants Res*. 2010;21(6):605-611.
14. Ersanli S, Karabuda C, Beck F, Leblebicioglu B. Resonance frequency analysis of one-stage dental implant stability during the osseointegration period. *J Periodontol*. 2005; 76(7):1066-1071.
15. Simunek A, Kopecka D, Brazda T, Strnad I, Capek L, Slezak R. Development of implant stability during early healing of immediately loaded implants. *Int J Oral Maxillofac Implants*. 2012; 27(3): 619-627.
16. Gahona O, Granic X, Antunez C, Domancic S, Diaz-Narvaez V, Utsman R. Insertion torque and resonance frequency analysis (ISQ) as predictor methods of Implant osseointegration. *J Osseointegr* 2018; 10(3):103-107.
17. Sarfaraz H, Johri S, Sucheta P, Rao S. Study to assess the relationship between insertion torque value and implant stability quotient and its influence on timing of functional implant loading. *J Indian Prosthodont Soc* 2018; 18:139-46.
18. Bornstein MM, Wittneben JG, Bragger U, Buser D. Early loading at 21 days of non-submerged titanium implants with a chemically modified sandblasted and acid-etched surface: 3-year results of a prospective study in the posterior mandible. *J Periodontol*. 2010; 81 (6):809-818.
19. Rocuzzo M, Wilson TG Jr. A prospective study of 3 weeks' loading of chemically modified titanium implants in the maxillary molar region: 1-year results. *Int J Oral Maxillofac Implants*. 2009; 24(1): 65-72.
20. Kokovic V, Jung R, Feloutzis A, Todorovic VS, Jurisic M, Hammerle CH. Immediate vs. early loading of SLA implants in the posterior mandible: 5-year results of randomized controlled clinical trial. *Clin Oral Implants Res*. 2014;25(2):114-119.
21. Park KJ, Kwon JY, Kim SK, et al. The relationship between implant stability quotient values and implant insertion variables: a clinical study. *J Oral Rehabil* 2012; 39(2):151-159.
22. Chambrone L, Shibli JA, Mercurio CE, Cardoso B, Preshaw PM. Efficacy of standard (SLA) and modified sandblasted and acid-etched (SL Active) dental implants in promoting immediate and/or early occlusal loading protocols: a systematic review of prospective studies. *Clin Oral Implants Res*. 2015; 26:359-370.

Prevention of Peri-implantitis



A New System of Implant Abutment Connection: How to Improve a Two Piece Implant System Sealing

F. GRECCHI¹, M. DI GIROLAMO², F. CURA³, V. CANDOTTO⁴, F. CARINCI⁴

¹Department of Maxillofacial Surgery, Galeazzi Hospital, Milan, Italy

²Department of Clinical Sciences and Translational Medicine, University of Tor Vergata, Rome, Italy

³Department of Experimental, Diagnostic and Specialty Medicine, University of Bologna, Bologna, Italy

⁴Department of Morphology, Surgery and Experimental Medicine, University of Ferrara, Ferrara, Italy

SUMMARY

Purpose. Implant dentistry has become one of the most successful dentistry techniques for replacing missing teeth. The success rate of implant dentistry is above 80%. However, peri-implantitis is a later complication of implant dentistry that if untreated, can lead to implant loss. One of the hypothesized causes of peri-implantitis is the bacterial leakage at the level of implant-abutment connection. Bacterial leakage is favored by the presence of a micro gap at the implant-abutment interface, allowing microorganisms to penetrate and colonize the inner part of the implant leading to biofilm accumulation and consequently to peri-implantitis development.

Materials and methods: To identify the capability of the implant to protect the internal space from the external environment, the passage of genetically modified *Escherichia coli* across implant-abutment interface was evaluated. Implants were immersed in a bacterial culture for twenty-four hours and then bacteria amount was measured inside implant-abutment interface with Real-time PCR.

Results: Bacteria were detected inside all studied implants, with a median percentage of 9%.

Conclusions: The reported results are better to those of previous studies carried out on different implant systems. Until now, none implant-abutment system has been proven to seal the gap between implant and abutment.

Key words: implant-abutment connection, implant dentistry, bacterial leakage, peri-implantitis, bone resorption.

Introduction

Implant dentistry has become one of the most successful dentistry techniques for replacing missing teeth. The success rate of implant dentistry is above 80% (1-16) and implant placement requires an adequate quantity and quality of bone (17-25).

However, peri-implantitis is a later complication of implant dentistry, that if untreated can lead to implant loss.

One of the hypothesized causes of peri-implantitis is the bacterial leakage at the level of implantabutment interface. Bacterial leakage is favored by the presence of a micro gap at the implantabutment interface level, allowing microorganisms to penetrate and colonize the inner part of the implant leading to biofilm accumulation and consequently to peri-implantitis development (26, 27). Peri-implantitis is associated with a significantly higher inflammatory cell infiltration and bone loss (28). Prevention of microbial leakage at the level of implant-abutment interface is the main aim for the construction of a new two-piece implant systems (TPISs) to avoid inflammation in peri-implant tissues.

The aim of our study is to value the microbial leakage at implant-abutment interface of a new TPIS (Noris Medical Dental Implants System, Israel).

Tuff two-piece implant system

Tuff implant (Noris Medical Dental Implants System, Israel) is a new TPIS, which, with its three thread zones, has been designed according to the anatomy of the bone structure. The lower V-shape thread zone is for self-tapping. The middle zone has a square thread design, used especially for compressing cancellous bone, and helping achieving BIC (Bone-Implant Contact). The micro thread design on the upper zone adds stability and reduces crestal bone loss. Mono implants are specifically indicated for replacing maxillary lateral incisors and mandibular central and lateral incisors. They are cleared for immediate, non-occlusal provisionalization in singletooth restorations. Multiple unit restorations should be splinted together and may be used immediately, when clinically appropriate.

The Noris Medical Dental TPIS includes different types and sizes of dental implants made of medical grade Titanium Alloy and undergo a unique surface treatment.

Noris Medical TPIS are used for rehabilitating completely or partially edentulous patients. The rehabilitation on the implants includes a number of options: single crown, a number of connected crowns and partial or full dentures that are connected to Noris Medical TPIS using abutments. Quantity and quality of bone that are suitable for performing implants are an essential condition. This data is gathered during the planning stage by making appropriate radiographs (panoramic and computer tomography) of the implantation site. Anatomic areas near the implantation site such as: blood vessels, nerves, maxillary sinus and nasal cavity must be identified in order to prevent their damage. The performance of surgical procedures is subject to the patient's systemic condition.

The Noris Medical Dental TPIS employs internal hex connection designed to provide assembly facility while minimizing micro movements of the implant/abutment connection. The implants material composition is: Ti 6AL 4V - ELI. The Noris Medical TPIS surface is RBM treated. RBM (Resorbable Blast Media) Surface Technology is a surface treatment processed by blasting the implant with a soluble calcium phosphate material, creating a macro surface roughness, using of biocompatible Calcium Phosphate blasting media. Calcium Phosphates are easily dissolved by gentle solvents like alcohol, leaving well textured surface completely free of contaminants.

Noris Medical Dental TPIS is intended to replace missing tooth/teeth in either jaw for supporting prosthetic devices that may aid in restoring the patient's chewing function. The procedure can be accomplished in a one-stage or two-stage surgical operation. All implants are appropriate for immediate loading when good primary stability is achieved and with appropriate occlusal loading.

Materials and methods

Implant preparation

In order to size up the ability of the implant to isolate the heart of the device from the external environment, we evaluated the passage of modified *E. coli* across the joint of the implant. The peculiarity of these bacteria is that they contain synthetic DNA target sequences in their plasmid. In detail, the plasmid contains two sequence specific for two bacterial species (*P. gingivalis* and *T. forsythia*) and two genes for antibiotic selection (Kanamycin and Ampicillin).

Bacteria were cultured in lysogeny broth (LB) containing both Kanamycin and Ampicillin (at a final concentration of 50ug/ml) at 37°C for 12-18h in a shaking incubator. Four Tuff implants (Noris Medical®, Israel) were used in this study (Figure 1). Few microliters of LB with antibiotics were put inside the implants. The implants and the abutment are screwed with a torque of 35 Ncm. Few microliters of this culture were used to "contaminate" fresh LB with antibiotics contained in a microcentrifuge tube together with the implant. Tubes were then let at 37°C for 48h in a heater, in order to allow bacterial growth and their hypothetical passage within the implant. Inside the implant, instead, we just put LB and antibiotics without bacteria.

To be sure that there were no contaminations, a negative control containing only LB and antibiotics, was prepared.

Forty-eight hours later, implants were opened and samples were collected by dipping a paper probe in both the sites containing LB (external and internal to the implant) for each implant, and in the negative control too.

DNA extraction

Once collected, paper probe were put on a new microcentrifuge tube and processed for bacterial DNA extraction, by using the GenElute™ Bacterial Genomic DNA Kit (Sigma-Aldrich, St., St. Louis, MO, USA), following the manufacturing procedures. Briefly, samples were incubated with lysozyme and, subsequently with proteinase K to isolate DNA. Once extracted, DNA was purified by spin-column method.

Real-time polymerase chain reaction

Bacterial quantification was performed by Real-Time Polymerase Chain Reaction using the absolute quantification with the standard curve method.

Primers and probes oligonucleotides for *P. gingivalis* and *T. forsythia* were designed basing on 16S rRNA gene sequences of the Human Oral Microbiome Database (HOMD 16S rRNA Ref- Seq Version 10.1). For the quantitative analysis, plasmid (Eurofin MWG Operon, Ebersberg Germany) containing the specific DNA target sequence was employed as standard.

All reactions were performed in duplex, in 20ul final volumes, with 2X TaqMan Universal PCR master mix (Applied Biosystems, Foster City, CA, USA) and 50nM concentration of each primers and 200nM of the probes. Amplifications were carried out by using the ABI PRISM 7500 (Applied Bio systems, Foster City, CA, USA).

Statistical analysis

To evaluate if the difference in viability among outside and inside the implant was statistically significant, we applied Student's t-test on average bacteria quantification at each time point.



Figure 1

Tuff Implant and abutment by Noris Medica

Results

Bacteria quantification is reported in Table 1. In all the tested implants, bacteria were found in the inner side, with a median percentage of 9%. The analysis revealed that in both cases (internally and externally), bacteria grew for the first 48 hours but subsequently they started to dye, probably as a consequence of nutrient consumption. Moreover, the difference between outer and inner bacteria concentration was statistically significant at each time point.

Table 1 : Absolute quantification of *P. gingivalis* and *T. forsythia*, outside and inside the implant. Implant permeability is expressed as percent rate of the internal vs external bacteria quantity.

Implant	Bacteria	Bacteria quantity	Implant	Bacteria	Bacteria quantity	Passage of bacteria from outside to inside the implant (%)
1 OUTSIDE	<i>P. gingivalis</i>	3581973	1 INSIDE	<i>P. gingivalis</i>	697785	19%
	<i>T. forsythia</i>	3304664		<i>T. forsythia</i>	708424	21%
2 OUTSIDE	<i>P. gingivalis</i>	7195087	2 INSIDE	<i>P. gingivalis</i>	396791	6%
	<i>T. forsythia</i>	6789549		<i>T. forsythia</i>	400960	6%
3 OUTSIDE	<i>P. gingivalis</i>	4579415	3 INSIDE	<i>P. gingivalis</i>	1082464	24%
	<i>T. forsythia</i>	4582728		<i>T. forsythia</i>	1084939	24%
4 OUTSIDE	<i>P. gingivalis</i>	2820289	4 INSIDE	<i>P. gingivalis</i>	89335	3%
	<i>T. forsythia</i>	2720166		<i>T. forsythia</i>	98433	4%
5 OUTSIDE	<i>P. gingivalis</i>	1351250	5 INSIDE	<i>P. gingivalis</i>	198973	15%
	<i>T. forsythia</i>	1372971		<i>T. forsythia</i>	203651	15%
6 OUTSIDE	<i>P. gingivalis</i>	2877517	6 INSIDE	<i>P. gingivalis</i>	88918	3%
	<i>T. forsythia</i>	2452891		<i>T. forsythia</i>	100066	4%
7 OUTSIDE	<i>P. gingivalis</i>	1124582	7 INSIDE	<i>P. gingivalis</i>	142005	13%
	<i>T. forsythia</i>	1150407		<i>T. forsythia</i>	145277	13%
8 OUTSIDE	<i>P. gingivalis</i>	1150527	8 INSIDE	<i>P. gingivalis</i>	101557	9%
	<i>T. forsythia</i>	1112707		<i>T. forsythia</i>	128467	12%
9 OUTSIDE	<i>P. gingivalis</i>	8131886	9 INSIDE	<i>P. gingivalis</i>	101248	1%
	<i>T. forsythia</i>	7506339		<i>T. forsythia</i>	111292	1%
10 OUTSIDE	<i>P. gingivalis</i>	2836594	10 INSIDE	<i>P. gingivalis</i>	243945	9%
	<i>T. forsythia</i>	2614350		<i>T. forsythia</i>	252896	10%
11 OUTSIDE	<i>P. gingivalis</i>	1792653	11 INSIDE	<i>P. gingivalis</i>	100353	6%
	<i>T. forsythia</i>	1700109		<i>T. forsythia</i>	101758	6%
12 OUTSIDE	<i>P. gingivalis</i>	1310796	12 INSIDE	<i>P. gingivalis</i>	110644	8%
	<i>T. forsythia</i>	1173590		<i>T. forsythia</i>	112948	10%
Negative Control OUTSIDE	<i>P. gingivalis</i>	0	Negative Control INSIDE	<i>P. gingivalis</i>	0	0
	<i>T. forsythia</i>	0		<i>T. forsythia</i>	0	0
	Media Outside			Media Inside		
	PorG	3229381	PorG	Media Inside	279502	9%
	TanF	3040039	TanF	Media Inside	287426	9%

Discussion

Bacterial leakage at implant-abutment connection is the main cause of peri-implantitis. The current TPISs cannot completely prevent microleakage and consequent bacterial colonization of the inner part of the implants.

Although efforts have been made to reduce this TPISs limitation, several investigations have shown that bacterial oral leakage along the implantabutment interface may constitute a potential risk of inflammation of the supporting tissues, compromising the long-term success of the treatment with TPISs. A diversity of data regarding the leakage and consequent bacterial penetration along the gaps and cavities into the TIPSSs, as a consequence of poor adaptation of components, has been reported in some in vitro studies (26-37).

Other studies demonstrated microbial penetration of the TPISs micro gap of fixtures with an external hex design (29, 30). Some studies (31, 32) have investigated bacterial leakage of TPISs in order to find an efficient bacterial seal system.

With the TPISs, the abutment is retained in the fixture with mechanical methods, favoring an inflammatory process in peri-implant tissues.

Microbial colonization of the TPISs may have consequences as bone resorption. Some in vitro studies has demonstrated the passage of fluid into and out of TPISs. Our results are better to those reported in the English literature (33, 34). Aloise et al. found that the frequency of bacterial leakage was 20% of the TPIS of Bicon® and Ankylos® systems (27). Implant internal contamination evidently shows that the presence of gap in TPISs may represent a bacterial passage from the external medium (35).

TPISs do not prevent microbiological leakage in the inner part of implant-abutment interface (36).

In any case, the peri-implantitis is associated with gram- negative bacteria similar to those that cause periodontal disease (37).

The peri-implantitis, such as periodontal disease, is the result of the bacterial insult and the subsequent host response, in fact some studies have shown that bacterial species of periodontal disease are very similar to those that cause peri-implantitis (38).

Blocking the passage of bacteria, in a TPIS is essential to prevent periimplantitis, in fact the presence of a cavity near to bone may influence in the development of peri-implant inflammation and bone resorption.

An intense inflammatory cell infiltrate may be the cause of a significant bone resorption in a TPIS, on the contrary one-piece implants showed a minimal inflammation and bone loss around peri-implant tissues.

Some studies demonstrated that the presence of a micro gap significantly influence hard and soft tissues around an implant, so few literature data are available about the differences in the microbial penetration in TPISs with different connection designs.

The design of the implant-abutment junction may have an impact on the amount of bacterial penetration in the internal part of dental implants of a TPIS system.

Conclusions

The reported results are similar to previous work. Noris Medical Dental Implants System showed bacterial leakage better respect others implant systems (9 versus 20% of Bicon® and Ankylos® systems). In spite of the limits of our study, none TPIS has been demonstrated to perfectly close the gap between implant and abutment.

References

1. Rigo L, Viscioni A, Franco M, et al. Overdentures on implants placed in bone augmented with fresh frozen bone. *Minerva Stomatol.* 2011;60:5-14.
2. Carinci F, Brunelli G, Franco M, et al. A retrospective study on 287 implants installed in resorbed maxillae grafted with fresh frozen allogeneous bone. *Clin Implant Dent Relat Res.* 2010;12:91-98.
3. Viscioni A, Rigo L, Franco M, et al. Reconstruction of severely atrophic jaws using homografts and simultaneous implant placement: a retrospective study. *J Oral Implantol.* 2010;36:131-139.
4. Danza M, Paracchini L, Carinci F. Tridimensional finite element analysis to detect stress distribution in implants. *Dental Cadmos.* 2012;80:598-602.
5. Danza M, Grecchi F, Zollino I, et al. Spiral implants bearing full-arch rehabilitation: Analysis of clinical outcome. *Journal of Oral Implantology.* 2011;37:447- 455.
6. Danza M, Zollino I, Avantaggiato A, et al. Distance between implants has a potential impact of crestal bone resorption. *Saudi Dental Journal.* 2011;23:129-133.
7. Carinci F, Danza M. Clinical outcome of implants inserted in piezo split alveolar ridges: A pilot study. In: eds. *Perspectives on Clinical Dentistry.* 2011;29-30.
8. Danza M, Zollino I, Guidi R, et al. Computer planned implantology: Analysis of a case series. In: (ed.^(eds. *Perspectives on Clinical Dentistry.* 2011;287-300.
9. Danza M, Carinci F. Flapless surgery and immediately loaded implants: a retrospective comparison between implantation with and without computer-assisted planned surgical stent. *Stomatologija.* 2010;12:35-41.
10. Danza M, Quaranta A, Carinci F, et al. Biomechanical evaluation of dental implants in D1 and D4 bone by Finite Element Analysis. *Minerva stomatologica.* 2010; 59:305-313.
11. Danza M, Riccardo G, Carinci F. Bone platform switching: a retrospective study on the slope of reverse conical neck. *Quintessence Int.* 2010;41:35-40.
12. Calvo-Guirado JL, Ortiz-Ruiz AJ, Lopez-Mari L, et al. Immediate maxillary restoration of single-tooth implants using platform switching for crestal bone preservation: a 12-month study. *Int J Oral Maxillofac Implants.* 2009;24:275-281.

13. Andreasi Bassi M, Lopez MA, Confalone L, et al. Clinical outcome of a two-piece implant system with an internal hexagonal connection: a prospective study. *J Biol Regul Homeost Agents*. 2016;30:7-12.
14. Lucchese A, Carinci F, Saggese V, et al. Immediate loading versus traditional approach in functional implantology. *European Journal of Inflammation*. 2012;10:55-58.
15. Traini T, Danza M, Zollino I, et al. Histomorphometric evaluation of an immediately loaded implant retrieved from human mandible after 2 years. *International Journal of Immunopathology and Pharmacology*. 2011;24:31-36.
16. Scarano A, Murmura G, Carinci F, et al. Immediately loaded small-diameter dental implants: evaluation of retention, stability and comfort for the edentulous patient. *European Journal of Inflammation*. 2012;10:19-23.
17. Baj A, Trapella G, Lauritano D, et al. An overview on bone reconstruction of atrophic maxilla: success parameters and critical issues. *J Biol Regul Homeost Agents*. 2016;30:209-215.
18. Grecchi F, Perale G, Candotto V, et al. Reconstruction of the zygomatic bone with smartbone®: Case report. *Journal of Biological Regulators and Homeostatic Agents*. 2015;29:42-47.
19. Lauritano D, Avantaggiato A, Candotto V, et al. Insulin activity on dental pulp stem cell differentiation: An in vitro study. *Journal of Biological Regulators and Homeostatic Agents*. 2015;29:48-53.
20. Tettamanti L, Andreasi Bassi M, Trapella G, et al. Applications of biomaterials for bone augmentation of jaws: Clinical outcomes and in vitro studies. *ORAL and Implantology*. 2017;10:37-44.
21. Baj A, Sollazzo V, Lauritano D, et al. Lights and shadows of bone augmentation in severe resorbed mandible in combination with implant dentistry. *Journal of Biological Regulators and Homeostatic Agents*. 2016;30:177-182.
22. Lauritano D, Avantaggiato A, Candotto V, et al. Effect of somatostatin on dental pulp stem cells. *Journal of Biological Regulators and Homeostatic Agents*. 2015;29: 54-58.
23. Baj A, Muzio LL, Lauritano D, et al. Success of immediate versus standard loaded implants: A short literature review. *Journal of Biological Regulators and Homeostatic Agents*. 2016;30:183-188.
24. Calcaterra R, Di Girolamo M, Mirisola C, et al. Effects of Repeated Screw Tightening on Implant Abutment Interfaces in Terms of Bacterial and Yeast Leakage in Vitro: One-Time Abutment Versus the Multiscrewing Technique. *Int J Periodontics Restorative Dent*. 2016;36:275-280.
25. Calcaterra R, Pasquantonio G, Vitali LA, et al. Occurrence of *Candida* species colonization in a population of denture-wearing immigrants. *Int J Immunopathol Pharmacol*. 2013;26:239-246.
26. do Nascimento C, Miani PK, Pedrazzi V, et al. Leakage of saliva through the implant-abutment interface: in vitro evaluation of three different implant connections under unloaded and loaded conditions. *Int J Oral Maxillofac Implants*. 2012;27:551-560.
27. Aloise JP, Curcio R, Laporta MZ, et al. Microbial leakage through the implant-abutment interface of Morse taper implants in vitro. *Clin Oral Implants Res*. 2010; 21:328-335.
28. do Nascimento C, Miani PK, Watanabe E, et al. In vitro evaluation of bacterial leakage along the implant-abutment interface of an external-hex implant after saliva incubation. *Int J Oral Maxillofac Implants*. 2011; 26:782-787.
29. D'Ercole S, Tripodi D, Ravera L, et al. Bacterial leakage in Morse Cone internal connection implants using different torque values: an in vitro study. *Implant Dent*. 2014;23:175-179.
30. do Nascimento C, Barbosa RE, Issa JP, et al. Bacterial leakage along the implant-abutment interface of premachined or cast components. *Int J Oral Maxillofac Surg*. 2008;37:177-180.
31. Baggi L, Di Girolamo M, Mirisola C, et al. Microbiological evaluation of bacterial and mycotic seal in implant systems with different implant-abutment interfaces and closing torque values. *Implant Dent*. 2013;22:344-350.
32. do Nascimento C, Barbosa RE, Issa JP, et al. Use of checkerboard DNA-DNA hybridization to evaluate the internal contamination of dental implants and comparison of bacterial leakage with cast or pre-machined abutments. *Clin Oral Implants Res*. 2009;20:571-577.
33. Jaworski ME, Melo AC, Picheth CM, et al. Analysis of the bacterial seal at the implant-abutment interface in external-hexagon and Morse taper-connection implants: an in vitro study using a new methodology. *Int J Oral Maxillofac Implants*. 2012;27:1091-1095.
34. Dias EC, Bisognin ED, Harari ND, et al. Evaluation of implant-abutment microgap and bacterial leakage in J Oral Maxillofac Implants. 2012;27:346-351.
35. Cosyn J, Van Aelst L, Collaert B, et al. The peri-implant sulcus compared with internal implant and suprastructure components: a microbiological analysis. *Clin Implant Dent Relat Res*. 2011;13:286-295.
36. Koutouzis T, Wallet S, Calderon N, et al. Bacterial colonization of the implant-abutment interface using an in vitro dynamic loading model. *J Periodontol*. 2011; 82:613-618.
37. Koutouzis T, Mesia R, Calderon N, et al. The Effect of Dynamic Loading on Bacterial Colonization of the Dental Implant Fixture-Abutment Interface: An Invitro Study. *J Oral Implantol*. 2012.
38. Barbosa RE, do Nascimento C, Issa JP, et al. Bacterial culture and DNA Checkerboard for the detection of internal contamination in dental implants. *J Prosthodont*. 2009;18:376-381.

Correspondence to:

Prof. Francesco Carinci, MD
Department of Morphology,
Surgery and Experimental Medicine
University of Ferrara
Via Luigi Borsari 46
44121 Ferrara, Italy

Phone: +39.0532.455874

Fax: +39.0532.455876

E-mail: crc@unife.it

A Comparative Evaluation of Height of Interdental Papilla around Noris Tuff TT and Nobel Active Dental Implants placed in Maxillary Anterior Region

Nitin Ahuja¹, Ritika Arora², Vaibhav Kumar³, Johnson Raja James⁴

¹MDS - Oral and Maxillofacial Surgery, Private practitioner and Implantologist, Dentistry Dental Clinic, Oberoi splendour D-205, Andheri East, JVLR, Mumbai - 400060

²Professor and Head, Department of Periodontics, Vadik Dental College and Research Centre, Daman,

³Lecturer, Department of Public Health Dentistry, Terna Dental College, Navi Mumbai.

⁴MDS Periodontology, Professor & Vice Principal, Rajas Dental College & Hospital, 4/ 148, Shanthi Nagar, Palayamkottai, Tirunelveli - 627002

ABSTRACT

Background: Interdental papilla height is important as esthetic factor for dental implant success. The present study was conducted to compare the amount of soft tissues around Noris Tuff TT and Nobel Active dental implant systems. **Materials & Methods:** The present study was conducted on 28 patients (males- 13, females- 15) who received 32 dental implants in maxillary anterior region. Group I patients received Nobel Active dental implants and Group II patients received Noris Tuff TT dental implants. In all patients, interdental papilla was evaluated using JEMT index. The amount of bone loss in both groups was evaluated using paired and unpaired t-test.

Results: The amount of bone loss around dental implants in both groups did not show significant difference ($P > 0.05$). There was nonsignificant correlation between bone loss and papilla index in both groups ($P > 0.05$). **Conclusion:** The amount of interdental bone loss and papilla profile in the maxillary anterior region around Noris Tuff TT when compared to that around Nobel Active dental implants was non-significant.

Clinical significance: The preservation of interdental papilla is of paramount importance for the successful dental implant therapy.

Key words: Bone loss, Noris Tuff TT implants, Nobel Active implants, Interdental papilla, JEMT index.

Corresponding author: Dr Nitin Ahuja, MDS - Oral and Maxillofacial Surgery, Private practitioner and Implantologist, Dentistry Dental Clinic, Oberoi splendour D-205, Andheri East, JVLR, Mumbai - 400060.

This article may be cited as: Ahuja N, Arora R, Kumar V, James JR. A Comparative Evaluation of Height of Interdental Papilla around Noris Tuff TT and Nobel Active Dental Implants placed in Maxillary Anterior Region. J Adv Med Dent Scie Res 2018;6(11):5-9.

Introduction

Maxillary anterior region is common site for tooth loss. The causes may be trauma, cysts or tumors etc. The prime most reason to replace missing anterior teeth is esthetics and functions. Dental implants are considered options for replacing single tooth. This treatment modality has advantages over Fixed Partial Denture (FPD) or Removable Partial Denture (RPD). There is no need to prepare adjacent teeth as in cases of FPD. The clasps of RPD may lead to trauma to tooth as well as to soft tissues. Thus dental implants are useful in restoring function and esthetics.¹

Studies have revealed high success rate of 95% over 10 years for dental implants. The process of osseointegration promotes union of dental implant with bone, ensuring better attachment and success

rate. Apart from it, the soft tissues around dental implant play an important role in long term survival. Interdental papilla and labial gingiva add beauty to dental implants.^{2,3}

Factors such as periodontitis, over contoured restoration, flossing technique, improper alignment prosthetic part of M dental implant and abnormal tooth morphology may affect interdental papilla. The level of bone around dental implant and adjacent teeth determines the future outcome of treatment. Therefore, the height of interdental papilla may be regarded as deciding parameter for successful implant therapy. Literature has shown that there is variation in height of interdental papilla on distal and mesial side of dental implant.⁴ The present study was conducted to compare the amount of soft tissues around Nobel Active and Noris Tuff TT dental implant system.

Materials & Methods

The present three years retrospective study was conducted in a Mumbai, India (Aesthetic Smiles Dental Clinic). EC approval was obtained from an Independent Review Board. A non-probability convenience sample comprising of 28 patients (Males- 13, Females- 15) who received 32 dental implants in the maxillary anterior region was fixed as the study sample. Inclusion criteria were patients with dental implant in maxillary anterior region in last three years, no systemic diseases, non-smokers, pocket depth <3mm and no bone loss. Patients with poor quality radiographs, uncooperative, pregnant women, patients with systemic diseases and on steroid therapy or those unwilling to give written informed consent were excluded from the study.

All the subjects recruited for the study were informed regarding the same and written consent was obtained. The patients were divided into 2 groups. Group I patients comprised of those who received Nobel Active dental implants (Nobel Biocare) and Group II patients received Noris Tuff TT dental implants (Noris Medical Pvt. Ltd.). The reason why these two implant systems were chosen in the purview of the study, among the pool of various other systems available can be attributed to the fact that these two systems have similar external geometry of thread design.

All the dental implant were inserted by same clinical team comprising of a faciomaxillary surgeon (NA) and periodontist (RA) following standardized operating surgical protocols. The prosthetic part was prepared by the same technician (R.R. Dental Lab). Following the dental implant insertion, Intraoral Periapical Radiographs (IOPAR) were taken with the same calibrated machine following the paralleling technique using size 2 x-ray films. The patients were recalled periodically in accordance to the Merin's classification of patient scheduling and radiographs of the same site were obtained after 2 years.

Upper edge of the implant shoulder in initial radiograph and the distance between abutment and implant was regarded as reference line. In initial radiographs, the distance from the contact point of the implant and bone to the reference line and the distance from the CEJ of the adjacent tooth to the contact point of the crestal bone and tooth were measured. In follow up radiographs, the distance from the contact point of the crestal bone and implant to the reference line and the distance from the CEJ of the adjacent tooth to the contact point of the crestal bone and tooth were measured. The distance from the contact point of the implant restoration and the adjacent tooth to the crestal bone was also calculated.

JEMT index (Figure 1) was used to measure presence of interdental papilla between implant and adjacent teeth in follow up period (after 2 years). All the measurements were performed by two independent clinicians following astute training of the examiners (RA and VK). Cohen's Kappa (unweighted) statistic yielded a strong level of agreement (0.90) between the two examiners. The mean of their values was considered to further

overcome interobserver bias. A digital Vernier caliper was used for measurements in mm.

Papilla index (PI) grading was used. Score 0 depicted no papilla in the interproximal space, score 1 was presence of less than 50% of the papilla height, score 2 had presence of at least 50% of the papilla height but not all the interproximal space, score 3 showed the papilla completely fills the interproximal space and is coordinated by the adjacent papilla with a favorable gingival contour and score 4 had the hyperplastic papillae that covers too much of the single implant restoration and/or the adjacent tooth, with unfavorable gingival contour was used.

The data was compiled in Microsoft Excel spreadsheet and subjected to necessary statistical analysis. The normality of the data was assessed using Shapiro-Wilk test and the data was found amenable to parametric inferential statistics.

Intergroup comparisons were analyzed using the paired t-test and the intragroup comparisons were judged using the Student's t-test. The level of significance (α) was set a-priori, at 5% ($p < 0.05$) with the power of the study ($1 - \beta$) at 80%.

Results

The results are elaborated in Table I and III. Group I, mean distances from the implant shoulder to the crestal bone on mesial side was 1.22 mm initially and 1.8 mm after 2 years. On distal side, it was 0.82 initially and 2.3 mm after 2 years. In group II, mean distances from the implant shoulder to the crestal bone on mesial side was 1.8 mm initially and 3.1 mm after 2 years.

On distal side, it was 1.6 mm initially and 2.2 mm after 2 years. The difference was significantly ($P < 0.05$) on distal side in group I. The mean distance between the CEJ of the adjacent tooth and the crestal bone in group I initially on mesial side was 2 mm and 2.6 mm after 2 years, on distal side it was 2.2 mm initially and 2.4 mm after 2 years.

In group II, it was 2.1 mm initially and 2.5 mm after 2 years on mesial side. It was 2.5 mm initially and 2.7 mm after 2 years on distal side. The difference was non-significant ($P > 0.05$) (Graph I). Mean bone loss adjacent to implant shoulder in group I was 1.34 mm and 0.72 mm in group II. The difference was non-significant ($P > 0.05$).

Figure 1: Jemt T. Int J Periodontics Restorative Dent. 1997 Aug;17(4):326-33

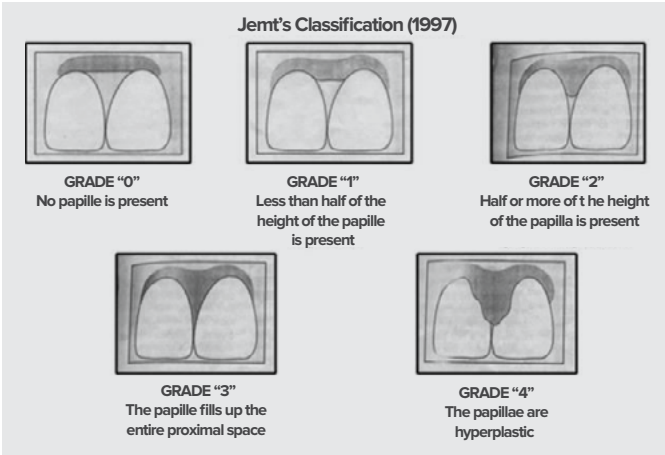


Table I : Intragroup comparison of mean distances (mm) from the implant shoulder to the crestal bone

Group I (Nobel Active)	Mesial	1.22	1.8	0.5
	Distal	0.82	2.3	0.01*
Group II (Noris Tuff)	Mesial	1.8	3.1	0.08
	Distal	1.6	2.2	0.1

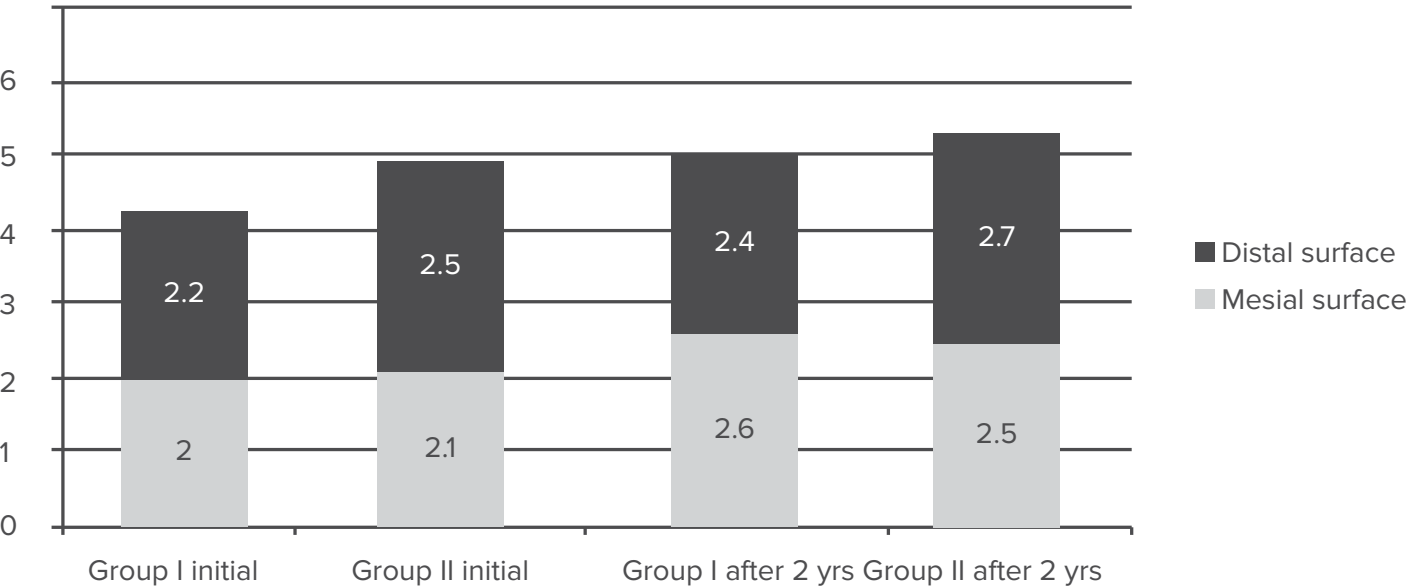
Paired t-test. * Indicates Statistical Significance. (p> 0.05)

Table II : Intergroup comparison of mean distances (mm) from the implant shoulder to the crestal bone

	Interdental papilla height (mm)	Group I (Nobel Active)	Group II (Noris Tuff)	P value
Initial IOPAR	Mesial	1.22	1.8	0.2
	Distal	0.82	1.6	0.3
2 Years	Mesial	1.8	3.1	0.5
	Distal	2.3	2.2	0.07

Unpaired Student t-test.

Graph I: Comparison of the mean distance between the CEJ of the adjacent tooth and the crestal bone



Discussion

Teeth are lost due to various reasons such as a result of trauma, dental caries, and periodontitis or due to orthodontic reasons. Dental implant therapy is widely used nowadays.

The higher survival rate is one of the reasons for its popularity. The successful implant therapy is based on its ability to restore esthetics as well as functions.⁵ It should mimic the natural teeth and perform all required functions such as eating, biting, chewing etc. Maxillary anterior tooth region is favorable site for dental implant. The presence of sufficient bone height in this region favours dental implant therapy. Moreover, maxillary anterior region shows type I bone which is suitable for dental implants. Dental implants in maxillary anterior region are less subjected to occlusal forces. The height of interdental papilla also determines the dental implant success rate.⁶ Many studies have been conducted which evaluate factors affecting bone loss around dental implants. Very few studies have been performed so far which shows importance of dental papilla as key factor in deciding outcome of dental implants.^{7,8} Considering this, the present study was conducted to compare the amount of soft tissues around Nobel Active and Noris Tuff TT dental implant systems.

Chang M et al⁹ in their study revealed that interdental papilla formation is greatly depends on distance between dental implant and natural teeth and anatomy of adjacent teeth. Grunder U¹⁰ suggested that bone level around dental implant determines the presence of interdental papilla between implant and natural teeth.

In present study we included 28 patients of both genders having 32 dental implants. All were the cases of maxillary anterior region. We used Nobel Active dental implants in group I and Noris Tuff TT dental implants in group II. We observed that the mean distances from the implant shoulder to the crestal bone was 1.22 mm initially which become 1.8 mm after 2 years in group I on mesial side. It was 0.82 initially and 2.3 mm after 2 years on distal side. Similarly, the mean distance from the implant shoulder to the crestal bone was 1.8 mm initially and 3.1 mm after 2 years on mesial side and 1.6 mm initially and 2.2 mm after 2 years on distal side. Our results are in accordance to the study of Henriksson K et al.¹¹ In their study, the height of interdental papilla around dental implants was compared.

In present study, there was no significant bone loss in either of dental implant systems. Our results are in tandem with the study by Bratuet al¹² who performed a prospective study to evaluate the level of bone loss around micro- threaded dental implants and found that there was significantly less bone loss in dental implants having micro- threads. Studies have demonstrated that micro- threaded dental implants tend to deliver stress at crestal bone. It was found that rough dental implants with micro- threads are helpful in maintaining crestal bone level as compared to non threaded dental implants.^{13,14}

We observed that on mesial side the mean distance between the CEJ of the adjacent tooth and the crestal bone was 2 mm initially and 2.6 mm after 2 years

whereas on distal side it was 2.2 mm initially and 2.4 mm after 2 years in group I.

In group II, it was 2.1 mm initially and 2.5 mm after 2 years on mesial side. It was 2.5 mm initially and 2.7 mm after 2 years on distal side. However, the difference in both groups found to be non- significant. Kan JY et al¹⁵ in their study on 6 dental implant system found that interdental papilla are greatly affected by the around of crestal bone level in adjacent teeth.

Choquet et al¹⁶ in their study assessed the level of interdental papilla around single maxillary anterior dental implant both clinically as well as radiographically. Authors found that in cases where there was >6mm distance between alveolar crest and contact point, the interdental papilla was seen in all cases whereas when it was <5mm, only half of cases showed interdental papilla.

Ozdemir et al¹⁷ in their study included 33 immediate dental implants and adjacent implants. The level of interdental papilla height was measured using Pink esthetic score at 1 week, 1 month and 4 months. Authors concluded that immediate dental implants and loading are effective in maintaining soft tissue health such as interdental papilla.

Similarly, the study by Mankoo et al¹⁸ in their 2-7 years follow up study on 10 dental implants placed in esthetic zone suggested the role of labial tissue thickness and tissue biotype in dental implant therapy in maxillary anterior region.

The limitation of the study was small sample size. Only Noble Active and Noris Tuff TT types of dental implants were included. Further studies are warranted to elucidate fortified results in different study settings and populations. Keeping the congruency of the gingival biotype and studies depicting survival analysis data could prove to be a cornerstone in research within this paradigm and vista.

Conclusion

Authors found relation between presence of papilla and the distance of the contact point of the implant restoration and the adjacent tooth to the crestal bone. The amount of bone loss in both groups was not significant.

Clinical Significance

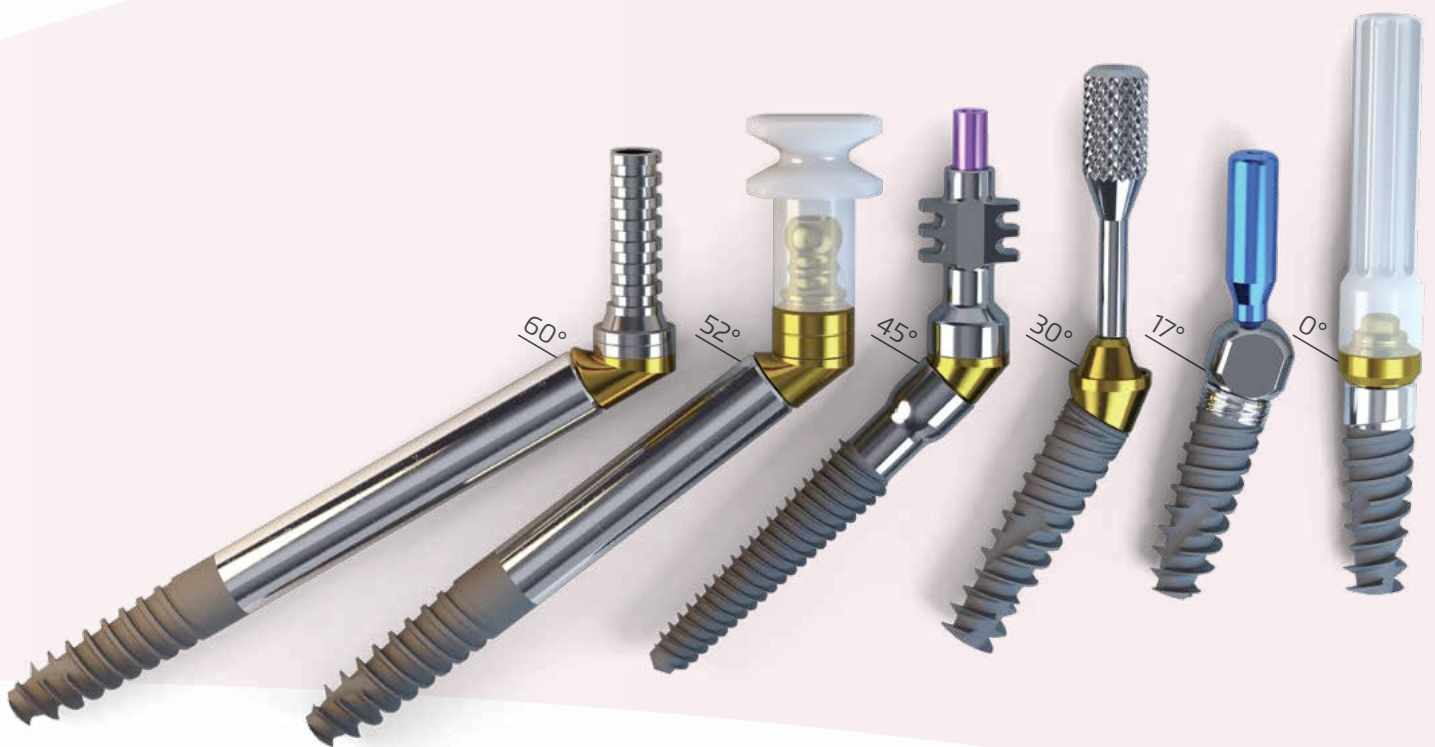
The preservation of interdental papilla is of paramount importance for predictable results and successful dental implant therapy.

References

1. Grey E B, Harcourt D, O'Sullivan D, Buchanan H, Kilpatrick N M. A qualitative study of patients' motivations and expectations for dental implants. *Br Dent J* 2013; 214: 1.
2. Fardal, Grytten J. A comparison of teeth and implants during maintenance therapy in terms of the number of disease-free years and costs-an in vivo internal control study. *J Clin Periodontol* 2013; 40: 645–651.
3. Clementini M, Rossetti P H, Penarrocha D, Micarelli C, Bonachela W C, Canullo L. Systemic risk factors for peri-implant bone loss: a systematic review and meta-analysis. *Int J Oral Maxillofac Surg* 2014; 43:323–334.
4. Gatti C, Gatti F, Chiapasco M, Esposito M. Outcome of dental implants in partially edentulous patients with and without a history of periodontitis: a 5-year interim analysis of a cohort study. *Eur J Oral Implantol* 2008;1(1):45-51.
5. Turkyilmaz I, McGlumphy EA. Influence of bone density on implant stability parameters and implant success: a retrospective clinical study. *BMC Oral Health* 2008;8:32.
6. Chow YC, Wang HL. Factors and techniques influencing peri-implant papillae. *Implant Dentistry*. 2010; 19: 208–219.
7. Bruno V, Badino M, Sacco R, Catapano S. The use of a prosthetic template to maintain the papilla in the esthetic zone for immediate implant placement by means of a radiographic procedure. *Journal of Prosthetic Dent*. 2012; 108: 394-397.
8. Salama H, Salama M, Garber D, Adar P. Developing optimal peri-implant papillae within the esthetic zone: guided soft tissue augmentation. *J Esthet Dent* 1995;7(3):125-9.
9. Chang M, Wennstrom JL, Odman P, Andersson B. Implant supported single-tooth replacements compared to contralateral natural teeth. Crown and soft tissue dimensions. *Clin Oral Implants Res*. 1999;10(3):185-94.
10. Grunder U. Stability of the mucosal topography around single-tooth implants and adjacent teeth: 1-year results. *Int J Periodontics Restorative Dent*. 2000;20(1):11-7.
11. Henriksson K, Jemt T. Measurements of soft tissue volume in association with single-implant restorations: a 1-year comparative study after abutment connection surgery. *Clin Implant Dent Relat Res*. 2004;6(4):181-9.
12. Bratu EA, Tandlich M, Shapira L. A rough surface implant neck with microthreads reduces the amount of marginal bone loss: a prospective clinical study. *Clin Oral Implants Res*. 2009; 20(8):827-32.
13. Pradeep AR, Karthikeyan BV. Peri-implant papilla reconstruction: realities and limitations. *J Periodontol*. 2006;77(3):534-44.
14. Schrotenboer J, Tsao YP, Kinariwala V, Wang HL. Effect of microthreads and platform switching on crestal bone stress levels: a finite element analysis. *J Periodontol*. 2008;79(11):2166-72.
15. Kan JY, Rungcharassaeng K. Interimplant papilla preservation in the esthetic zone: a report of six consecutive cases. *Int J Periodontics Restorative Dent*. 2003;23(3):249-59.
16. Choquet V, Hermans M, Adriaenssens P, Daelemans P, Tarnow DP, Malevez C. Clinical and radiographic evaluation of the papilla level adjacent to single-tooth dental implants. A retrospective study in the maxillary anterior region. *J Periodontol* 2001;72(10):1364-71.
17. Ozdemir E, Yener Oguz. The effect of immediate implant placement and immediate loading on interdental papillae heights in single implants and adjacent implants. *OHDM* 2015; 14 (2): 104- 108.
18. Mankoo T. Maintenance of interdental papillae in the esthetic zone using multiple immediate adjacent implants to restore failing teeth – a report of ten cases at 2 to 7 years follow-up. *Eur J Esthet Dent* 2008;3:304–322.

Clinical Challenges

Total Solutions
for ***Total Care***



A NEW SPIRAL DENTAL IMPLANT: A TOOL FOR ORAL REHABILITATION OF DIFFICULT CASES

I. BALAN¹, R. CALCATERRA², D. LAURITANO³, E. GRECCHI⁴, F. CARINCI⁵

¹Private practice in Israel

²Department of Clinical Sciences and Translational Medicine, University of Tor Vergata, Rome, Italy

³Department of Medicine and Surgery, University of Milan-Bicocca, Milan, Italy

⁴Department of Oral Surgery, IRCCS Fondazione Ca' Granda, Ospedale Maggiore Policlinico, Milan, Italy

⁵Department of Morphology, Surgery and Experimental Medicine, University of Ferrara, Ferrara, Italy

SUMMARY

Spiral dental implant (SDI) is an implant with a conical internal helix that confers the characteristic of self-drilling, self-tapping, and self-bone condensing. These proprieties offer better control during insertion of SDI giving a high primary stabilization, even in poor quality bone. A shorter diameter of SDI results in reduced drilling during insertion and consequently less trauma and minimal bone loss. To address the research purpose, the investigators designed a retrospective cohort study. The study population was composed of 25 patients, 11 males and 14 females that have been treated by Dr. Balan with 187 SDI positioned in mandible and into maxilla bone. The implants were placed during the years 2013 to 2014 in Dr. Balan clinic.

All patients underwent the same surgical protocol. Several variables are investigated: demographic (age and gender), anatomic (upper/lower jaws and tooth site), implant (length and diameter and type) variables, edentulism (partial or total), and comorbid status of health (i.e.: hypothyroidism, parodontitis, hypertension, diabetes, presence of cancer, heart disease, hepatitis and rheumatologic disease). Pearson Chi-Square test was used to investigate variables and $p < 0.05$ was considered statistically significant.

Statistically it has been shown that females have a higher possibility of unsuccessful respect of male, with a "p value" of 0.014.

Another important impact factor for success of implant insertion has been represented by concomitants pathologies: cancer represents the most negative high factor risk with a percentage of unsuccessful of 50%, followed by heart disease (15%), and diabetes (3.7%).

SDIs are reliable tools for difficult cases of oral rehabilitation. They have a higher success and survival rate, which means stable results over time. No differences were detected among SDI lengths, implant/crown ratio. In addition, the insertion of SDIs in banked bone can be performed without adverse effects. Finally, flapless and computer tomography-planned surgery does not significantly increase the clinical outcome of SDIs in complex rehabilitation. Cancer represents the most important variable to consider when a patient wants to do oral rehabilitation because of its high risk of unsuccessful.

Key words: implant dentistry, spiral implants, bone, helix design, survival rate.

Introduction

Spiral dental implant (SDI) is a conical internal helix implant with a variable thread design that confers the characteristic of self-drilling, self-tapping, and self-bone condensing (1-3). These proprieties offer better control during insertion of SDI giving a high primary stabilization, even in poor quality bone. A shorter diameter of SDI results in reduced drilling during insertion and consequently less trauma and minimal bone loss. Position and orientation of SDI can be changed even after initial insertion without trauma to the alveolar bone tissues. These properties of SDI are particularly useful in case of bone atrophy, in low bone density, or in freshly extracted sites and thin sinus floors elevation without prior bone augmentation. Implant placement requires an adequate

quantity and quality of bone (4-12). The selfdrilling capability of the SDI allows it to be inserted into sites with reduced depth. This characteristic of SDI is very useful for implant surgeon when implant must be inserted in proximity to anatomic structures such as the mandibular nerve canal or the maxillary sinus and nose cavity.

Some studies have proven the SDIs to be highly successful (13-16). However, to achieve this predictable success, a specific protocol for SDI should be followed. Researches have challenged several aspects of this specific protocol, and their investigations found the relative importance of helix design on osseointegration. Therefore, the identification of guidelines for the long-term success (i.e., total implants still in place at the end of the follow-up, good clinical, radiologic, and aesthetic outcome) has been to achieve good clinical outcome (17-20).

Many variables may influence the clinical outcome of SDI: surgery protocol, bone quality and quantity, helix design, and occlusion (21-25). Surgery-related factors comprise several variables such as an excess surgical trauma like flap, bone thermal injury, and irrigation. Bone quality and quantity are the most important host-related factors, while helix design, surface coating, and length are the strongest implant-related factors. Finally prosthetic restoration and occlusion-related factors may affect the clinical outcome.

Surgery-related factors

Flapless implant surgery is easy to perform since the helix design allows a simpler penetration into bone of SDI. With this blind procedure, the surgeon may run the risk to deviate SDI. The use of radiographic images is necessary to evaluate the surgical site underneath the soft tissue, and computer tomography images provide an accurate 3D picture of the surgical field. In addition, several Authors have advocated the use of drill guides for SDI insertion to link the virtual preoperative treatment plan based on the computer tomography images to the situation encountered during surgery (18, 19).

Bone quality and quantity

Bone quality and quantity, a host-related factor, is believed to be the strongest predictor of outcome in SDIs. Some studies have reported that most of the immediately loaded implants are placed in anatomic sites with bone quality D1 or D2 (16, 17, 26). No differences were detected between implants inserted in native and grafted bone. Some papers on clinical outcome of SDIs reported no statistical difference with regard to anatomic sites (mandible vs maxilla or tooth site) or surgery-related factors (i.e., surgeon, flapless surgery, computed tomography- planned, and post extraction sites).

Prosthetic-related variables

Several prosthetic-related variables were reported: loading time, situation of antagonist arch, and implant/crown ratio; this variable was statistically significant with a worse outcome for full arches loading few implants.

Several reports have appeared in the last decade and good medium-term success rate of SDIs has been reported. The effectiveness of these types of SDI was demonstrated in several clinical situations (25).

However, because there are no reports about survival rate of SDI we therefore decide to perform a retrospective study on 187 SDIs.

Materials and methods

Study design/sample

To address the research purpose, the investigators designed a retrospective cohort study. The study population was composed of 25 patients, 11 males and 14 females that have been treated by Dr. Balan with 187 SDI positioned in mandible and into maxilla bone. The implants were placed during the years 2013 to 2014 in Dr. Balan clinic.

Subjects were screened according to the following inclusion criteria: controlled oral hygiene, the absence of any lesions in the oral cavity; in addition, the patients had to agree to participate in a post-operative check-up program.

The exclusion criteria were as follows: bruxism, smoking more than 20 cigarettes day and consumption of more than 2 glass of wine per day, localized radiation therapy of the oral cavity, blood and kidney diseases.

Pre-operative medication protocol

An antimicrobial prophylaxis was administered with 500 mg amoxicillin twice daily for 5 days One hour prior to dental surgery: 1g Augmentin (amoxicillin and clavulanate potassium) for patients who are allergic to penicillin - 600 mg Dalacin (clindamycin); 12 mg dexamethasone (not for diabetics); 20 mg Vaben (oxazepam); 100 mg Otarex (hydroxyzine hydrochloride); 2 tab Narocin 275 mg (naproxen); 1 cap Losec 20 mg (omeprazole); Probiotic.

Implant surgery

All patients underwent the same surgical protocol. Local anesthesia was induced by infiltration with articaine/ epinephrine and post-surgical analgesic treatment was performed with 100 mg nimesulid twice daily for 3 days. Oral hygiene instructions were provided.

After a crestal incision a mucoperiosteal flap was elevated. Implants were inserted according to the procedures recommended. The implant platform was positioned at the alveolar crest level. Sutures were removed 14 days after surgery.

The provisional prosthesis is delivered on the same day of the operation and the final restoration was usually delivered within an additional 6 months. All patients were included in a strict hygiene recall.

Post-operative medication protocol

Antibiotics: Moxypen (amoxicillin) 500 mg 3 times a day/ Augmentin 500/875 3 or 2 times a day/Dalacin 300 mg 3 times a day, for 7 days; 0.12% Chlorhexidine rinse for a month; 400 mg Ibuprofen every 4 hours, if needed; Dexamethasone, starting with 12 mg daily and reducing 2 mg each following day, botox (dilute according to manufacturer's instructions, divide to 6 doses, inject to the masseter muscle in 3 points along the muscle, in each side).

Variables

Several variables are investigated: demographic (age and gender), anatomic (upper/lower jaws and tooth site), implant (length and diameter and type) variables, edentulism (partial or total), comorbid status of health (i.e.: hypothyroidism, parodontitis, hypertension, diabetes, presence of cancer, heart disease, hepatitis and rheumatologic disease).

Primary and secondary predictors of clinical outcome were used. The primary predictor is the presence/absence of the implant at the end of the observation period. It is defined as survival rate (i.e., SVR) that is the total number of implants still in place at the end of the follow-up period. The second predictor of outcome was the periimplant bone resorption. It is defined as implant success rate (SCR and it is evaluated according to the absence of persisting peri-implant bone resorption greater than 1.5 mm during the first year of loading and 0.2 mm per year during the following years (24).

Data collection methods and summary of operative methods

Before surgery, radiographic examinations were done with the use of orthopantomography (Figure 1).

In each patient, peri-implant crestal bone levels were evaluated by the calibrated examination of orthopantomography X-rays. Measurements were recorded after surgery (Figure 2) and at the end of the follow-up period (Figure 3). The measurements were carried out mesially and distally to each implant, calculating the distance between the implant' platform and the most coronal point of contact between the bone and the implant. The bone level recorded just after the surgical insertion of the implant was the reference point for the following measurements.

The measurement was rounded off to the nearest 0.1 mm. A peak Scale Loupe with a magnifying factor of seven times and a scale graduated in 0.1 mm was used.

The difference between the implant-abutment junction and the bone crestal level was defined as the Implant Abutment Junction (IAJ) and calculated at the time of operation and during follow-up.

The delta IAJ is the difference between the IAJ at the last check-up and the IAJ recorded just after the operation. Delta IAJ medians were stratified according to the variables of interest.

Peri-implant probing was not performed because controversy still exists regarding the correlation between probing depth and implant success rates (24, 25).

Data analysis

Pearson Chi-Square test was used to investigate variables and $p < 0.05$ was considered statistically significant.

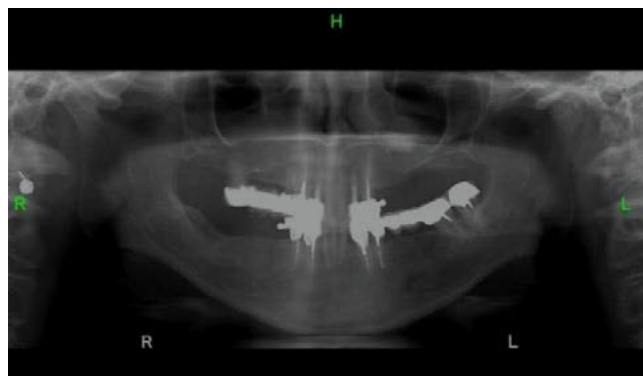


Figure 1
Pre-operative Rx opt.

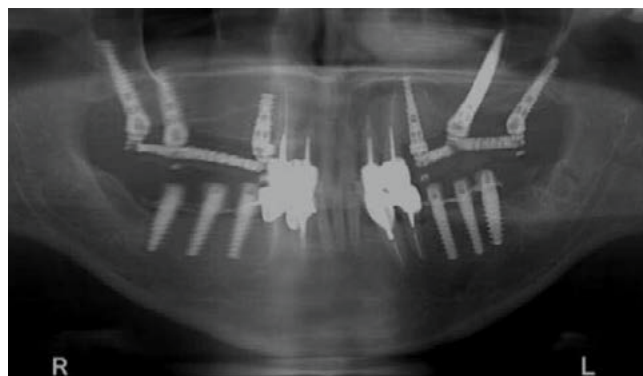


Figure 2
Rx opt in the immediate post-operative (t0).

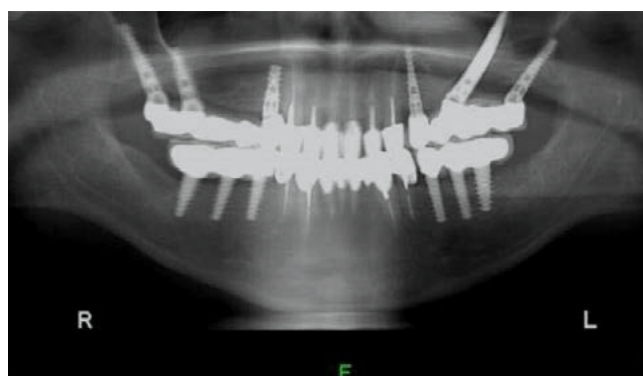


Figure 3
Rx opt after 11 months of follow-up.

Results

Twenty-five patients, 11 males and 14 females, treated by Dr. Balan with 187 SDI with a medium age of 58.4 years have the inclusion criteria and were enrolled in the present study. Informed written consent approved by the local Ethics Committee was obtained from patients to use their data for research purposes. The mean post loading follow-up was 8.7 ± 2.5 months. One hundred and ten implants (58.8%) were inserted in females, 77 (41.2%) in males. A total of 187 implants was inserted into 25 patients: 73 (39.0%) into the mandible and 114 (61%) into the maxilla.

There were 187 NORIS Medical Ltd dental Implant system (Israel):166 Tuff 21 Cortical. They were inserted because of atrophy of the bone in 97 cases (51.9%), periodontitis in 78 cases (41.7 %) and 12 (6.4%) in post extraction for caries.

Implant length and diameter ranged from 8 mm to 16 mm (standard was 11.5 mm) and from 3.75 mm to 6.0 mm, (standard was considered 3.75 mm) respectively.

There were 40 standard length fixtures (i.e. 11.5 mm), 33 short and 114 long implants. There were 79 standard diameter fixtures (i.e. 3.75 mm) and 108 wide implants. Implants were inserted to replace 51 incisors, 26 cuspids, 49 premolars and 61 molars.

One hundred and fifty-three implants were inserted in totally edentulous patients, and 34 in partially edentulous patients.

Considering the presence of comorbidity, the most percentage of SDI were inserted in healthy patients (58.8%), while 27 (14.4%) implants were inserted in diabetic patients, 19 (10.2%) in patients with heart disease, 21 (11.2 %) in hypothyroid, and finally 10 (5.3%) in patients with cancer. Seventy-three (39%) implants were inserted in mandibular bone. One hundred and fourteen (61%) implants were inserted in maxilla bone. No implant was lost in the post-operative period. Every variable has been studied with Pearson Chi-Square test, to investigate which of these can compromise the successful rate of the insertion of SDI.

Statistically it has been shown that females have a higher possibility of unsuccessful respect of males, with a "p value" of 0.014. Another important impact factor for success of implant insertion has been represented by concomitants pathologies: cancer represents the most negative high factor risk with a percentage of unsuccessful of 50%, followed by heart disease (15%), and diabetes (3.7%).

Discussion

Primary implant stability and bone density are variables considered essential to achieve predictable osseointegration and long-term clinical survival of SDIs. For osseointegration of SDI, not only adequate bone quantity is required, but adequate density is also needed. The initial bone density not only provides mechanical immobilization of the SDI during healing, but also permits distribution and transmission of stresses from the prosthesis to the implant bone interface. The mechanical distribution of stress occurs primarily where bone is in contact with the SDI (16-18, 26). One study demonstrated that when maximum stress concentration occurs in cortical bone, it is located in the area of contact with the thread of helix, and when the maximum stress concentration occurs in trabecular bone, it occurs around the apex of the helix (25). Besides the success rate of SDIs is above 80%, peri-implantitis may occur in oral rehabilitations of difficult cases also. Peri-implantitis and periodontal disease spring from bacterial infection that activates a cytokines cascade leading to inflammation and bone loss (27-31).

In addition, the patient-related susceptibility is a critical factor for disease onset. So, every factor favouring oral biofilm formation (poor oral hygiene), host defence capability (smoking habit, excessive alcohol consumption, genetic traits, history of periodontitis, oral mucosal lesions and prosthetics), might favour developing of peri implantitis and periodontal disease in SDIs, which diagnosis and treatment require dentist's engagement (32-39).

Conclusion

In conclusion, SDIs are reliable tools for difficult cases of oral rehabilitation. They have a higher success and survival rate, which means stable results over time. No differences were detected among SDI lengths, implant/crown ratio.

In addition, the insertion of SDIs in banked bone can be performed without adverse effects. Finally, flapless and computer tomography-planned surgery does not significantly increase the clinical outcome of SDIs in complex rehabilitation. Considering risks factors above all health status and female sex seems to be mandatory for the success of SDI. Nowadays we should keep in touch that cancer represents the most important variable to consider when patients wants to do oral rehabilitation because of its high risk of unsuccessful.

References

1. Danza M, Paracchini L, Carinci F. Tridimensional finite element analysis to detect stress distribution in implants. *Dental Cadmos*. 2012;80:598-602.
2. Danza M, Grecchi F, Zollino I, et al. Spiral implants bearing full-arch rehabilitation: Analysis of clinical outcome. *Journal of Oral Implantology*. 2011;37:447- 455.
3. Danza M, Zollino I, Avantaggiato A, et al. Distance between implants has a potential impact of crestal bone resorption. *Saudi Dental Journal*. 2011;23:129-133.
4. Baj A, Trapella G, Lauritano D, et al. An overview on bone reconstruction of atrophic maxilla: success parameters and critical issues. *J Biol Regul Homeost Agents*. 2016;30:209-215.
5. Grecchi F, Perale G, Candotto V, et al. Reconstruction of the zygomatic bone with smartbone®: Case report. *Journal of Biological Regulators and Homeostatic Agents*. 2015;29:42-47.
6. Lauritano D, Avantaggiato A, Candotto V, et al. Insulin activity on dental pulp stem cell differentiation: An in vitro study. *Journal of Biological Regulators and Homeostatic Agents*. 2015;29:48-53.
7. Tettamanti L, Andreasi Bassi M, Trapella G, et al. Applications of biomaterials for bone augmentation of jaws: Clinical outcomes and in vitro studies. *ORAL and Implantology*. 2017;10:37-44.

8. Baj A, Sollazzo V, Lauritano D, et al. Lights and shadows of bone augmentation in severe resorbed mandible in combination with implant dentistry. *Journal of Biological Regulators and Homeostatic Agents*. 2016;30:177-182.
9. Lauritano D, Avantaggiato A, Candotto V, et al. Effect of somatostatin on dental pulp stem cells. *Journal of Biological Regulators and Homeostatic Agents*. 2015;29: 54-58.
10. Baj A, Muzio LL, Lauritano D, et al. Success of immediate versus standard loaded implants: A short literature review. *Journal of Biological Regulators and Homeostatic Agents*. 2016;30:183-188.
11. Calcaterra R, Di Girolamo M, Mirisola C, et al. Effects of Repeated Screw Tightening on Implant Abutment Interfaces in Terms of Bacterial and Yeast Leakage in Vitro: One-Time Abutment Versus the Multiscrewing Technique. *Int J Periodontics Restorative Dent*. 2016;36:275-280.
12. Calcaterra R, Pasquantonio G, Vitali LA, et al. Occurrence of *Candida* species colonization in a population of denture-wearing immigrants. *Int J Immunopathol Pharmacol*. 2013;26:239-246.
13. Carinci F, Danza M. Clinical outcome of implants inserted in piezo split alveolar ridges: A pilot study. In: eds. *Perspectives on Clinical Dentistry*. 2011:29-30.
14. Danza M, Zollino I, Guidi R, et al. Computer planned implantology: Analysis of a case series. In: eds. *Perspectives on Clinical Dentistry*. 2011:287-300.
15. Danza M, Carinci F. Flapless surgery and immediately loaded implants: a retrospective comparison between implantation with and without computer-assisted planned surgical stent. *Stomatologija*. 2010;12:35-41.
16. Danza M, Quaranta A, Carinci F, et al. Biomechanical evaluation of dental implants in D1 and D4 bone by Finite Element Analysis. *Minerva stomatologica*. 2010; 59:305-313.
17. Carinci F, Danza M. Clinical outcome of implants inserted in piezo split alveolar ridges: A pilot study. *International Journal of Clinical Dentistry*. 2009;2:219- 229.
18. Danza M, Fromovich O, Guidi R, et al. The clinical outcomes of 234 spiral family implants. *J Contemp Dent Pract*. 2009;10:E049-056.
19. Danza M, Zollino I, Guidi R, et al. Computer planned implantology: Analysis of a case series. *International Journal of Clinical Dentistry*. 2009;2:121-134.
20. Carinci F, Brunelli G, Danza M. Platform switching and bone platform switching. *J Oral Implantol*. 2009;35: 245-250.
21. Danza M, Guidi R, Carinci F. Comparison between implants inserted into piezo split and unsplit alveolar crests. *J Oral Maxillofac Surg*. 2009;67:2460-2465.
22. Danza M, Scarano A, Zollino I, et al. Evaluation of biological width around implants inserted in native alveolar crest bone. *Journal of Osseointegration*. 2009;1:73- 76.
23. Danza M, Zollino I, Guidi R, et al. A new device for impression transfer for non-parallel endosseous implants. *Saudi Dental Journal*. 2009;21:79-81.
24. Danza M, Zollino I, Carinci F. Comparison between implants inserted with and without computer planning and custom model coordination. *J Craniofac Surg*. 2009;20:1086-1092.
25. Danza M, Guidi R, Carinci F. Spiral family implants inserted in postextraction bone sites. *Implant Dent*. 2009;18:270-278.
26. Danza M, Riccardo G, Carinci F. Bone platform switching: a retrospective study on the slope of reverse conical neck. *Quintessence Int*. 2010;41:35-40.
27. Lauritano D, Martinelli M, Mucchi D, et al. Bacterial load of periodontal pathogens among Italian patients with chronic periodontitis: A comparative study of three different areas. *Journal of Biological Regulators and Homeostatic Agents*. 2016;30:149-154.
28. Lauritano D, Cura F, Gaudio RM, et al. Polymerase Chain Reaction to Evaluate the Efficacy of Silica Dioxide Colloidal Solutions in the Treatment of Chronic Periodontitis: A Case Control Study. *J Biol Regul Homeost Agents*. 2015;29:131-135.
29. Andreasi Bassi M, Lopez MA, Confalone L, et al. Clinical outcome of a two-piece implant system with an internal hexagonal connection: a prospective study. *J Biol Regul Homeost Agents*. 2016;30:7-12.
30. Lauritano D, Cura F, Candotto V, et al. Evaluation of the Efficacy of Titanium Dioxide with Monovalent Silver Ions Covalently Linked (Tiab) as an Adjunct to Scaling and Root Planing in the Management of Chronic Periodontitis Using Pcr Analysis: A Microbiological Study. *J Biol Regul Homeost Agents*. 2015; 29:127-130.
31. Fanali S, Carinci F, Zollino I, et al. A retrospective study on 83 one-piece implants installed in resorbed maxillae. *European Journal of Inflammation*. 2012; 10:55-58.
32. Scarano A, Sinjari B, Di Orio D, et al. Surface analysis of failed oral titanium implants after irradiated with ErCr:ysgg 2780 laser. *European Journal of Inflammation*. 2012;10:49-54.
33. Scarano A, Murmura G, Carinci F, et al. Immediately loaded small-diameter dental implants: evaluation of retention, stability and comfort for the edentulous patient. *European Journal of Inflammation*. 2012;10:19-23.
34. Lauritano D, Bignozzi CA, Pazzi D, et al. Efficacy of a new coating of implantabutment connections in reducing bacterial loading: An in vitro study. *ORAL and Implantology*. 2017;10:1-10.
35. Andreasi Bassi M, Serra S, Andrisani C, et al. Polymerization shrinkage and spherical glass mega fillers: Effects on cuspal deflection. *ORAL and Implantology*. 2016;9:71-79.

36. Andreasi Bassi M, Andreasi Bassi S, Andrisani C, et al. Light diffusion through composite restorations added with spherical glass mega fillers. *ORAL and Implantology*. 2016;9:80-89.
37. Avantaggiato A, Palmieri A, Carinci F, et al. Effects of glucosamine and nucleotide association on fibroblast: extracellular matrix gene expression. *International journal of immunopathology and pharmacology*. 2014;27: 689-693.
38. Lauritano D, Arrica M, Lucchese A, et al. Oral lichen planus clinical characteristics in Italian patients: a retrospective analysis. *Head Face Med*. 2016;12:18.
39. Lauritano D, Petruzzi M, Nardi GM, et al. Single Application of a Dessicating Agent in the Treatment of Recurrent Aphthous Stomatitis. *J Biol Regul Homeost Agents*. 2015;29:59-66.

Correspondence to:

Francesco Carinci

Department of Morphology,
Surgery and Experimental Medicine,
University of Ferrara
Via Luigi Borsari 46
Ferrara, Italy

Phone: +39.0532.455874

E-mail: crc@unife.it



Original Article

Evaluation of patient satisfaction and masticatory performance in mandible single implant-assisted overdenture

Swati Kashyap, Sanjeev Mittal*, Navneet Sharma, Urvashi Sukhija, Mohit Kamra, Nitika Gupta

Department of Prosthodontics,
MM College of Dental Sciences
and Research, Mullana, Haryana,
India

ABSTRACT

Objectives: Many authors have advocated a minimum of two implants to support a mandibular overdenture, but financial restraints specifically among the geriatric population in developing countries made this treatment plan economically difficult. Hence, this study was planned to assess the symphyseal (midline) single implant-assisted complete overdenture for patient satisfaction and masticatory performance. **Materials and Methods:** In this clinical study, 12 edentulous first-time denture wearers underwent placement of a single implant in the mandibular symphyseal region. After 1 week, new complete denture were fabricated and delivered to the patients. Post 3 months, the denture was fixed with a nylon cap-ball attachment to the anchor implant. Patients were questioned about comparison in the level of satisfaction and complaint before loading the implant (control group) and after 1 week, 1 month, and 3 months. The implant-assisted overdenture was fabricated with the help of a questionnaire. Masticatory performance was calculated with the help of a bite force measuring device at the same time intervals. SPSS 17.0 statistical software was used to analyze the data. **Results:** It was found that single implant anchorage of the mandibular complete denture resulted in a significant increase ($P < 0.05$) in patient's subjective satisfaction and a decrease ($P < 0.05$) in complaints at the end of 3 months. There was a significant ($P < 0.01$) increase in bite force in implant overdenture after 3 months (5.459 kgf) as compared to that of the complete denture (3.406 kgf). **Conclusion:** Single implant-assisted overdenture can be an appropriate treatment modality to treat edentulousness in the geriatric population. It insinuates the remarkable improvement of prosthesis function and oral comfort with minor surgical procedures.

KEYWORDS: Complete edentulous, Dental implant, Mandibular symphysis, Overdenture

Submission : 17-Sep-2020
Revision : 19-Nov-2020
Acceptance : 01-Feb-2021
Web Publication : 05-Apr-2021

INTRODUCTION

An agreeable dentition is of prime importance for a happy and healthy lifestyle. Regardless of various advances in preventive dentistry, edentulism is still a considerable problem all over the world. In the geriatric population, due to their mandibular ridge being more atrophied as compared to the maxillary one, they find a lack of retention, stability, and comfort in their mandibular denture [1]. They also suffer from denture soreness, unclear pronunciation, low chewing efficiency, and nutritional deficiency [2,3].

Although most edentulous patients appear to benefit from complete dentures and report satisfactory oral comfort and masticatory function, it is quite frequent to find patients who have lousy feeling dentures even though those dentures are prosthodontically acceptable [4]. Complete denture wearers needed four to eight times more chewing strokes than the

edentulous individual to attain the same degree of pulverization of the food. Among major factors, one which leads to decrease in chewing performance is the reduced bite force that denture wearers can develop owing to a lack of retention and stability of the denture [5].

An endosseous implant has been proved as a promising and viable treatment option for oral rehabilitation. Various studies have described an elevated rate of success related to placement and osseointegration of implants. The implant overdenture can be considered a secure and satisfactory method for the anchorage of denture prosthesis in an edentate population [6].

*Address for correspondence

Dr. Sanjeev Mittal
Department of Prosthodontics, MM College of Dental Sciences and Research, Mullana, Haryana, India
E-mail: ambaladental@yahoo.co

Access this article online	
Quick Response Code: 	Website: www.tcmjmed.com
	DOI: 10.4103/tcmj.tcmj_242_20

This is an open access journal, and articles are distributed under the terms of the Creative Commons Attribution-NonCommercial-ShareAlike 4.0 License, which allows others to remix, tweak, and build upon the work non-commercially, as long as appropriate credit is given and the new creations are licensed under the identical terms.

For reprints contact: WKHLRPMedknow_reprints@wolterskluwer.com

How to cite this article: Kashyap S, Mittal S, Sharma N, Sukhija U, Kamra M, Gupta N. Evaluation of patient satisfaction and masticatory performance in mandible single implant-assisted overdenture. Tzu Chi Med J 2021; 33(4): 406-11.

With guidance from The Glossary of Prosthodontic Terms [7], implant overdenture can be defined as removable complete or partial denture supported and retained in part or whole by a dental implant. Hence, implant overdenture may be either implant or implant-mucosa supported, depending on the number of implants and design of the prosthesis.

Many authors have done various studies regarding the minimum number of implants used for anchorage of a complete denture. They advocated a minimum of two implants to support a mandibular overdenture, but financial restraints specifically among the elderly population in developing countries made this treatment plan economically difficult [8].

As compared to the two implant-assisted overdenture, a single midline implant situated in the symphyseal area of the mandible has demonstrated to be more efficient in terms of cost, time, maintenance, and comparatively easier surgical approach which will be more beneficial to the economically unfit population, especially in India. Through an *in vitro* study, it was also verified that a single implant-assisted overdenture has more retention and stability as compared to that of a conventional one [8].

We can enhance the quality of life, improve patient satisfaction and masticatory efficiency with the use of implants but the minimum number used in this concept is still debatable. Efforts to reduce implant numbers are still ongoing. Few studies have shown that a single implant overdenture is superior to the conventional denture in terms of general satisfaction. So, this study was designed to evaluate patient satisfaction and bite force with a single midline implant-retained mandibular overdenture. The null hypothesis was that there would be no difference in patient satisfaction and maximum bite force (MBF) with the conventional denture and single implant-retained mandibular overdenture.

MATERIALS AND METHODS

A total of 12 fully edentulous first-time denture wearers (8 males and 4 females), between the age of 55 and 70 years, who had been edentulous for approximately 1 year, were selected in this within-subject crossover clinical trial. Ethical approval for the study was obtained from the Institutional Ethics Committee (IEC914). After an explanation of the proposed study criteria, including alternate treatment modalities, potential risks, and benefits, patients were asked to fill up an informed consent form before inclusion in the study. The subjects were selected after considering the following inclusion and exclusion criteria.

Inclusion criteria

1. Fully edentulous maxilla and mandible with atrophied mandibular ridge
2. Adequate bone volume for implant configuration which would be a minimum of 3.5 mm in diameter and 8 mm in length
3. Age between 55 and 70 years
4. No history of previous denture wear
5. Cooperative patient willing for surgery and proper follow-up
6. Skeletal class I patients with adequate interarch distance.

Exclusion criteria

1. Chronic smokers with poor oral hygiene
2. Any systemic or neurological diseases, e.g., diabetes, hypertension, and adrenal insufficiency
3. Any history of previous oral implant treatment
4. Insufficient bone quantity
5. Patient having parafunctional habits (e.g., clenching, bruxism) and temporomandibular disorders
6. Irradiated patient or patient undergoing chemotherapy
7. Impossibility to return to follow-up visits.

Before undergoing any surgical procedure, study models were prepared and orthopantomogram was taken for each patient. The edentulous symphyseal area was selected for implant placement and evaluated for length, width of bone, presence of any kind of undercut buccally or lingually. Implant position, vertical dimension was evaluated for interarch distance which should be a minimum of 9 mm for an implant-retained overdenture.

After attaining adequate local anesthesia, a midline incision was given at the implant site and a full-thickness mucoperiosteal flap was raised. Nishi's sequential drills were used to prepare the osteotomy site. Implant (Tuff, Medical Pvt Ltd, Nether, Israel) of the desired dimension was placed into the prepared site (35–45 Ncm) at the bone level and covered with a cover screw. Flap closure was done with silk suture and patients were given postoperative instructions related to diet, oral hygiene, and medication.

After 1 week of implant placement following the healing of soft tissue, the patient was recalled for the fabrication of a complete denture. Dentures were fabricated having a bilaterally balanced occlusion. Post denture instructions were given and patients were advised to wear the dentures for 3 months during the osseointegration phase. After 3 months, patients were recalled for the measurement of MBF and the questionnaire of patient satisfaction and complaint. All recordings before loading the implant were considered as Control Group.

Three months after the first stage of surgery, the ball abutment was placed for fifteen days. After the removal of healing abutment, the ball abutment was tightened to 20 Ncm with a hand torque wrench [9,10] [Figure 1]. The sequential cap was placed over the head of the ball abutment as a block. The standard nylon cap (NM-T3017, NORIS, Nether, Israel) with metal housing was inserted onto the ball abutment. The mandibular denture was then adjusted by providing a hole for the accommodation of metal housing in the denture. Metal housing was picked up in the denture with sequential pressure. During polymerization of the resin, the patient was asked to keep his/her denture in centric occlusion using maximum pressure, so that the denture base was in intimate contact with the supporting tissues [11]. Excess acrylic was trimmed, finished, and polished [Figure 2]. The stability of mandibular overdenture was checked and the patient was instructed for easy removal and placement. Then, the patient was recalled for the measurement of MBF and to fill the questionnaire at an interval of 1 week, 1 month, and 3 months. Denture fabrication and all the measurements were recorded by the same doctor.

Examination of patients satisfaction and complaints

The assessment of patient's satisfaction and complaint in complete denture (control group) and in implant overdenture after 1 week, 1 month, and 3 months was done with the help of a questionnaire [Table 1]. To quantify the level of satisfaction, a scale ranging from 1 to 4 ("very good/good/satisfactory/not satisfactory") and for complaint from 1 to 4 ("no/mild/moderate/severe") was used to evaluate the subjective data.

Maximum bite force measurement

Masticatory load generated was recorded using a specially designed bite gauge (LoadMaster, LIL 450, Bangalore, India). The bite gauge used was based on the principle of the strain gauge to measure the bite force. During measuring procedures, patients were seated comfortably upright in the chair with head supported. Bite tongs of the gauge were placed unilaterally in the first molar region, while occlusion was stabilized contralaterally with a block of putty [Figure 3]. Further, the patients were asked to bite onto the tongs with maximum force and were instructed to apply steady continuous pressure for 30 s. Readings that appeared on the bite force device were noted. All the measurements were done by one person.

It was important to determine whether the dentures caused pain during biting and to eliminate any pressure spots in order to avoid any difference on the part of the patients. The procedure was repeated three times for each of the right and left sides and the mean of all the readings recorded as MBF in kgf. Objective data or MBF were recorded in conventional denture (control group) and then at an interval of 1 week, 1 month, and 3 months in the mandibular implant overdenture.

Statistical Analysis: SPSS 17.0 (IBM, Chicago, USA) statistical software was used to analyze the data. Satisfaction outcomes and MBF between various time intervals were compared using Friedmann and *post hoc* Wilcoxon pair *t*-test. The association between masticatory performance and satisfaction level was calculated with the Spearman correlation test.

Table 1: Questionnaire for satisfaction and complaints measurement

Questionnaire

1. How satisfied you are with your dentures?
2. How satisfied you are with the fit of your maxillary denture?
3. How satisfied you are with the fit of your mandibular denture?
4. How satisfied you are with the appearance of your denture?
5. How satisfied you are with the speaking ability with your denture?
6. How satisfied you are with the chewing ability with your denture?
7. Are there any functional complaints (regarding speech, eating, and smiling) with your denture?
8. Is there any complaint in connection with the maxillary denture?
9. Is there any complaint in connection with the mandibular denture?
10. Is there any complaint regarding lip or cheek biting with your denture?
11. Is there any complaint regarding esthetic appearance of your denture?
12. Is there any complaint regarding handling (placement and removal) with your denture?
13. Is there any complaint regarding any kind of possible rotation effects with your denture?
14. Is there any physiognomic complaint (pinched mouth) with your denture?

RESULTS

Friedman test was done to analyze the satisfaction questioners response which showed significant improvement in ($P < 0.05$) subjective satisfaction (oral comfort and prosthesis function) and a significant decrease ($P < 0.05$) in complaints from pretreatment (control group) to

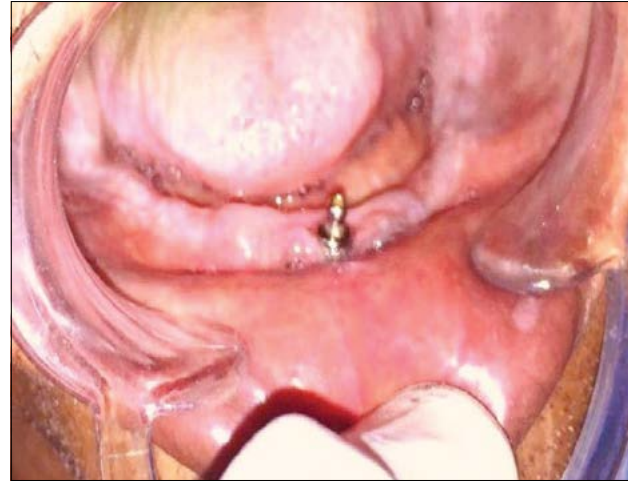

Figure 1: Implant with ball abutment after 3 months of implant placement

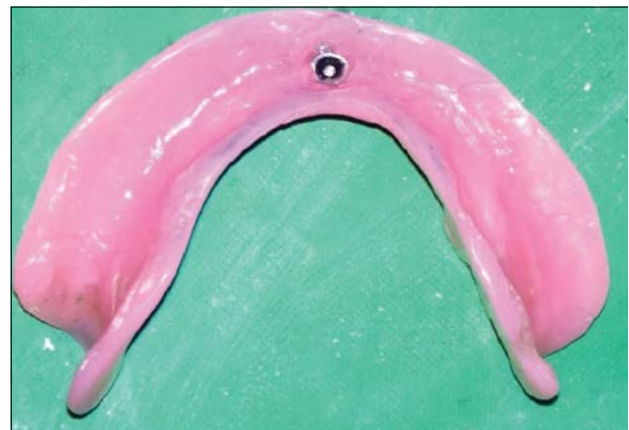

Figure 2: Nylon cap with metal housing picked up in denture using self-curing acrylic

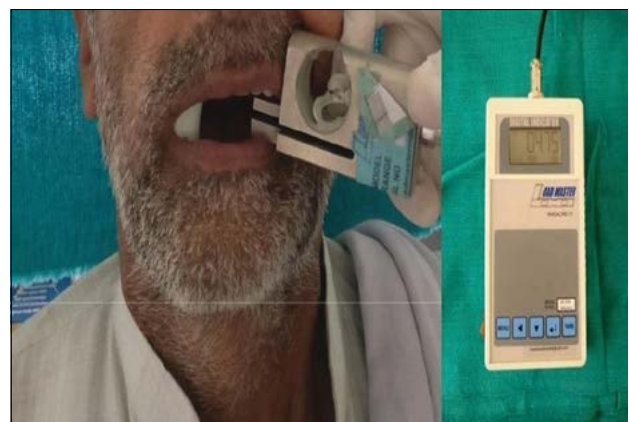

Figure 3: Maximum bite force recording with conventional upper and implant supported mandibular overdenture

posttreatment recall. Question responses of Q2, Q8, and Q11 were insignificant [Table 2].

MBF continued to increase in implant-assisted overdenture at all the recall examinations when compared with preoperative value (control group) [Table 3]. When the Friedman test and *Post hoc* Wilcoxon pair t-test were applied for intergroup comparison of MBF at different time intervals, a significant difference ($P < 0.01$) was found in all the comparisons [Table 4].

A statistically insignificant correlation was found between MBF values and satisfaction scores at different time intervals in implant overdenture, though patient satisfaction improved over time [Table 5].

DISCUSSION

As far as the location of a single implant in an edentulous mandible is concerned, studies conducted by several authors [1-3,12] stated that the mid-symphysis region constitutes an excellent host site for an implant in terms of quantity and quality of bone. This region is also easily accessible, demands minimal time, and shows less surgical trauma, with the result that, only a few postoperative complications (pain, swelling, ecchymosis, wound dehiscence, sublingual hematoma, and neurosensory problems) were seen. Single implant overdenture needs to be relined over a period of time for a better prognosis in the future.

Patient satisfaction was evaluated with the help of a questionnaire which was also used by Krennmair and Ulm, Palcari *et al.*, and Celebić *et al.* [1,11,13] in their study. Other methods of subjective assessment are the visual analog scale used by Cordoli *et al.* [2], Cheng *et al.* [3], and Walton *et al.* [14] in their studies. In this study, delayed loading after 3 months of implant placement was done. Author Kern *et al.* reported more success rate with delayed loading of single implant overdenture than of that with immediate loading [15]. However, Tavakolizadeh *et al.* [10] and Kronstrom *et al.* [16] reported success with immediate loading of single and two implant-retained overdenture in their one and 5-year study, respectively.

The null hypothesis of the study was rejected; the patient satisfaction and bite force improved in a implant-retained mandibular overdenture. Improved chewing experience can attribute to the improved stability/retention of implant mandibular overdenture which is in favor of the studies conducted by Cheng *et al.* [3], Geertman *et al.* [17], and Passia *et al.* [18]. Patients experienced a significant reduction ($P < 0.01$) in the functional complaint (speaking, smiling, and eating) with time because of gradual adaptation to the prosthesis. Krennmair and Ulm [1] also observed the same in their study, which showed that patient experience of decrease in complaints in implant overdenture as compared to that of conventional complete denture.

Evaluation of denture handling, i.e., denture removal and placement revealed an overall improvement after moderate difficulties. A significant improvement in denture handling was achieved from about 1 month by repeated practice and active involvement of the patients. In some patients, because of distolingual undercuts, some speech difficulties were observed during 3–4 days of use of the denture.

One disadvantage of this median ball attachment implant position was the development of a rotational movement which was absent before anchorage of the ball attachment in the conventional denture. In a study by Emami *et al.* [19] patients with implant-retained mandibular overdenture perceived no rotational movement were more satisfied with their denture as compared to patients who perceived rotational movement. Moreover, by keeping proper sublingual extensions, the complication could be prevented. Hence, in this study, we used a proper sublingual extension to reduce any kind of post-rotation of the denture.

Different types of recording devices had been used for the measurement of MBF. Lassila *et al.* [20] used a piezoelectric device and Haraldson *et al.* [21] used pressure-sensitive device in their study. In this study, the device used to record bite force comprised of two strain gauges connected to a strain measurement system through a cord. Bhat *et al.* [8], C

Table 2: Questions response at various time intervals

Questions	Pre (control group)		1 week		1 month		3 months		
	Mean	SD	Mean	SD	Mean	SD	Mean	SD	
Q1 ^a	2.083	0.966	1.917	0.900	1.500	0.522	1.417	0.515	0.00
Q2 ^a	1.750	1.055	1.583	0.669	1.667	0.779	1.417	0.669	0.30
Q3 ^a	2.750	0.866	2.00	0.603	1.667	0.492	1.333	0.492	0.00
Q4 ^a	1.667	0.651	1.33	0.651	1.333	0.492	1.250	0.452	0.00
Q5 ^a	2.00	0.853	1.83	0.577	1.417	0.515	1.167	0.389	0.00
Q6 ^a	2.750	1.055	2.08	0.793	1.750	0.622	1.417	0.515	0.00
Q7 ^a	2.250	0.622	1.750	0.452	1.417	0.515	1.083	0.289	0.00
Q8 ^a	1.500	1.000	1.450	0.452	1.417	0.515	1.333	0.492	0.59
Q9 ^a	2.500	0.674	1.75	0.452	1.58	0.515	1.250	0.452	0.00
Q10 ^a	1.167	0.651	1.167	0.389	1.000	0.000	1.000	0.000	0.00
Q11 ^a	1.167	0.389	1.250	0.452	1.083	0.289	1.083	0.289	0.39
Q12 ^a	1.417	0.318	1.667	0.492	1.33	0.492	1.000	0.000	0.00
Q13 ^a	NA	-	1.16	0.389	1.083	0.289	1.000	0.000	0.00
Q14 ^a	1.500	0.674	1.250	0.452	1.083	0.289	1.083	0.289	0.00

^aFriedmann test. S: Significant, NS: Nonsignificant, SD: Standard deviation, NA: Not available

Table 3: Maximum bite force (kgf) at various intervals

MBF total	Mean	SD	SE	Variance	P ^a
Pre (control group)	3.406	1.3940	0.403	1.944	0.0001* (S)
1 week	4.195	2.0730	0.598	4.297	
1 month	4.816	2.0800	0.601	4.327	
3 months	5.459	1.9650	0.567	3.861	

*Friedmann test. S: Significant, SD: Standard deviation, SE: Standard error, MBF: Maximum bite force

Table 4: Post hoc Wilcoxon pair t-test to compare maximum bite force at different time intervals

Class (I)	Class (J)	Z	Asymptotic significant (two-tailed)
Pre (control group)	1 week	-2.981	0.003
	1 month	-3.059	0.002
	3 months	-3.059	0.002
1 week	1 month	-3.059	0.002
	3 months	-3.061	0.002
1 month	3 months	-2.981	0.003

Table 5: Spearman correlation between satisfaction and maximum bite force at various time intervals

MBF versus Q	Correlation coefficient (r)	Significant (one-tailed)/P
Pre (control) versus pre (control)	0.546	0.033 (S)
1 week versus 1 week	0.305	0.167 (S)
1 month versus 1 month	0.435	0.079 (S)
3 months versus 3 months	0.060	0.426 (S)

MBF: Maximum bite force, Q: Questionnaire response, S: Significant

et al. [22], Rismanchian *et al.* [23], and Müller *et al.* [24] also used the strain gauge measurement system in their studies.

An increase in bite force after implant loading can be explained by the fact that the dental implants help in the improvement of the functional state of the masticatory apparatus by assisting in the establishment of better neuromuscular coordination by improving support, stability, and retention of the prosthesis. The present study confirms the findings of Bakke *et al.* [25], they observed higher MBF values in all implant-treated patients. Similar results were also seen by Fontijn Tekamp *et al.* [5] and Rismanchian *et al.* [23].

A significant difference was found only between MBF pre- and MBF postoperative recall examination at 3 months because of the gradual building up experience and adaptation to the prosthesis. Like the present study, most studies on implant treatment and oral function demonstrated an improvement of masticatory function in implant-assisted overdenture as compared to the conventional denture [18,22,25-28].

Association between masticatory performance and satisfaction level was also calculated with Spearman correlation test which was found to be low with no significant association between the objective (masticatory performance) and subjective (satisfaction level) measurement. In agreement with the present study, Geckili *et al.* [22] also did not find any correlation between the two. Thus, patients with a better masticatory performance are not necessarily more satisfied, because patient satisfaction is shown to be multifactorial.

Satisfaction not only depends on chewing ability but also on esthetics and expectations of the level of retention to implant overdenture.

Different authors found similar bone loss [10,29], functional improvement, implant survival [10,16], implant and prosthesis failure [30,31] in single and two implant-assisted mandibular overdenture. Ahmed *et al.* reported a significant decrease in marginal bone loss and a number of implant failures in single implant-retained overdenture compared to that with implants [32]. The single implant-retained overdenture proved to be successful and an economic treatment protocol [3]. Hence, a greater number of edentulous patients could benefit from this new treatment modality.

The main limitation of this research was the trivial number of participants along with the short duration of the follow-up period. Considering the strict inclusion and exclusion criteria, most patients evaluated were not included in this study. More studies are required to validate the finding of this study. Further, long-term follow-up studies on this subject with a larger number of participants are recommended. Furthermore, we can compare single and two implant-retained overdentures with different attachment systems e.g., ball, locator, and a magnet.

Clinical implication

Less component costs and surgical trauma in treating patients with single-implant retained overdenture compared to that with two implant-assisted overdentures should make this treatment modality a more affordable option for geriatric patients, who are not satisfied with their conventional mandibular denture but are deterred by the expense of two implants. This treatment option could benefit the economically weaker section of the population in developing countries.

CONCLUSION

Within the limitations of this study, it appears that the single implant-assisted mandibular overdentures increase the comfort, fit, stability, MBF, and decrease the functional complaints, i.e., difficulty to speak and chew as compared with a conventional complete denture.

Financial support and sponsorship

Nil.

Conflicts of interest

There are no conflicts of interest.

REFERENCES

1. Krennmair G, Ulm C. The symphyseal single-tooth implant for anchorage of a mandibular complete denture in geriatric patients: a clinical report. *Int J Oral Maxillofac Implants* 2001;16:98-104.
2. Cordioli G, Majzoub Z, Castagna S. Mandibular overdentures anchored to single implants: A five-year prospective study. *J Prosthet Dent* 1997;78:159-65.
3. Cheng T, Ma L, Liu LX, Sun FG, He JX, Huo YJ, et al. Use of a single implant to retain mandibular overdenture: A preliminary clinical trial of 13 cases. *J Dent Sci* 2012;7:261-6.
4. Nogueira TE, Esfandiari S, Leles CR. Cost-effectiveness analysis of

- single-implant mandibular overdenture versus conventional complete denture: study protocol for a randomized controlled trial. *Trials* 2016;17:533.
5. Fontijn-Tekamp FA, Slagter AP, Van Der Bilt A, Van T Hof MA, Witter DJ, Kalk W, et al. Biting and chewing in overdentures, full dentures, and natural dentition. *J Dent Res* 2000;79:1519-24.
 6. Mericske-Stern RD, Taylor TD, Belser U. Management of the edentulous patient. *Clin Oral Implants Res* 2000;11(Suppl 1):108-25.
 7. The Glossary of Prosthodontic Terms: GPT-9. *J Prosthet Dent* 2017;117(Suppl 5):e1-105.
 8. Bhat S, Chowdhary R, Mahoorkar S. Comparison of masticatory efficiency, patient satisfaction for single, two, and three implants supported overdenture in the same patient: A pilot study. *J Indian Prosthodont Soc* 2016;16:182-6.
 9. Varshney N, Aggarwal S, Kumar S, Singh SP. Retention and patient satisfaction with bar-clip, ball and socket and kerator attachments in mandibular implant overdenture treatment: An *in vivo* study. *J Indian Prosthodont Soc* 2019;19:49-57.
 10. Tavakolizadeh S, Vafae F, Khoshhal M, Ebrahimzadeh Z. Comparison of marginal bone loss and patient satisfaction in single and double-implant assisted mandibular overdenture by immediate loading. *J Adv Prosthodont* 2015;7:191-8.
 11. Paleari AG, Oliveira Junior NM, Marin DOM, Rodriguez LS, Arioli Filho JN, Pero AC, et al. One-year prospective clinical study comparing patient satisfaction and masticatory performance of mandibular overdentures supported by one versus two implants. *J Appl Oral Sci* 2018;26:e20160628.
 12. Liddel G, Henry P. The immediately loaded single implant-retained mandibular overdenture: a 36-month prospective study. *Int J Prosthodont* 2010;23:13-21.
 13. Celebić A, Knezović-Zlatarić D. A comparison of patient's satisfaction between complete and partial removable denture wearers. *J Dent* 2003;31:445-51.
 14. Walton JN, Pros C, Glick N, MacEntee MI, Pros D. A randomized clinical trial comparing patient's satisfaction and prosthetic outcomes with mandibular overdentures retained by one or two implants. *Int J Prosthodont* 2009;22:331-9.
 15. Kern M, Att W, Fritzer E, Kappel S, Luthardt RG, Mundt T, et al. Survival and complications of single dental implants in the edentulous mandible following immediate or delayed loading: A randomized controlled clinical trial. *J Dent Res* 2018;97:163-70.
 16. Kronstrom M, Davis B, Loney R, Gerrow J, Hollender L. Satisfaction and Clinical Outcomes Among Patients with Immediately Loaded Mandibular Overdentures Supported by One or Two Dental Implants: Results of a 5-Year Prospective Randomized Clinical Trial. *Int J Oral Maxillofac Implants* 2017;32:128-36.
 17. Geertman ME, Slagter AP, van 't Hof MA, van Waas MA, Kalk W. Masticatory performance and chewing experience with implant-retained mandibular overdentures. *J Oral Rehabil* 1999;26:7-13.
 18. Passia N, Wolfart S, Kern M. Six-year clinical outcome of single implant-retained mandibular overdentures--a pilot study. *Clin Oral Implants Res* 2015;26:1191-4.
 19. Emami E, de Souza RF, Bernier J, Rompré P, Feine JS. Perceptions of the mandibular three-implant overdenture: a practical study. *Clin Oral Implants Res* 2015;26:639-43.
 20. Lassila V, Holmlund I, Koivumaa KK. Bite force and its correlation with different denture types. *Acta Odontol Scand* 1985;43:127-32.
 21. Haraldson T, Jemt T, Ståhlblad PA, Lekholm U. Oral function in patients with overdentures supported by osseointegrated implants. *Scand J Dent Res* 1988;96:235-42.
 22. Geckili O, Bilhan H, Mumcu E, Tuncer N. The influence of bite force on patient satisfaction and quality of life of patients with mandibular implant overdentures. *J Oral Implantol* 2012;38:271-8.
 23. Rismanchian M, Bajoghli F, Mostajeran Z, Fazel A, Eshk. Effect of implants on maximum bite force in edentulous patients. *J Oral Implantol* 2009;35:196-200.
 24. Müller F, Heath MR, Ott R. Maximum bite force after the replacement of complete dentures. *Gerodontology* 2001;18:58-62.
 25. Bakke M, Holm B, Gotfredsen K. Masticatory function and patient satisfaction with implant-supported mandibular overdentures: a prospective 5-year study. *Int J Prosthodont* 2002;15:575-81.
 26. Carlsson GE, Kronström M, de Baat C, Cune M, Davis D, et al. A survey of the use of mandibular implant overdentures in different countries. *Int J Prosthodont* 2004;17:211-7.
 27. Naert I, Alsaadi G, Quirynen M. Prosthetic aspects and patient satisfaction with two-implant-retained mandibular overdentures: a randomized clinical study. *Int J Prosthodont* 2004;17:401-10.
 28. van Kampen FM, van der Bilt A, Cune MS, Fontijn-Tekamp FA, Bosman F. Masticatory function with implant-supported mandibular overdentures. *J Dent Res* 2004;83:708-11.
 29. Kant B, Ranjan M, Kumar A, Mukherjee B, Pandey SM, Aggarwal S, et al. A randomized controlled trial comparing the radiographic evidence of crestal bone resorption in single implant versus two implant-retained mandibular overdentures. *J Family Med Prim Care* 2019;8:1594-8.
 30. Kronstrom M, Davis B, Loney R, Gerrow J, Hollender L. A prospective randomized study on the immediate loading of mandibular overdentures supported by one or two implants: a 12-month follow-up report. *Oral Maxillofac Implants* 2010;25:181-8.
 31. Gonda T, Meda Y, Walton JN, MacEntee MI. Fracture incidence of mandibular overdentures retained by one or two implants. *J Prosthet Dent* 2010;103:178-81.
 32. Ahmed Elawady DM, Kaddah AF, Talaat Khalifa M. Single vs two implant-retained mandibular overdentures: A Systematic Review With Meta-analysis. *Int J Dent Pract* 2017;17:216-25.
 33. Mahoorkar S, Bhat S, Kant R. Single implant supported mandibular overdenture: A literature review. *J Indian Prosthodont Soc* 2016;16:75-82.

Notes

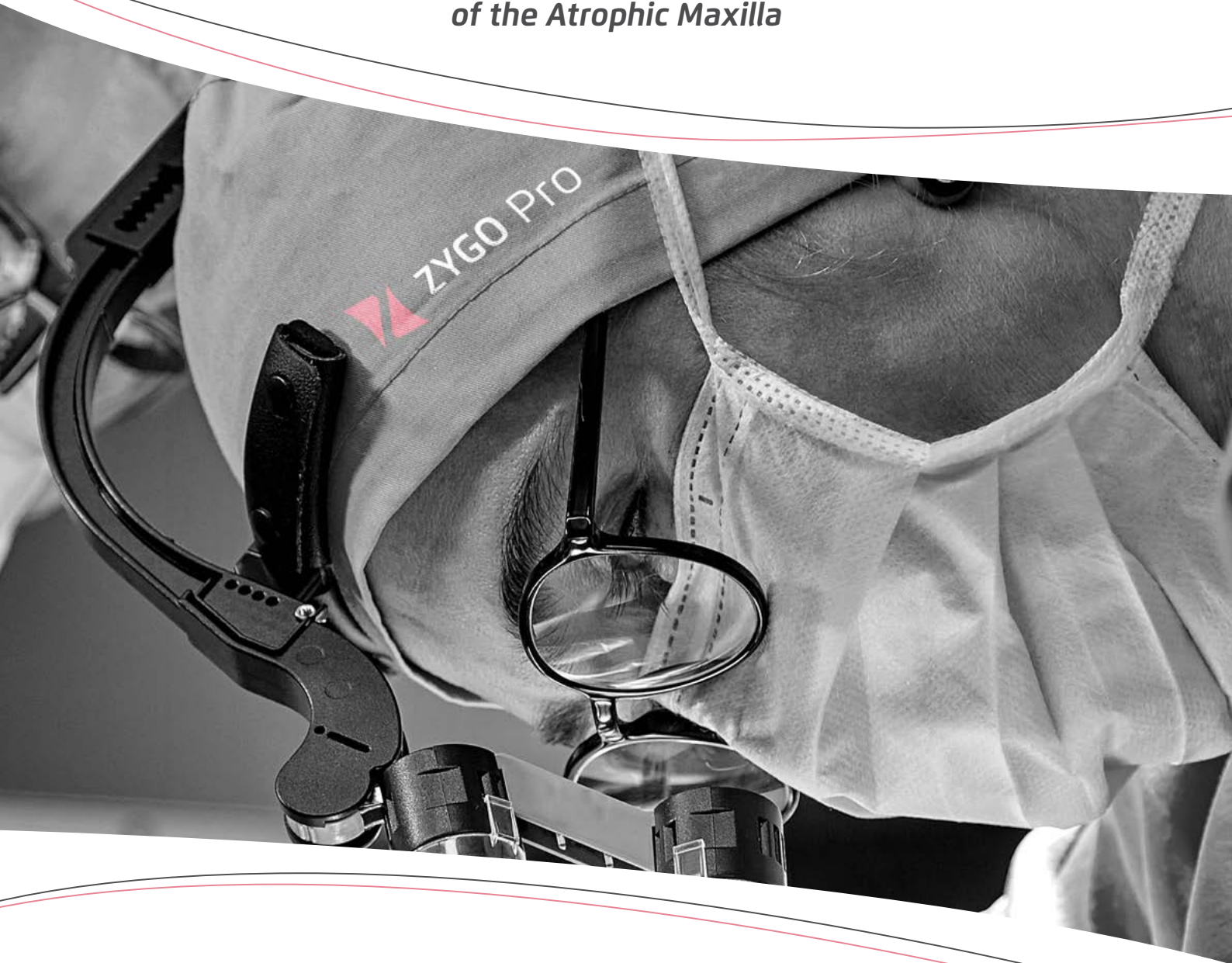



YOUR FUTURE

IN DENTAL HEALTHCARE

*A Global Community of Experts and Centers
Specializing in the Rehabilitation
of the Atrophic Maxilla*



www.zygopro.com

We can make you
Smile



norismedical.com