

Carmen B. B.

Carmen B. B.

Edad: 54 años.

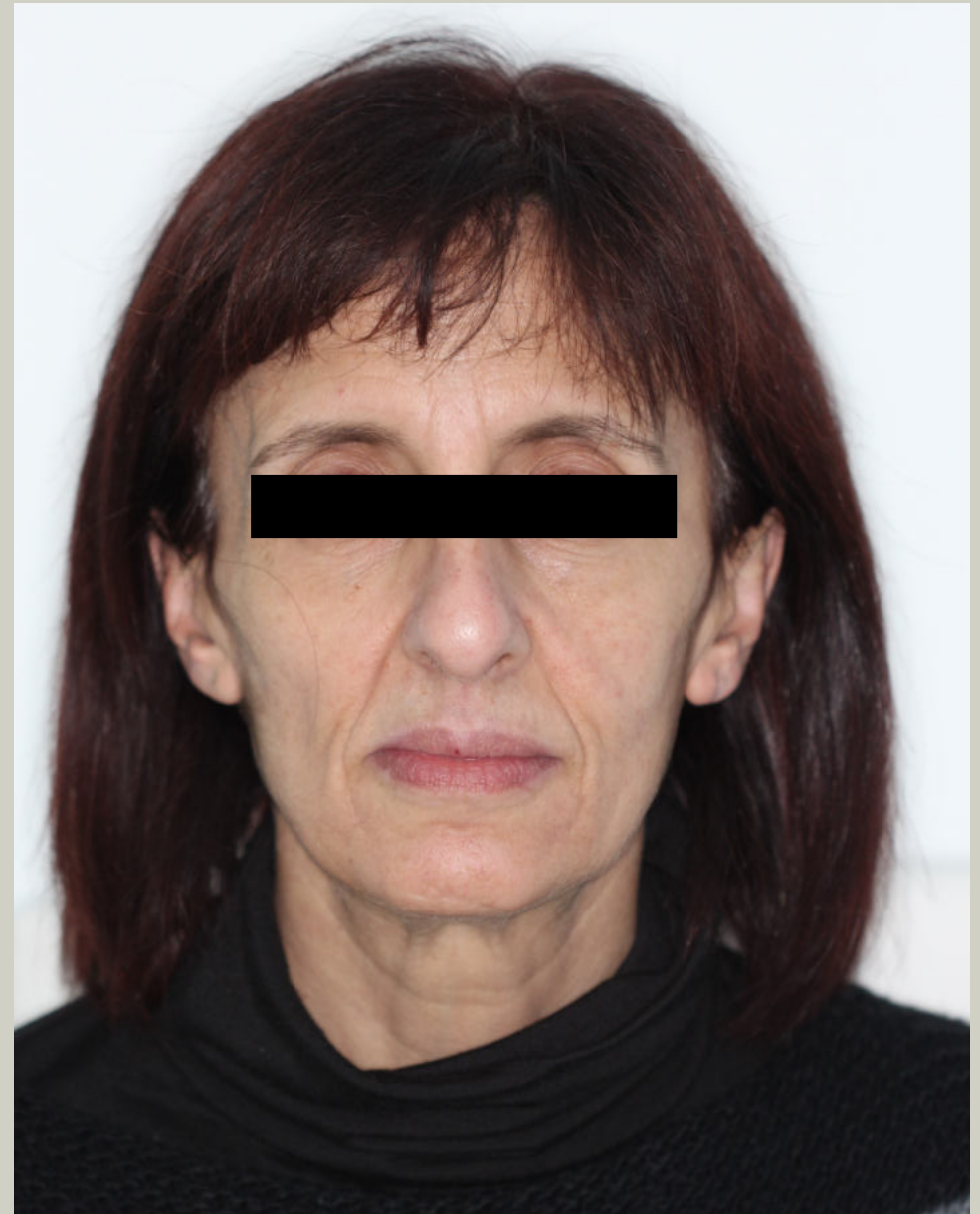Motivo de consulta: “Me han fracasado los implantes”.

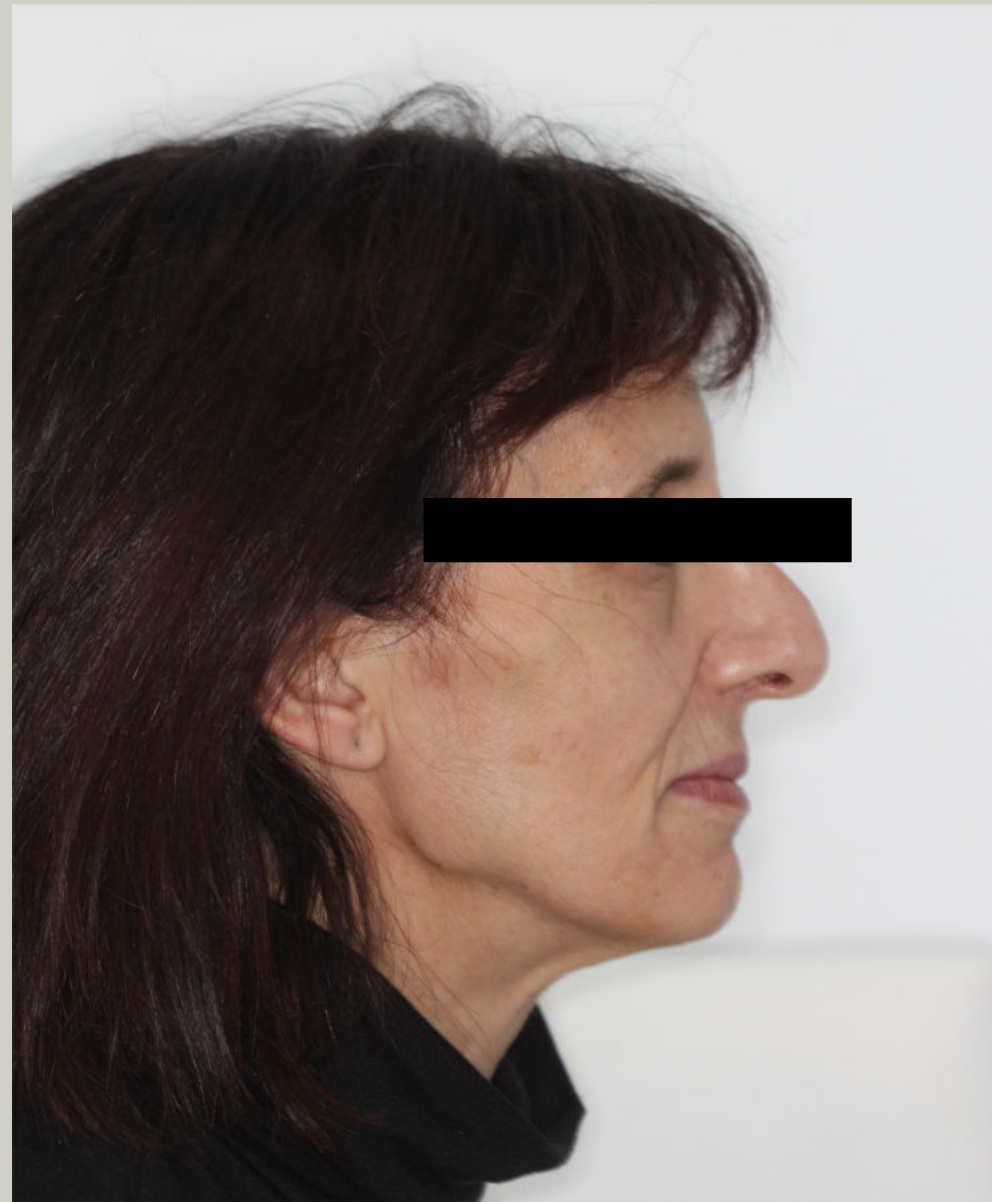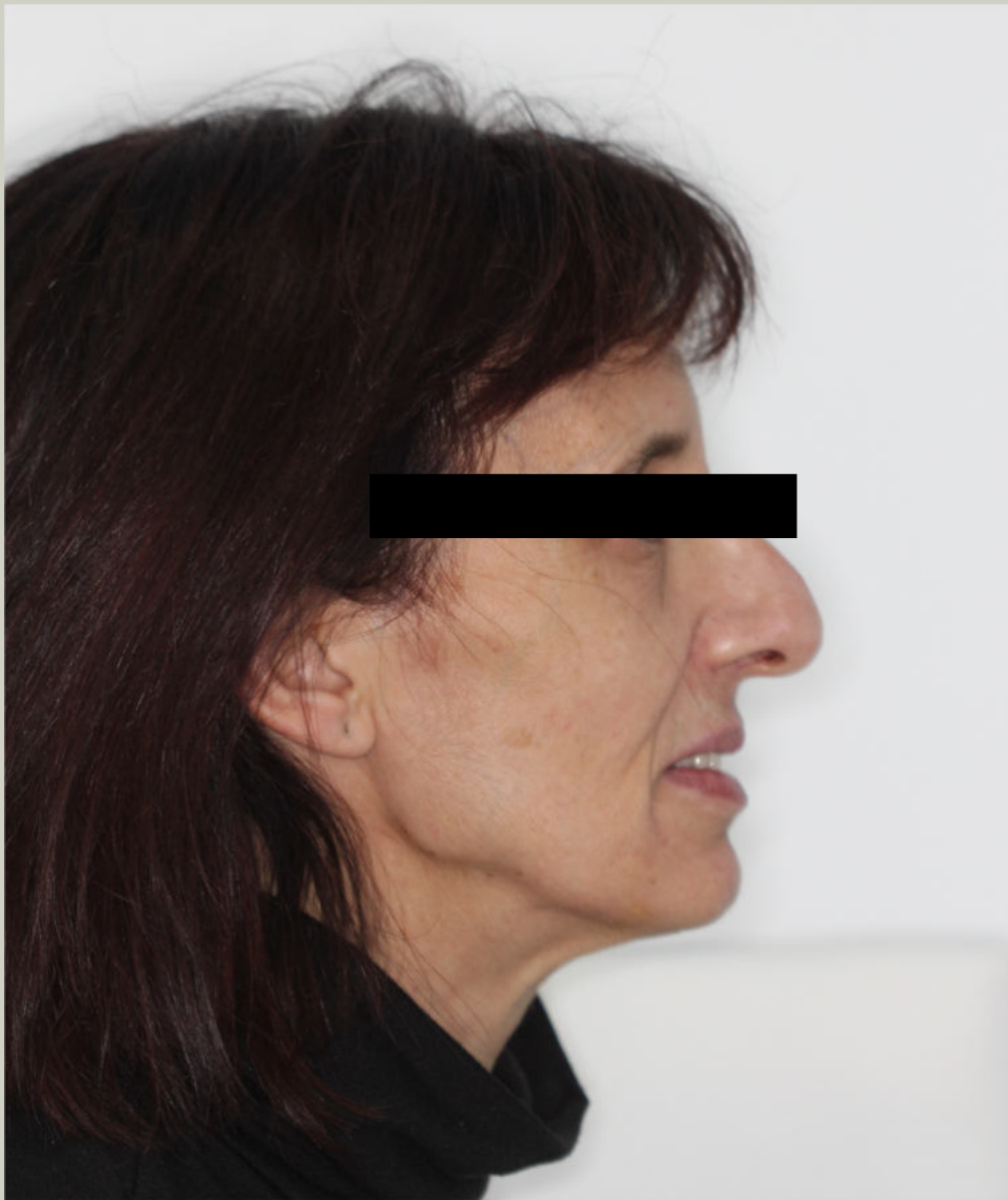Antecedentes médicos de interés:

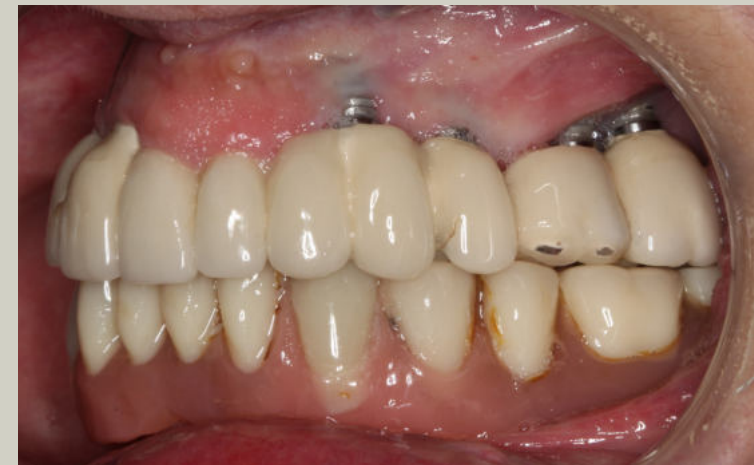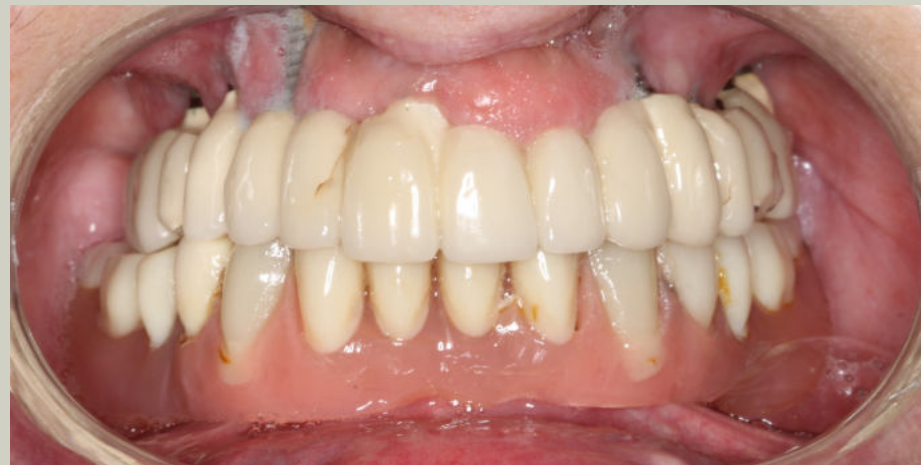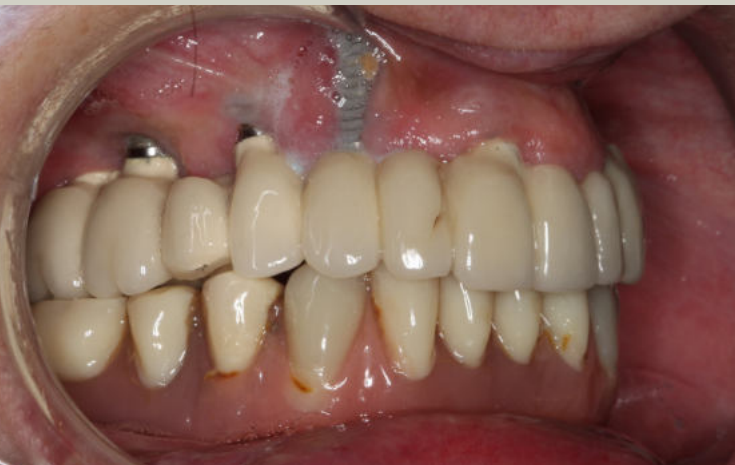- **Medicación:** Sedotime 15 mg (benzodiacepina), Serra 20 mg (opiáceo), Deltius 25.000 UI/2,5 ml (vitamina D - colecalciferol) y (atorvastatina).

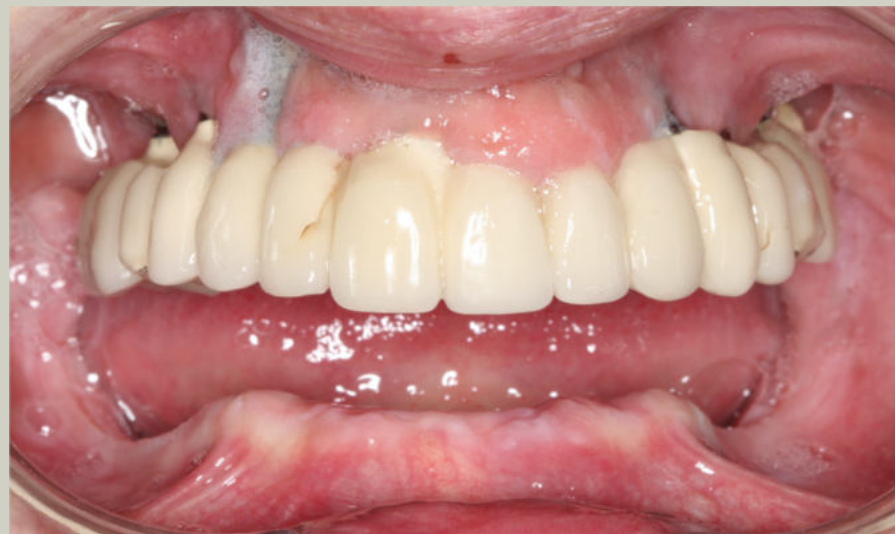- **No alergias.**

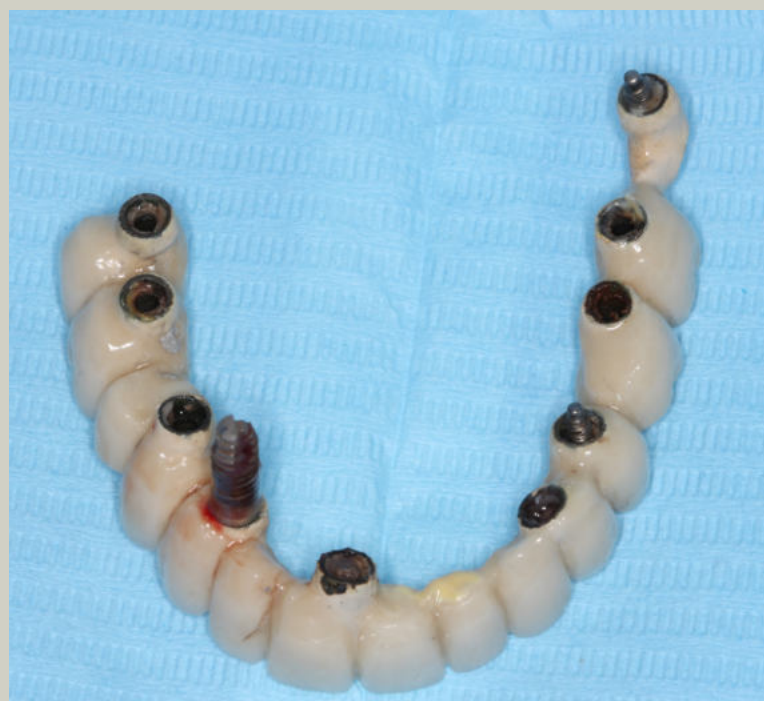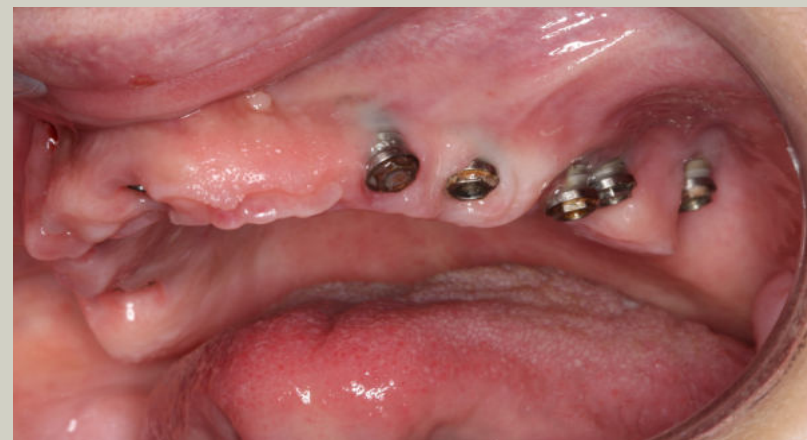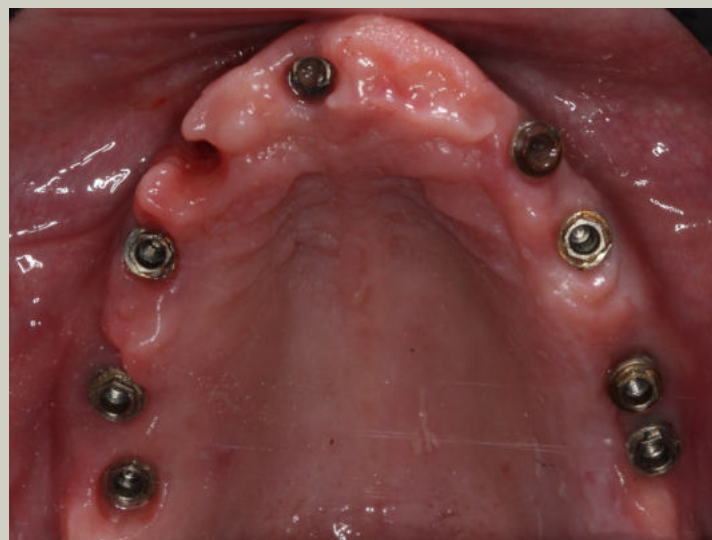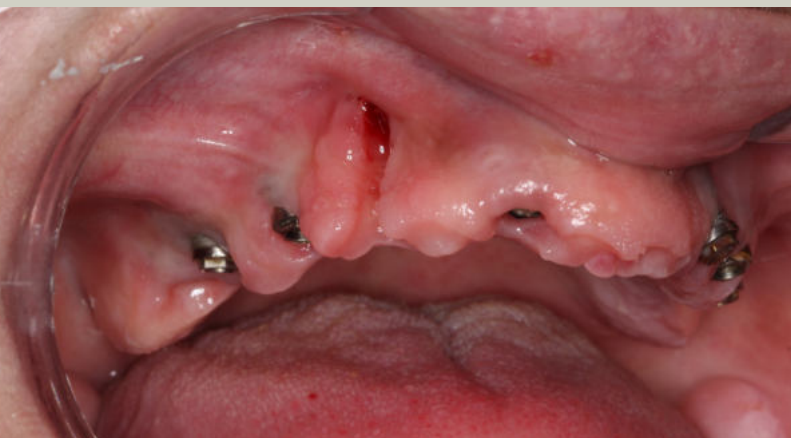Diagnóstico: Explantación de implantes superiores + rehabilitación superior con implantes cigomáticos e inferior con implantes convencionales.



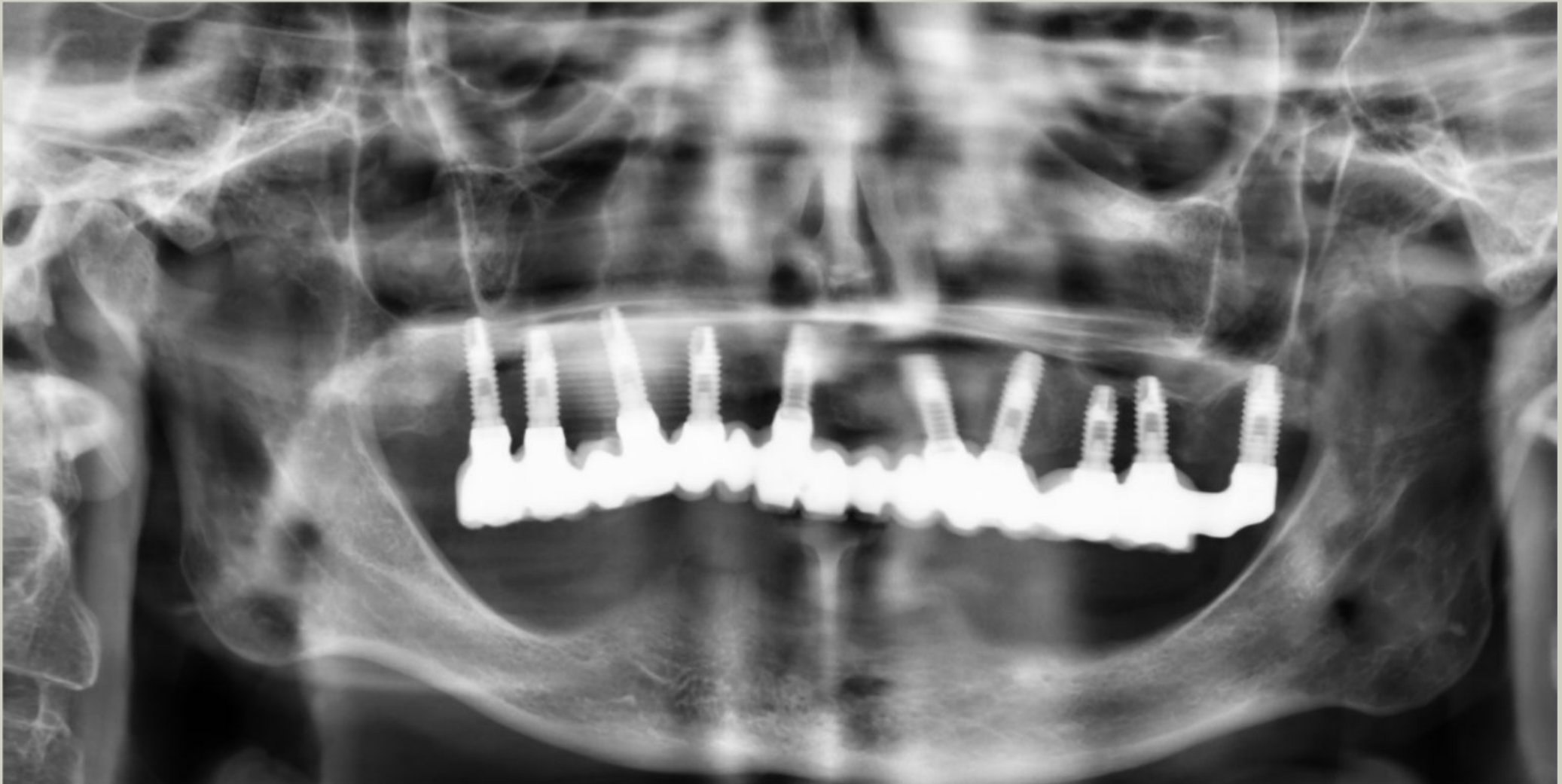




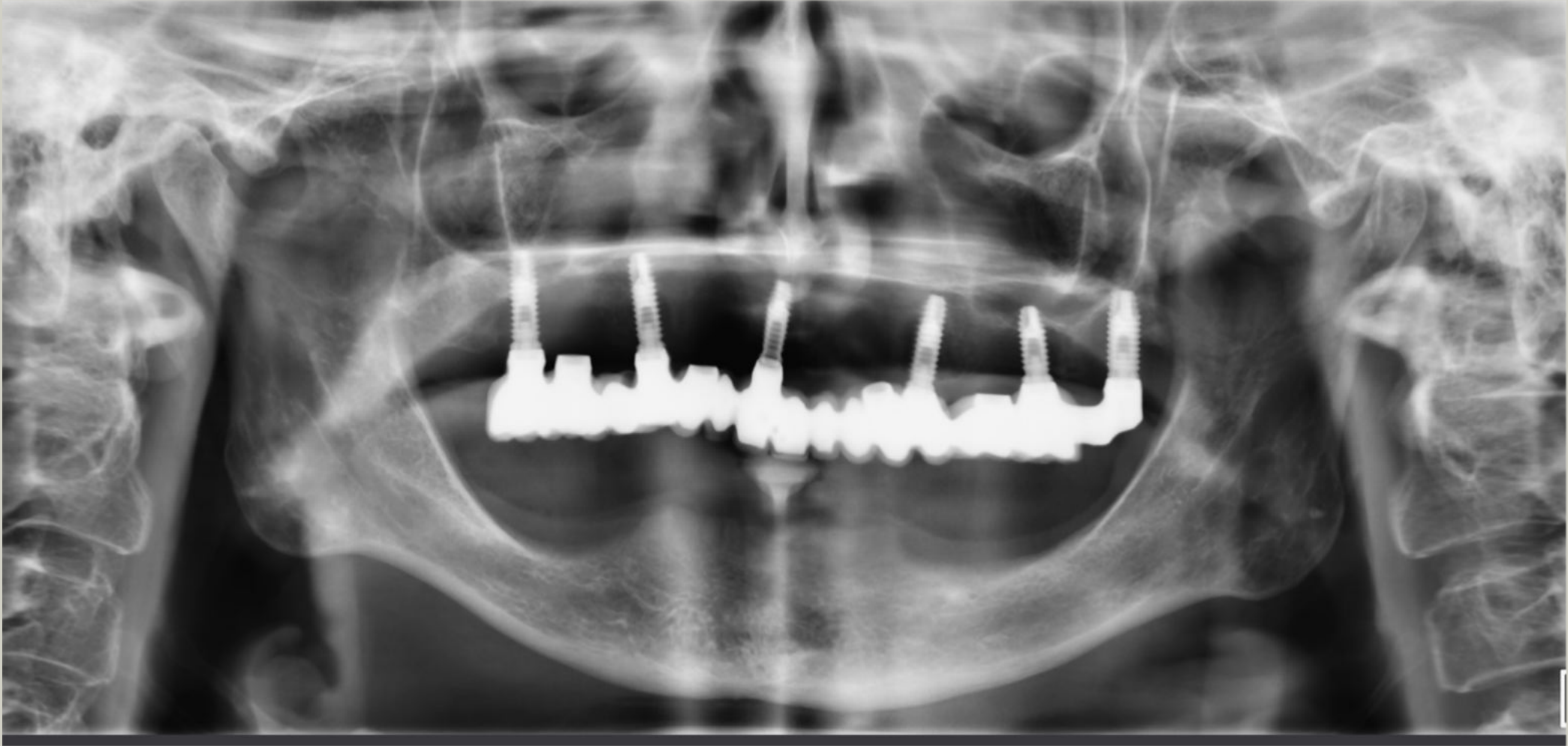
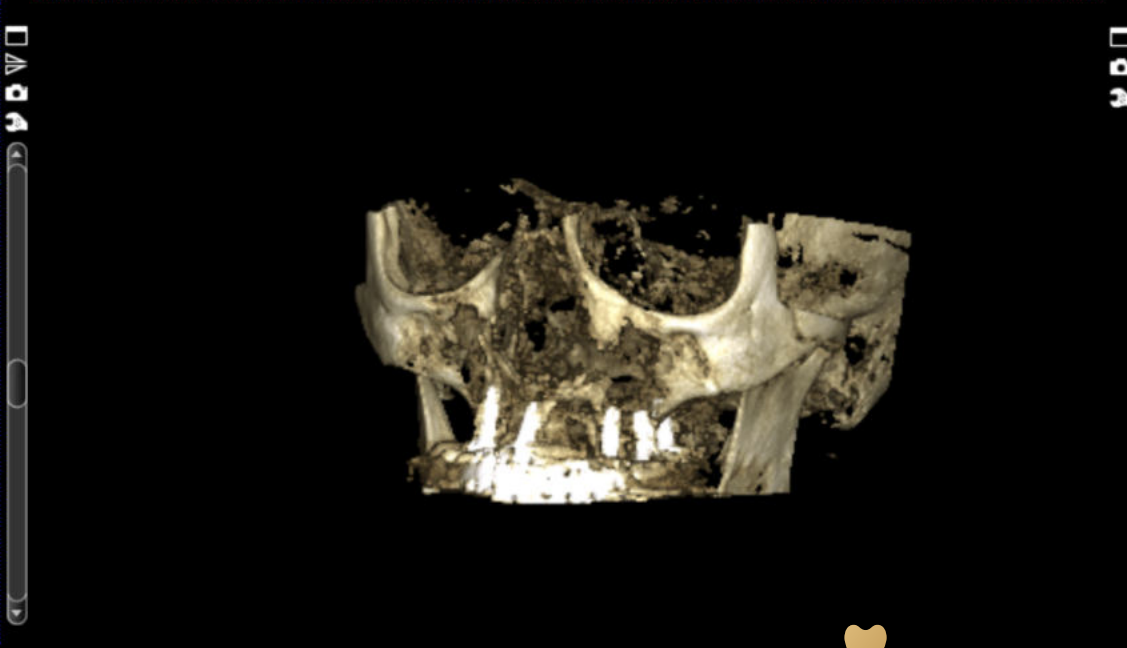
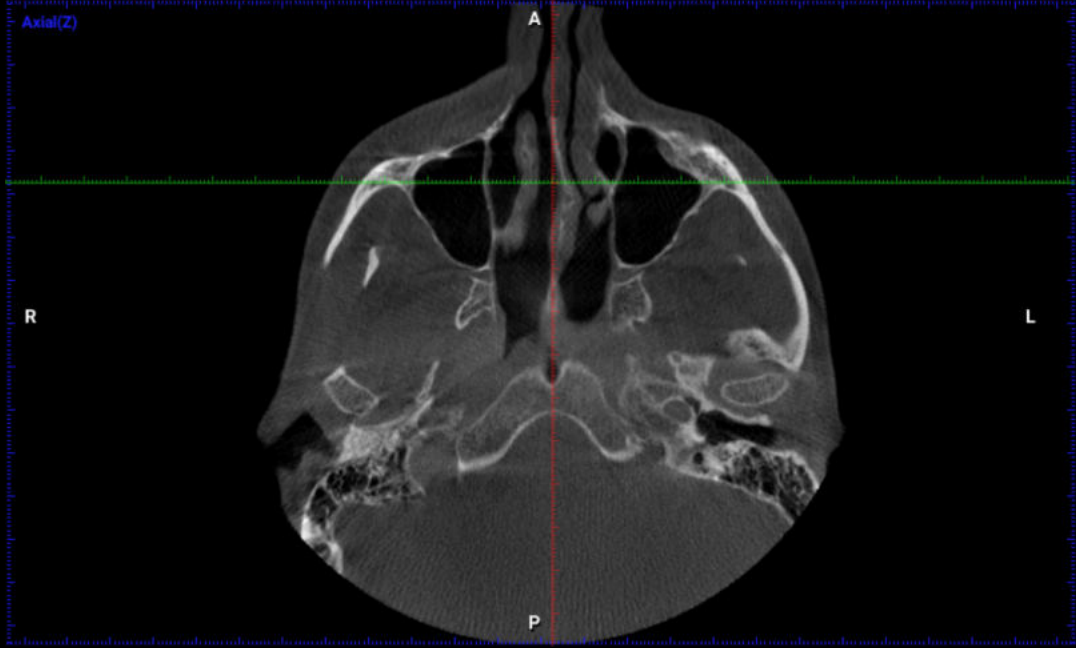
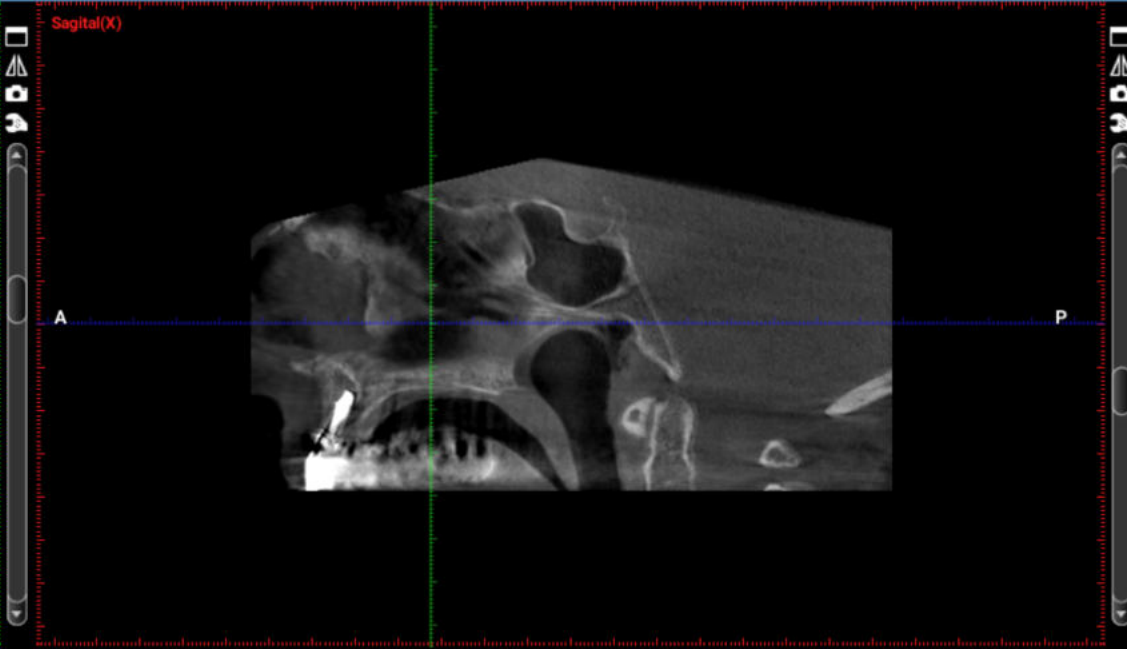
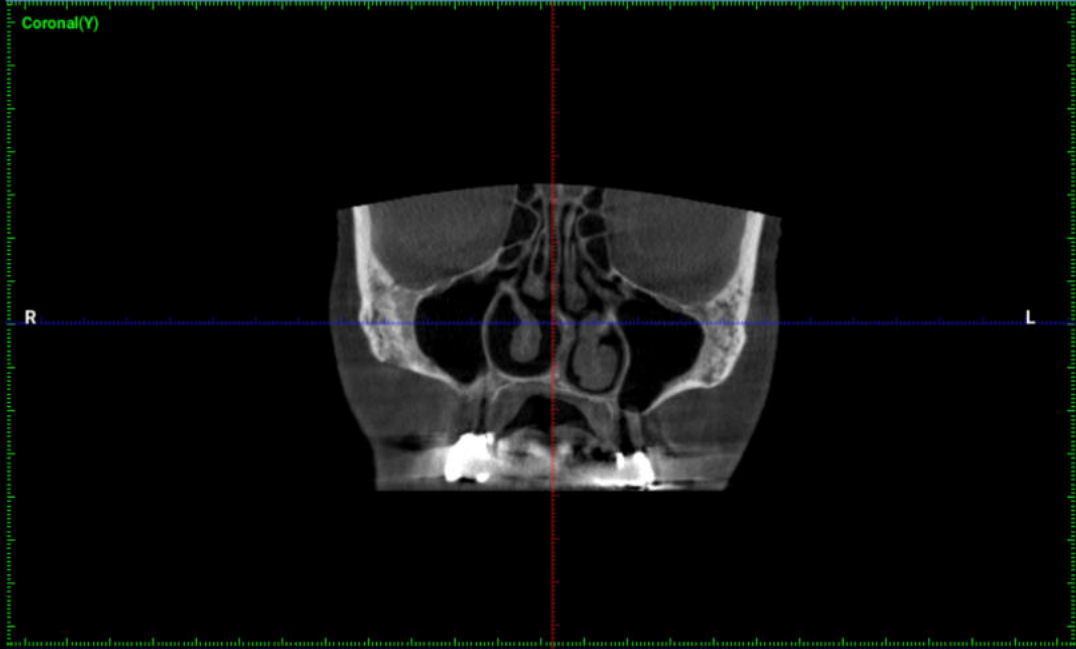


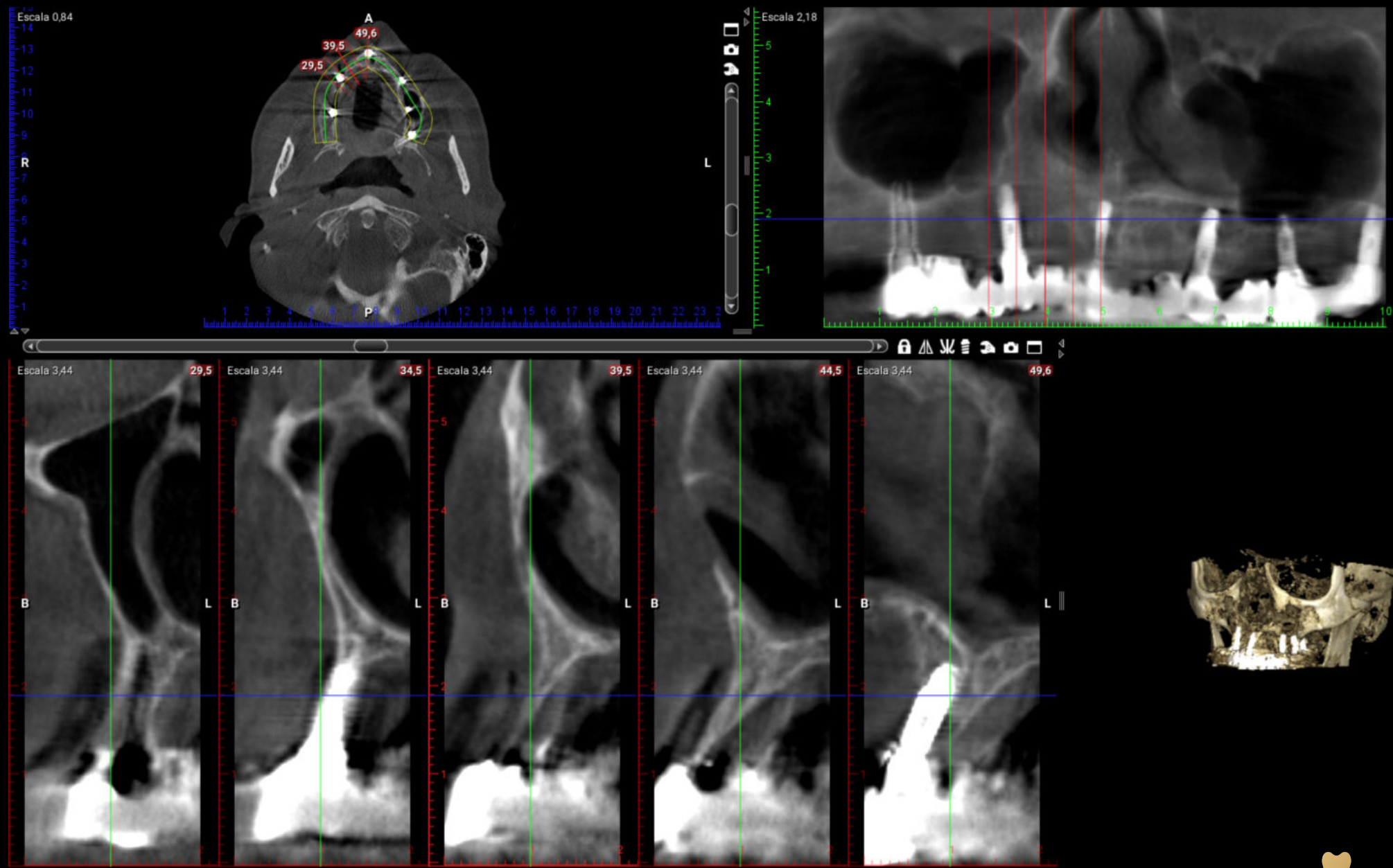
4/11/21

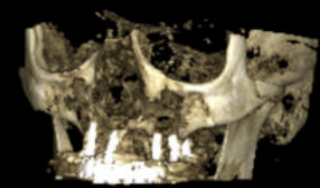
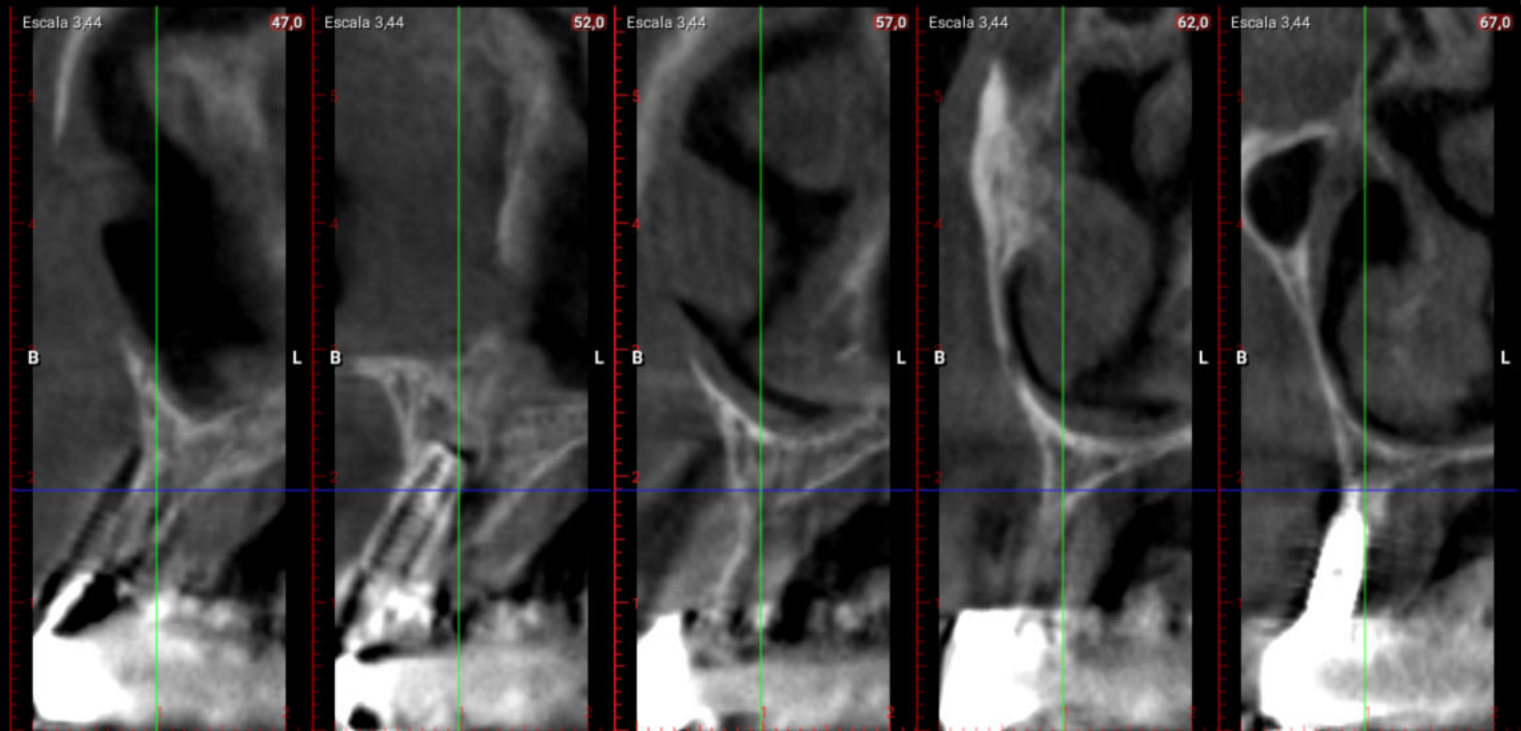
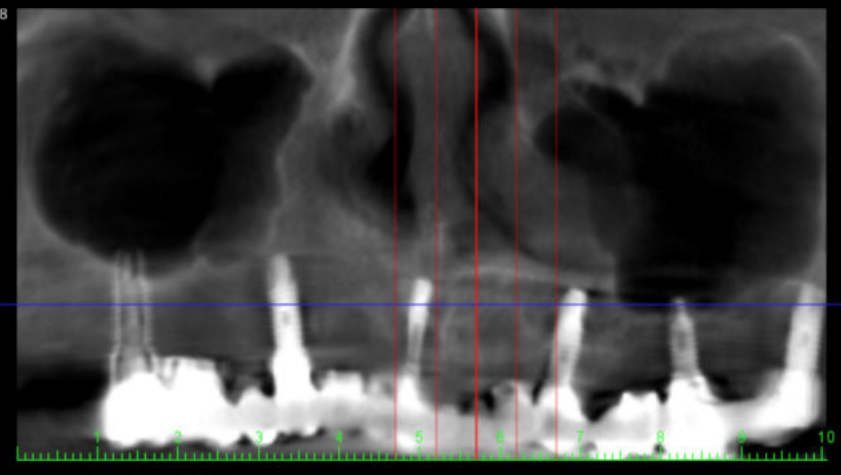
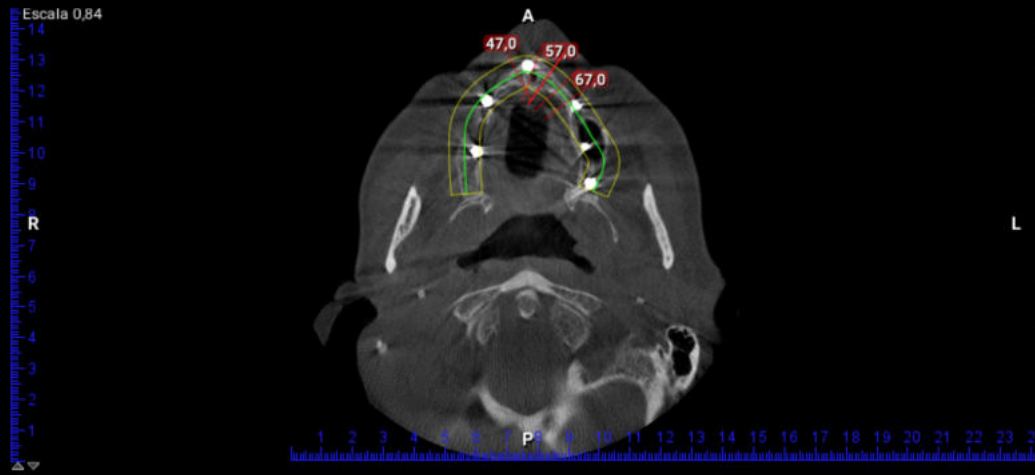


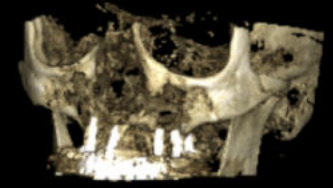
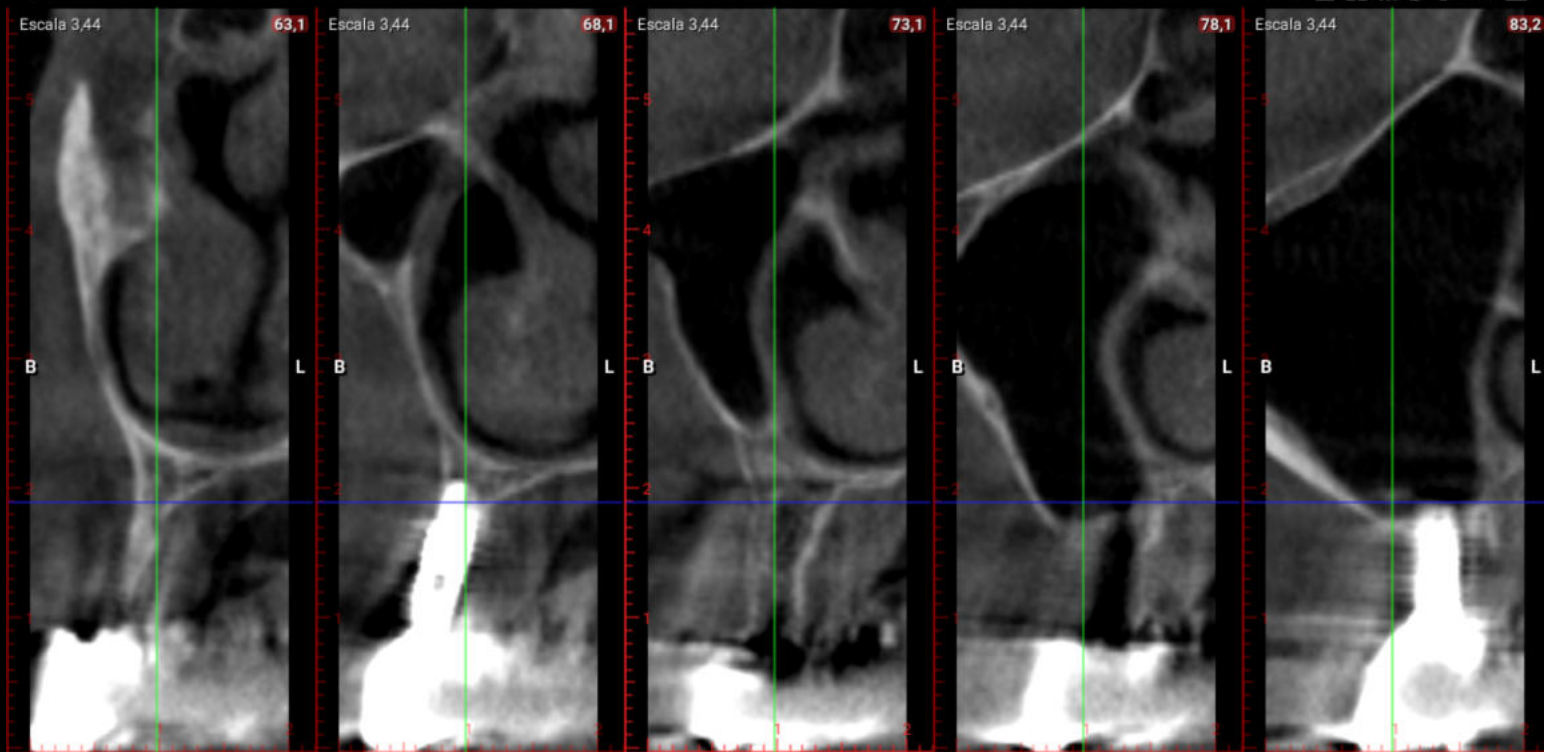
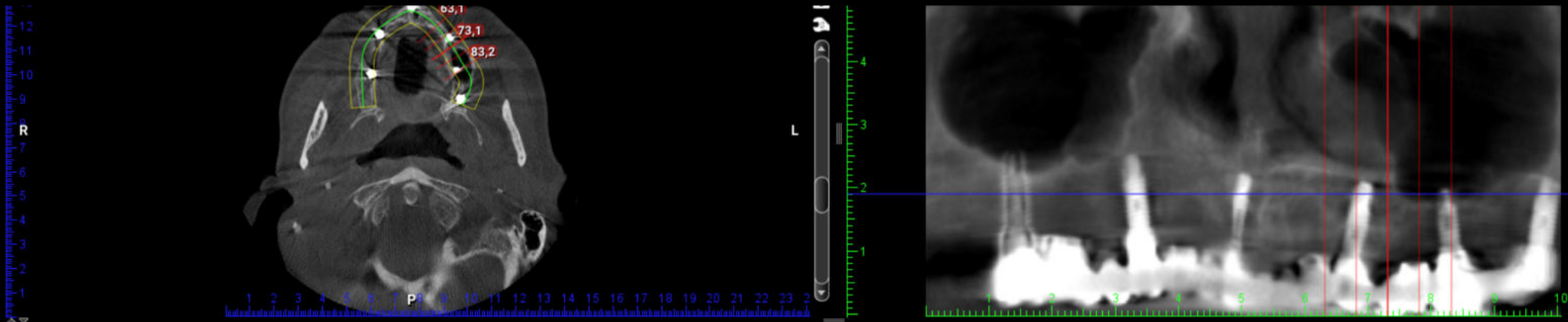
24/1/22

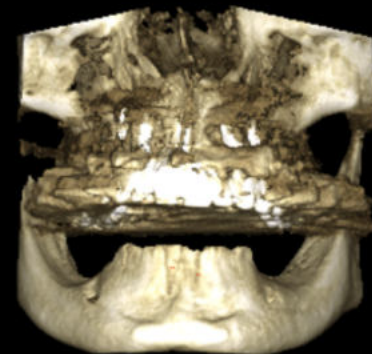
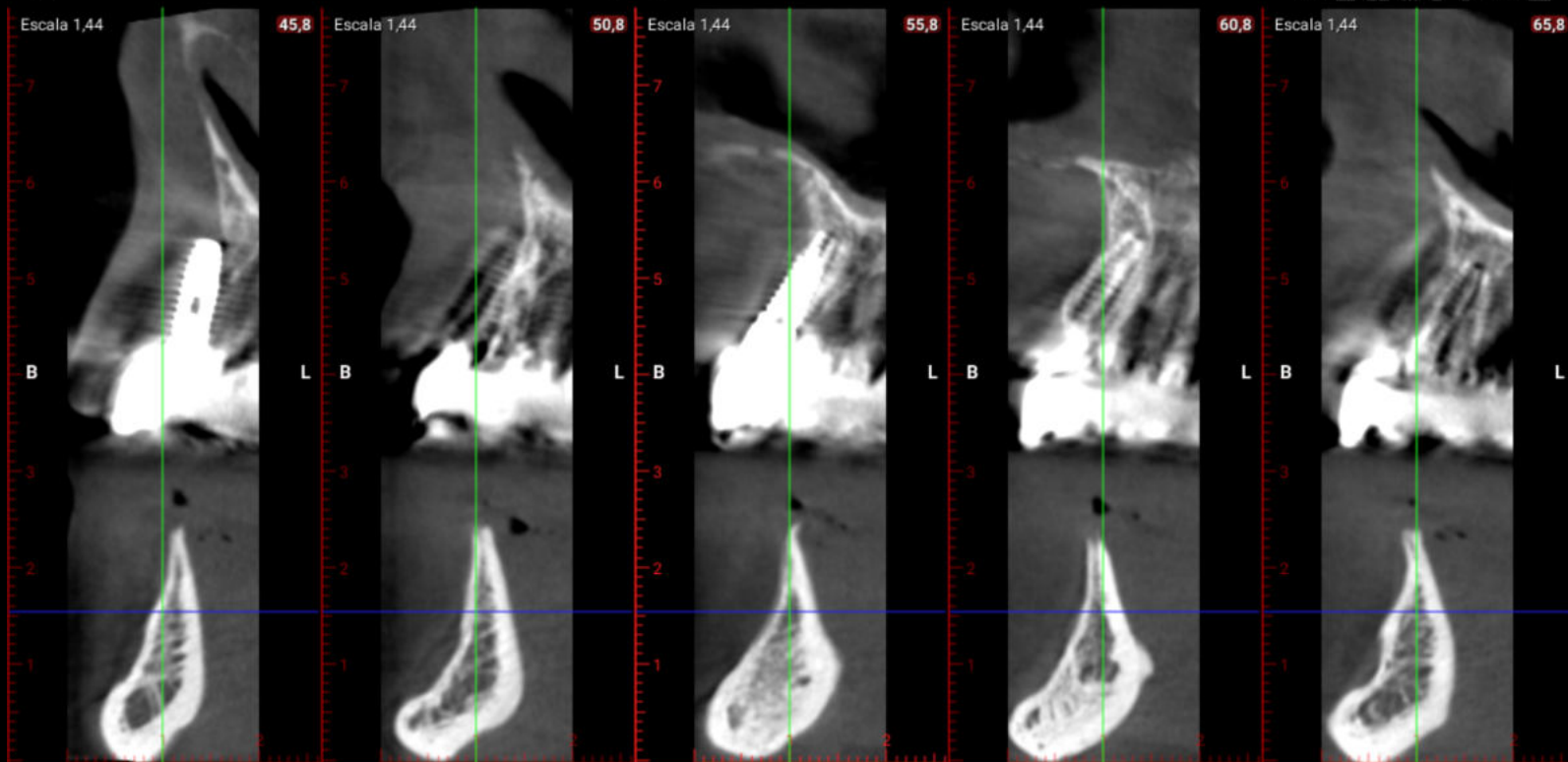
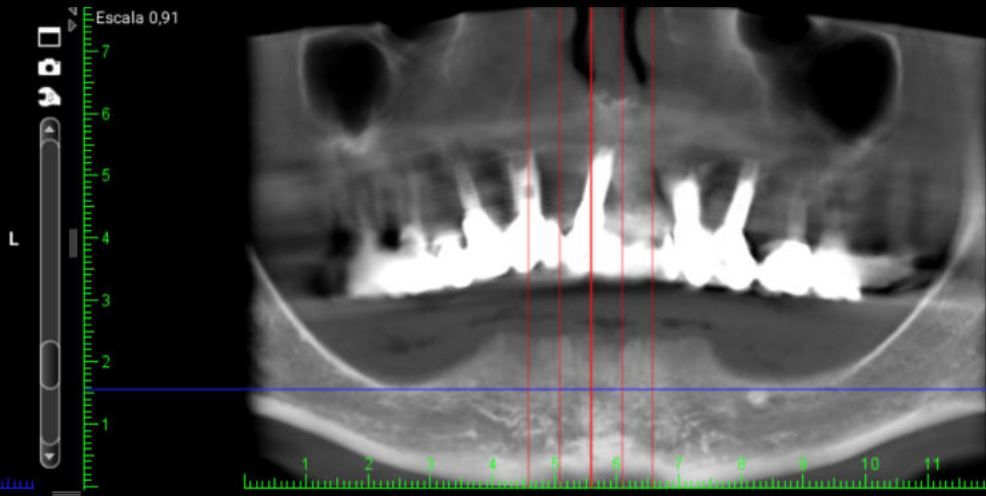
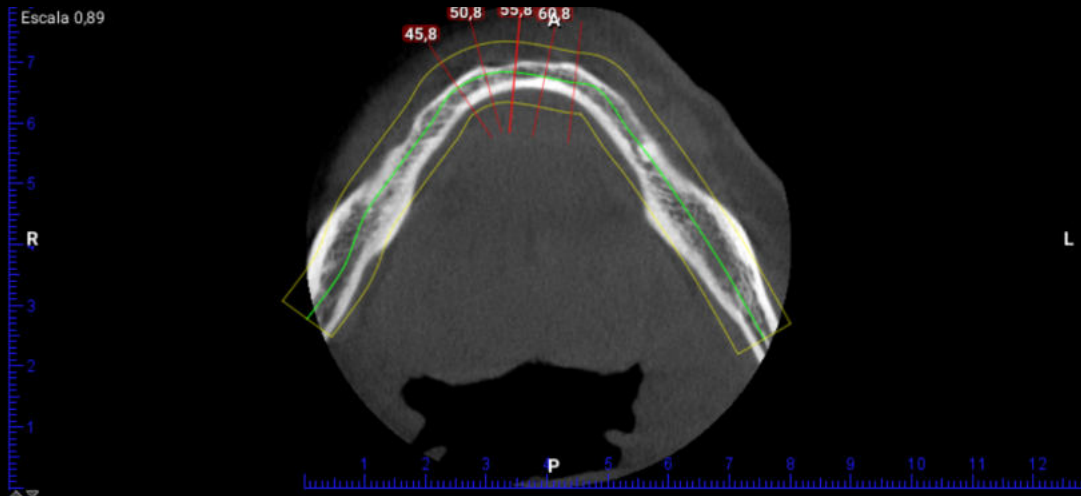




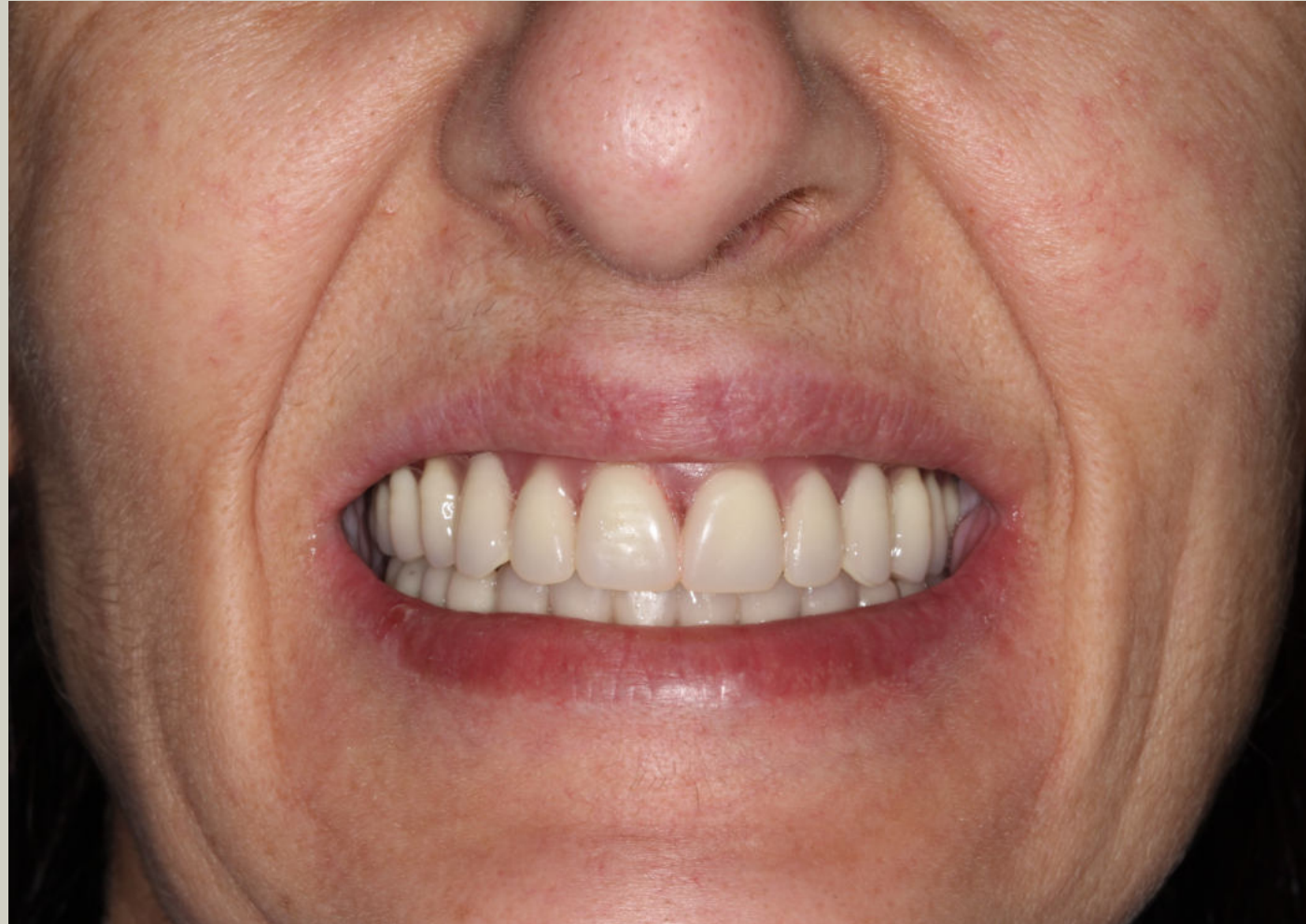





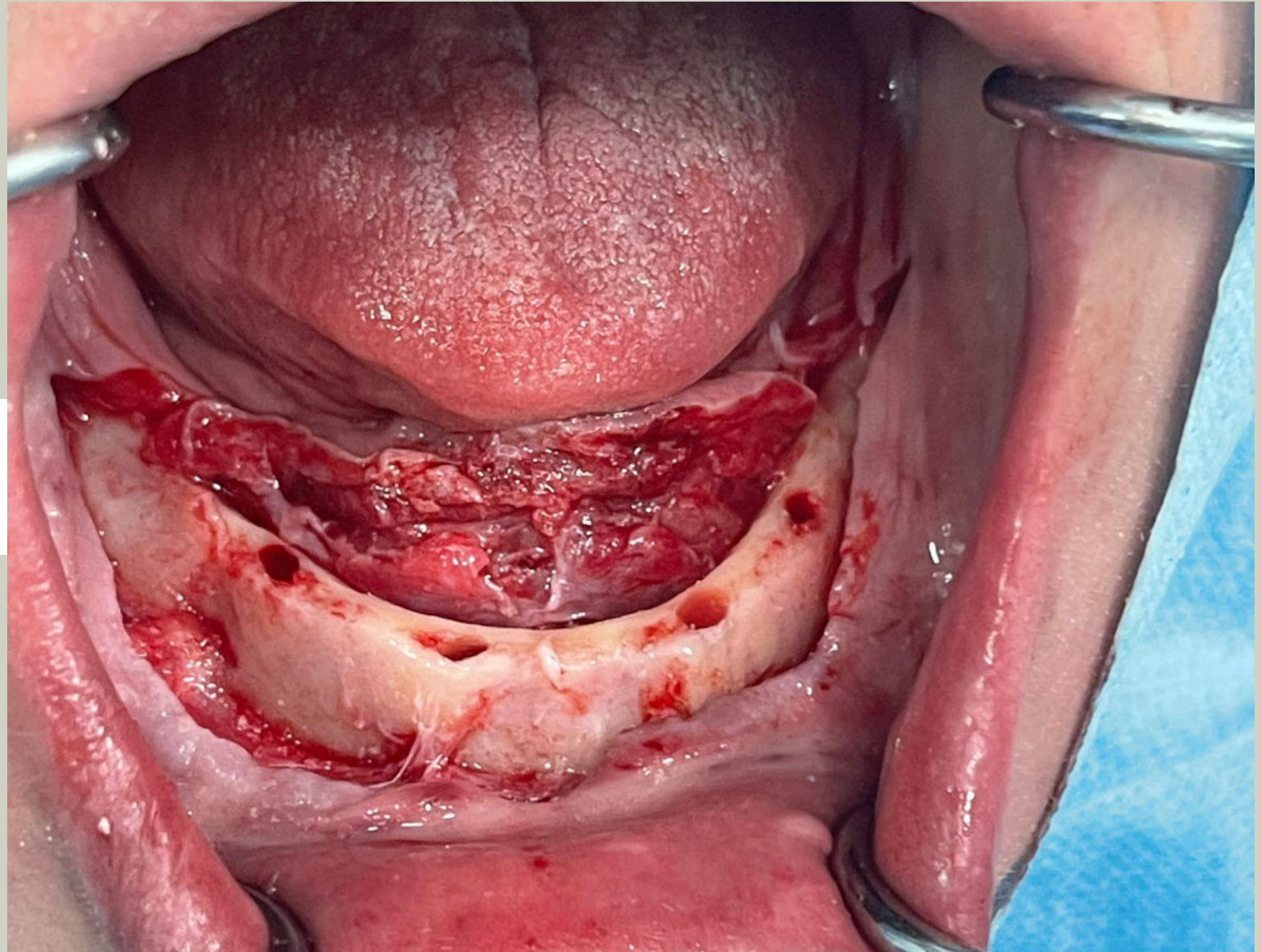


Prueba de dientes



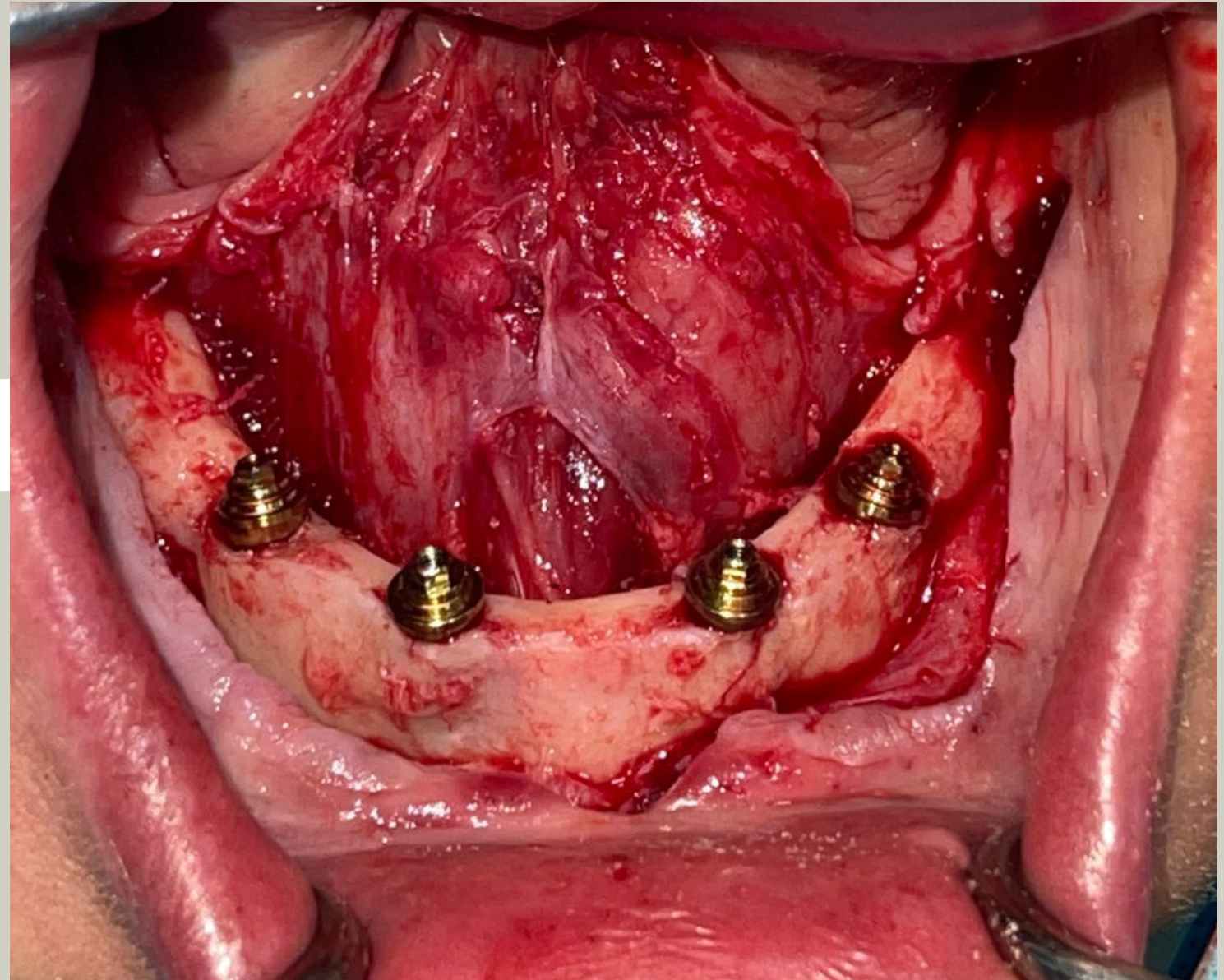
Cirugia

Arcada inferior -
fresado para all on
four



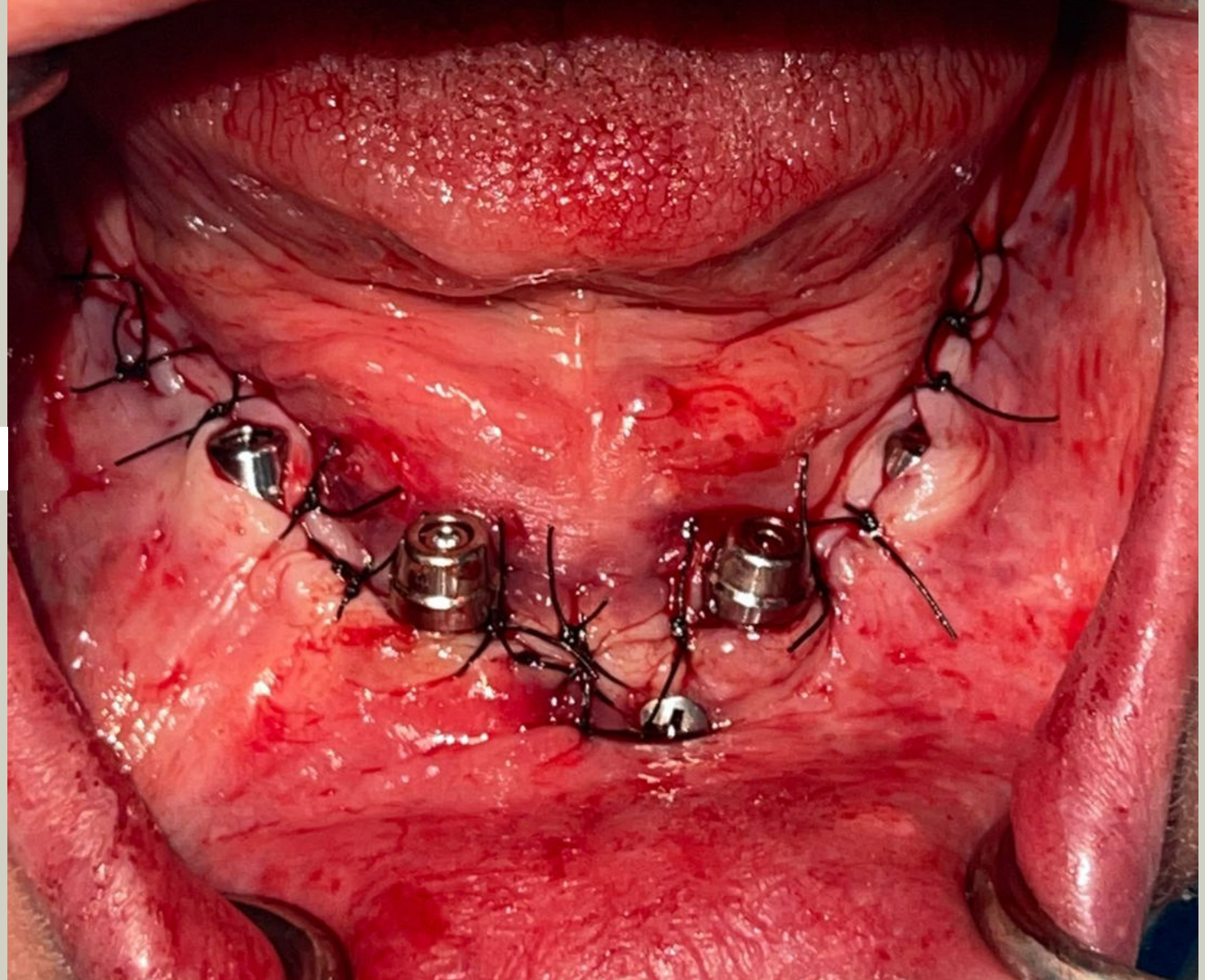
Cirugia

One abutment -
One time



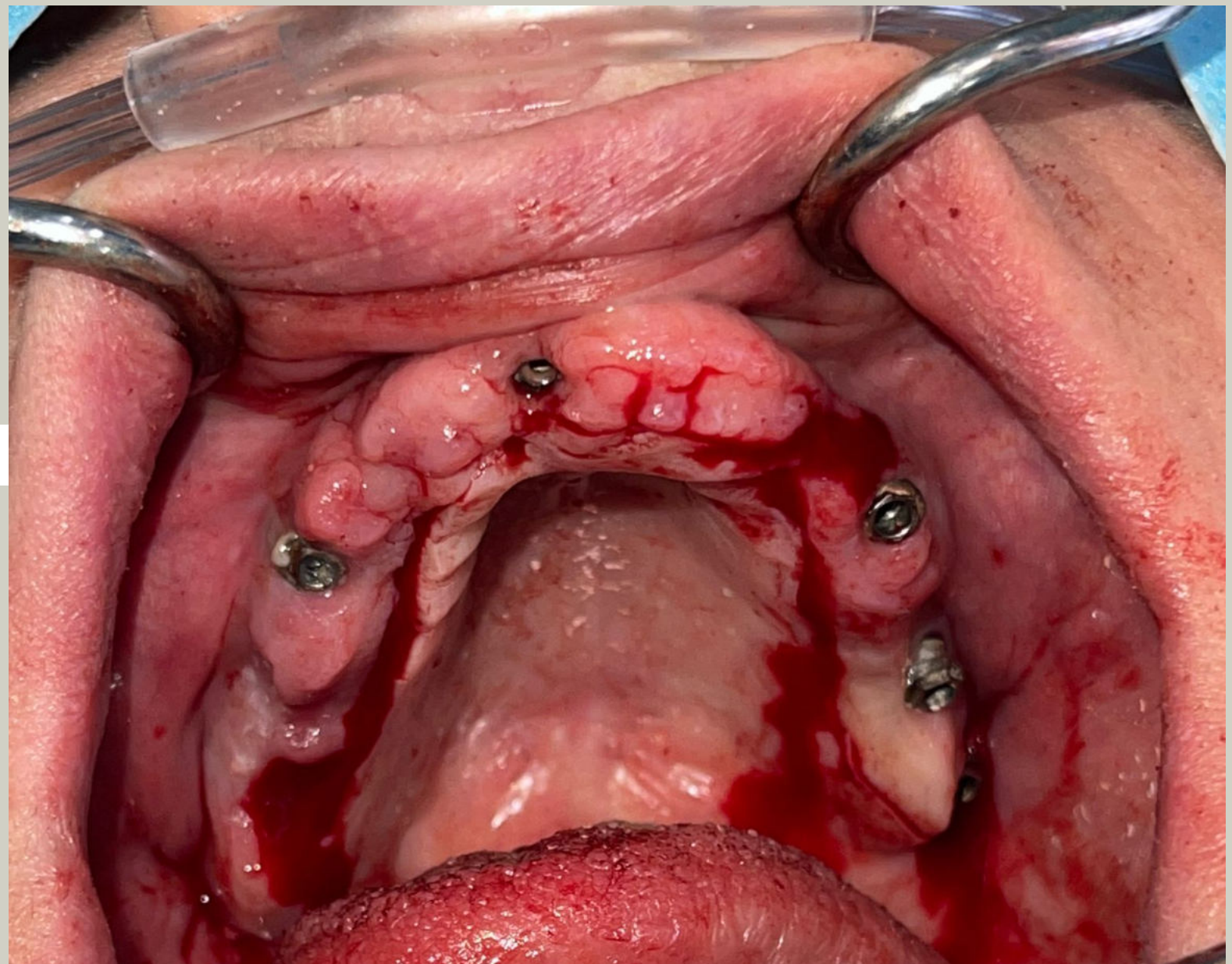
Cirugia

Sutura



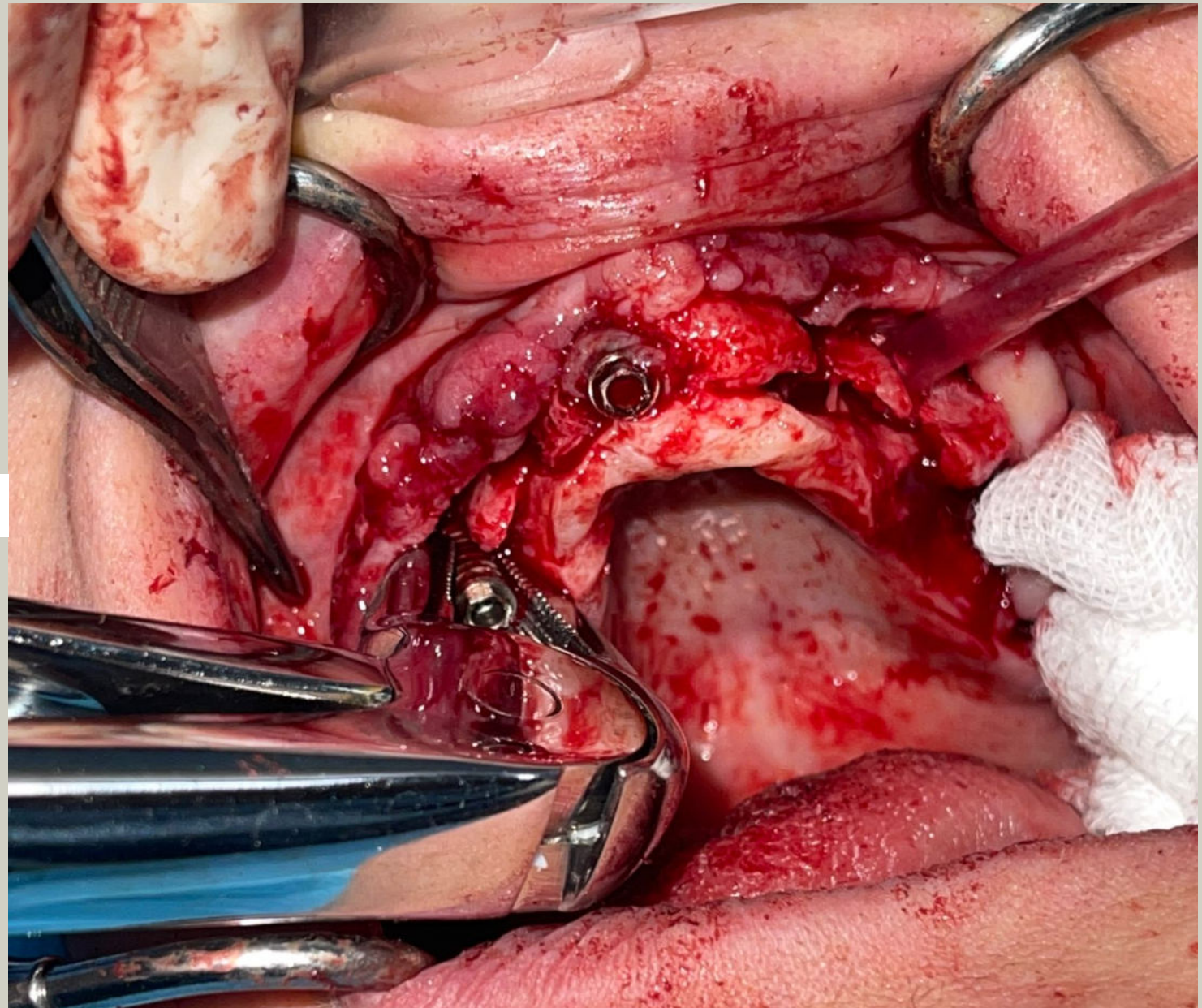
Cirugía

Incisión



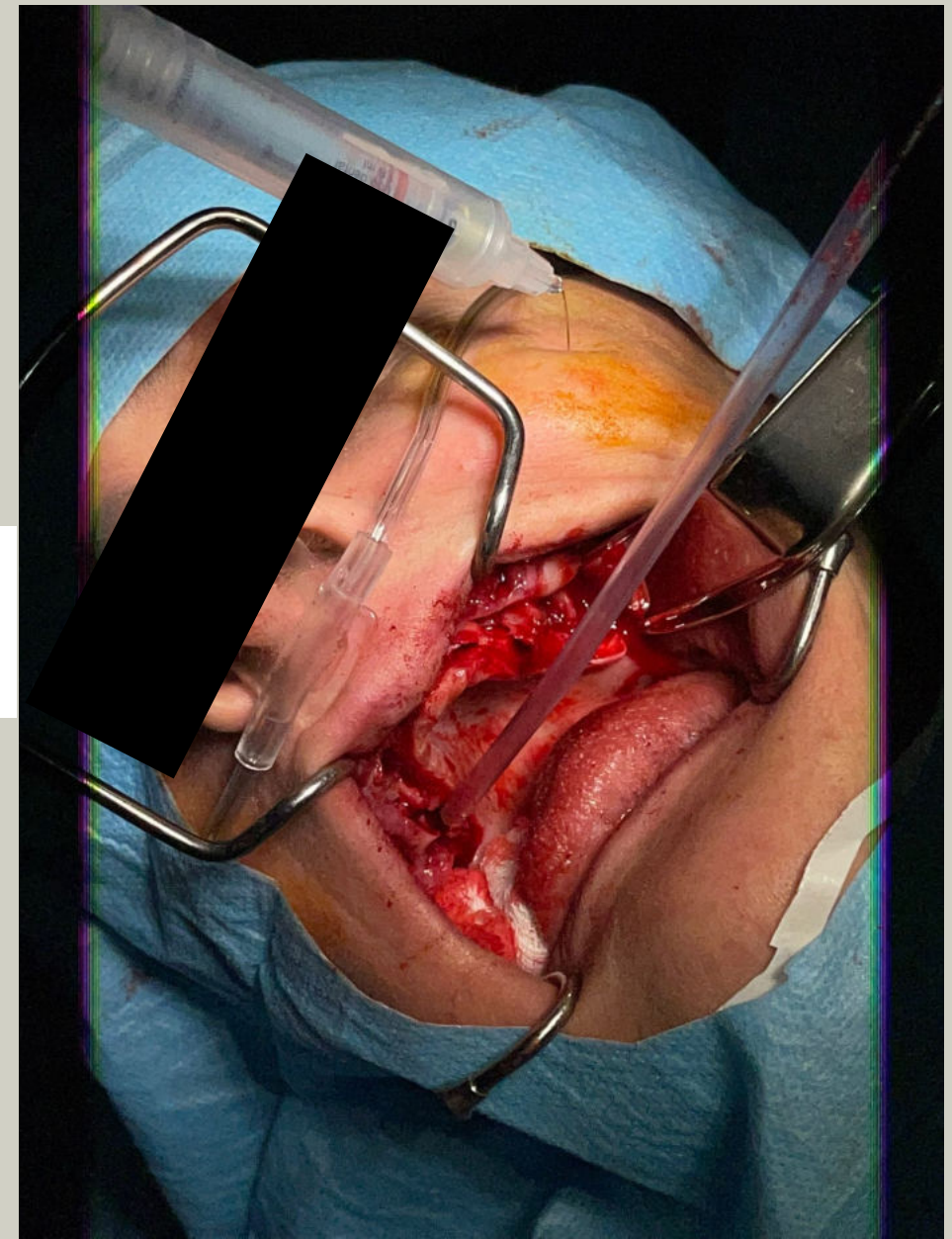Cirugía

Explantación



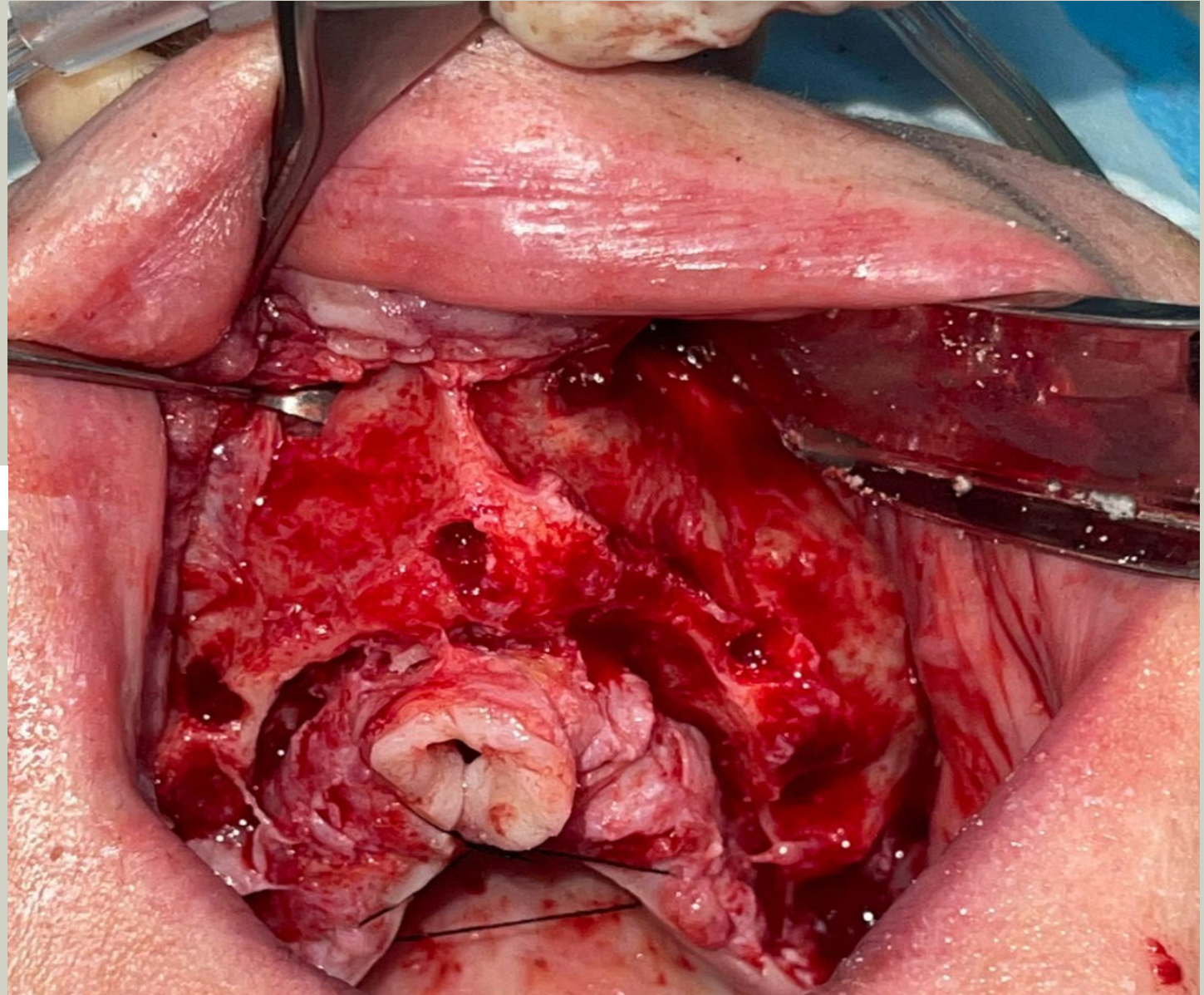
Cirugía

Anestesia para
implantes
cigomáticos



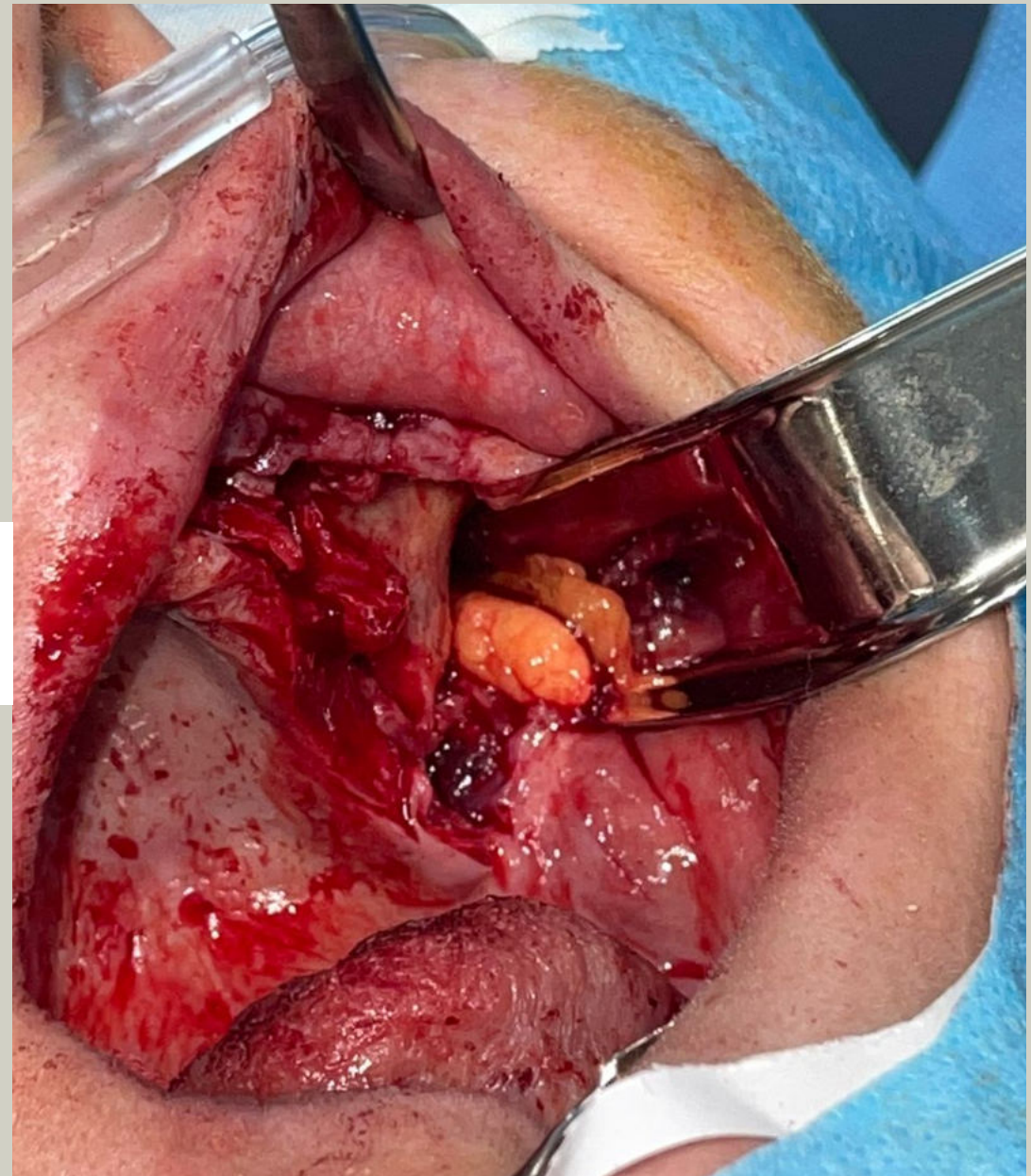
Cirugía

Despegamiento



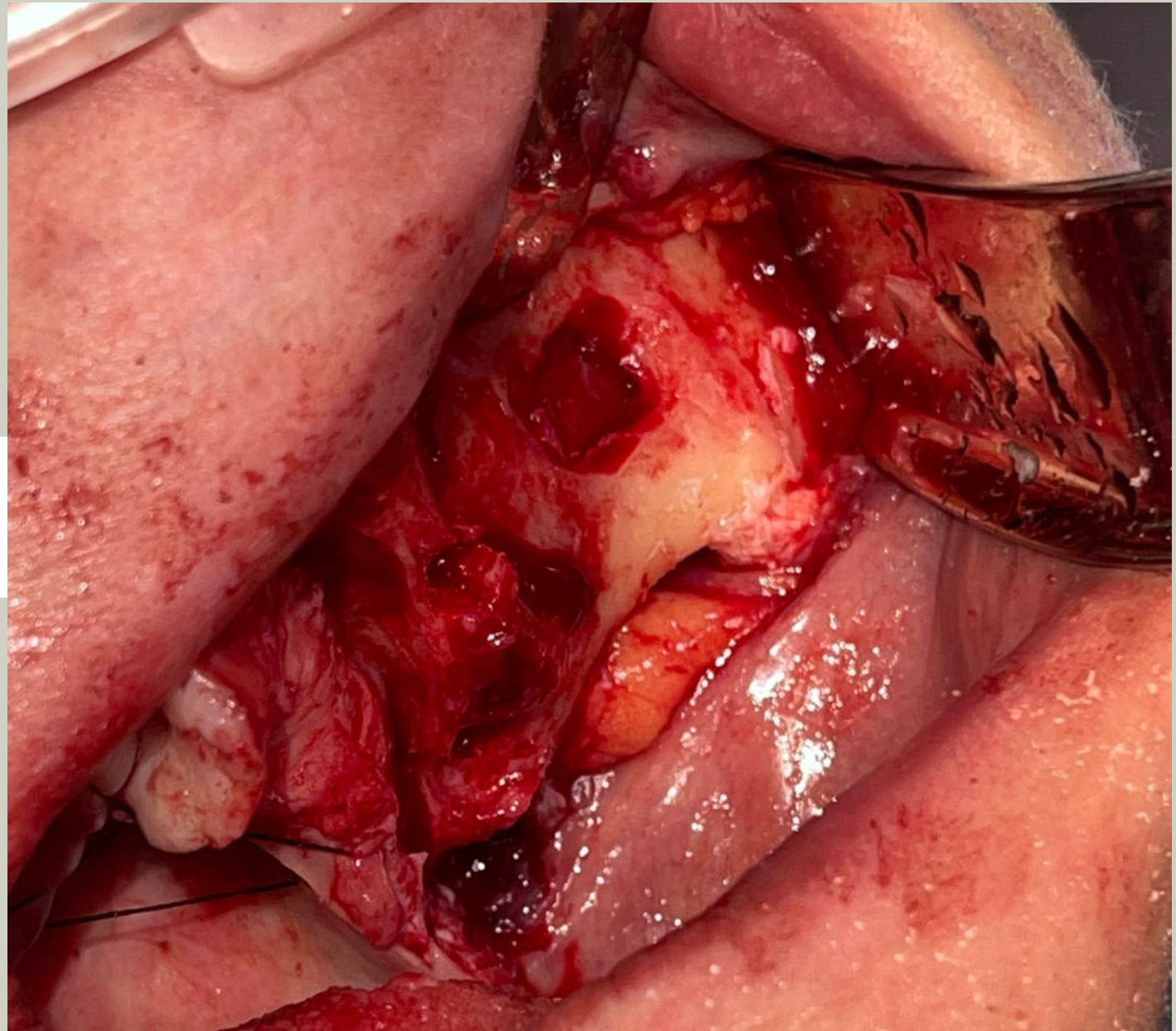
Cirugia

Acceso zona
malar + bola
de bichat



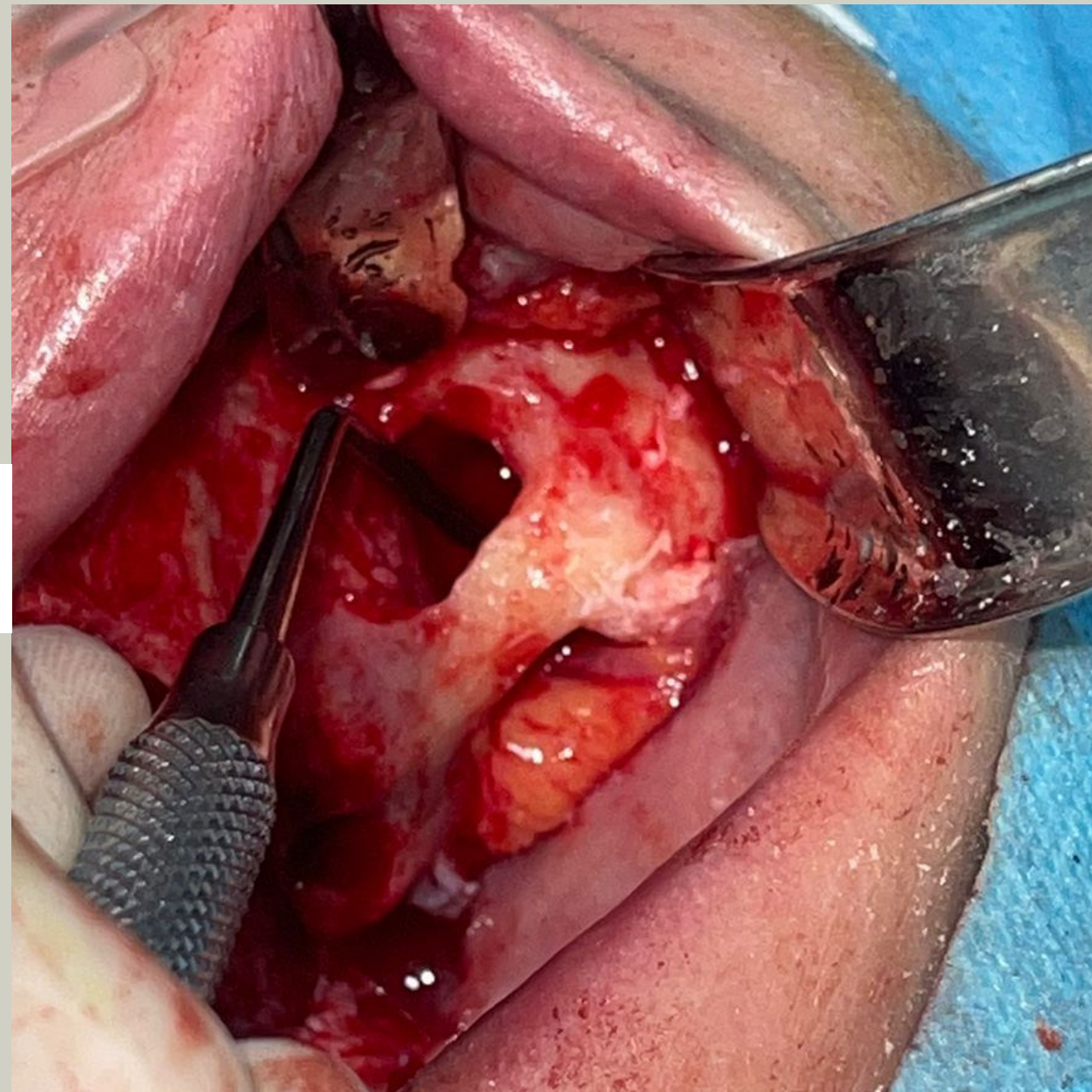
Cirugía

Ventana para
acceder al hueso
malar



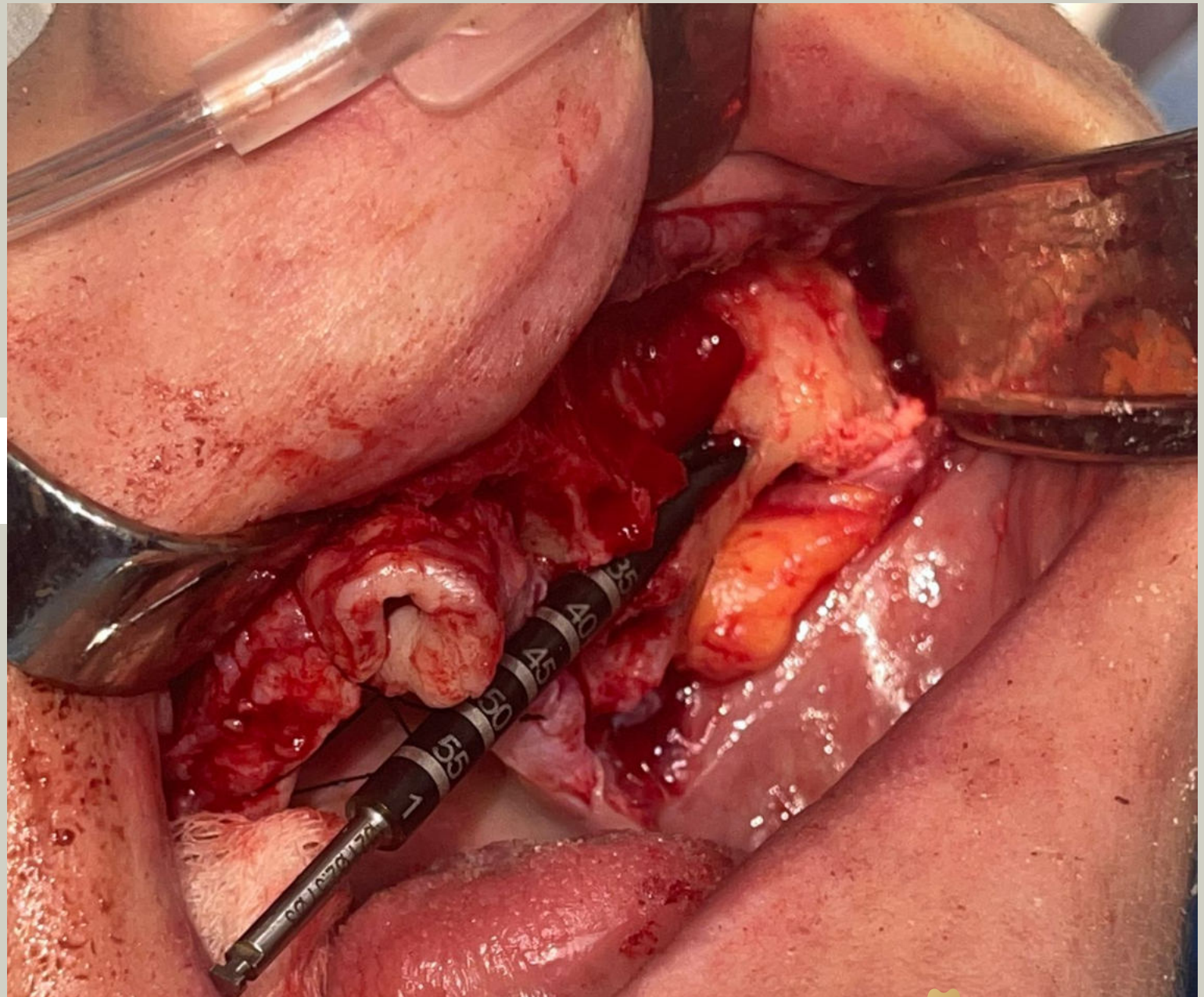
Cirugía

Elevación de la
membrana de
Schneider

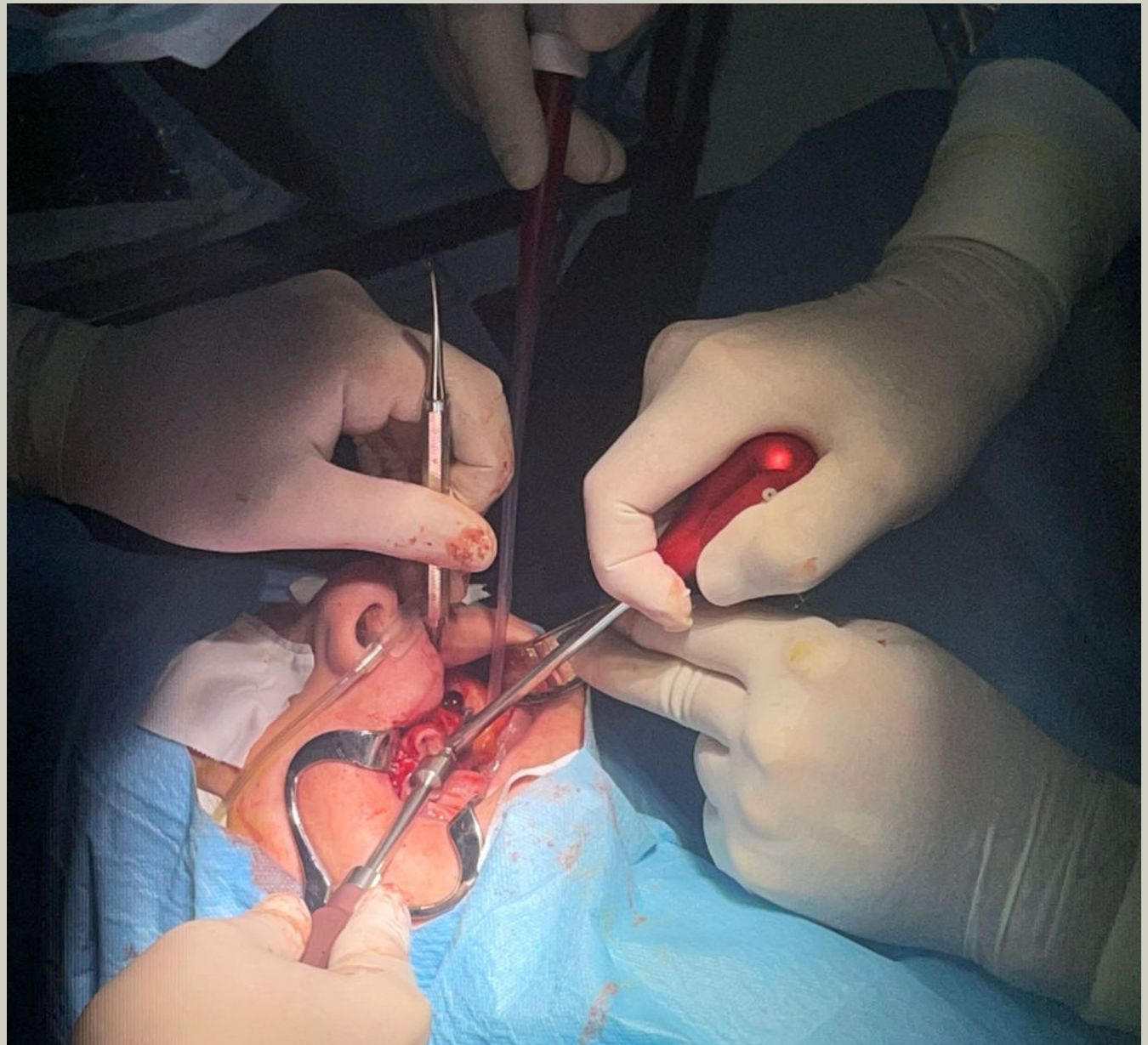
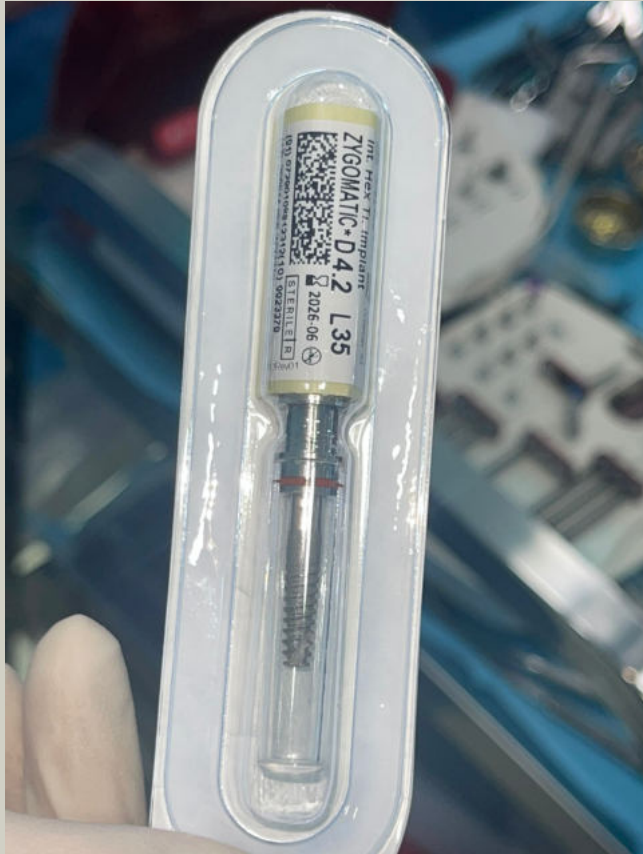

Cirugía

Fresado para
implante cigomático

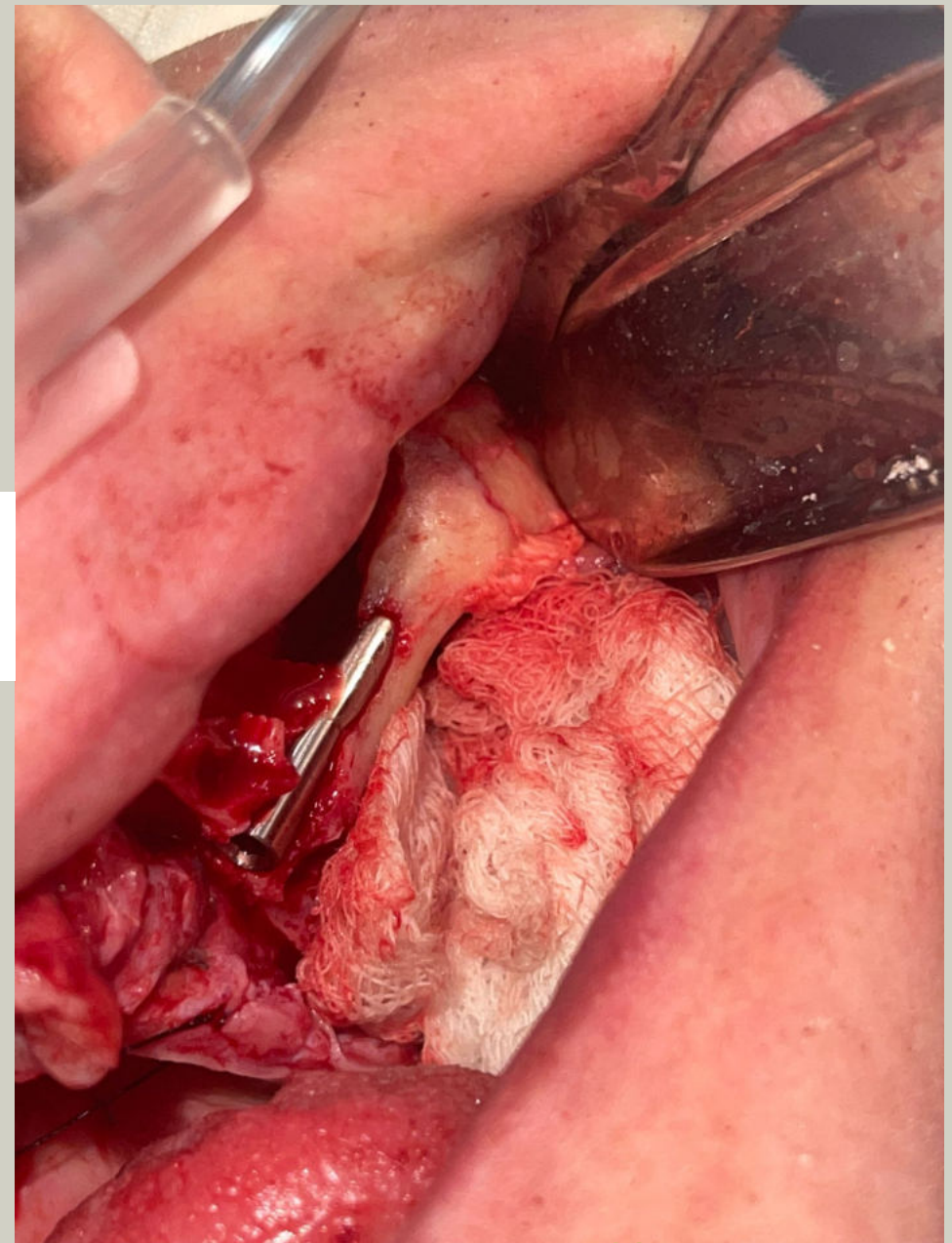


Cirugía



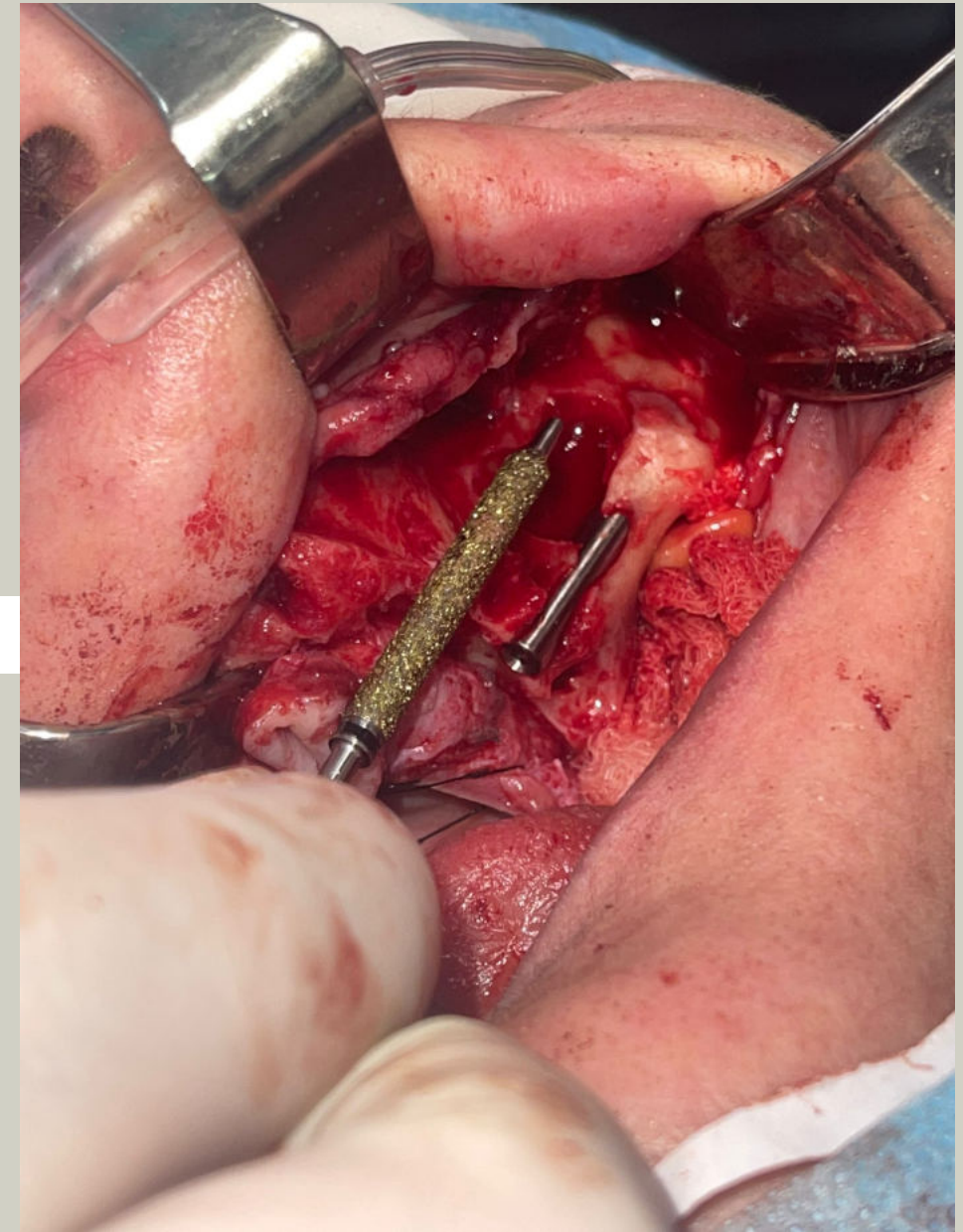
Cirugía

Colocación del primer
implante cigomático en
el segundo cuadrante



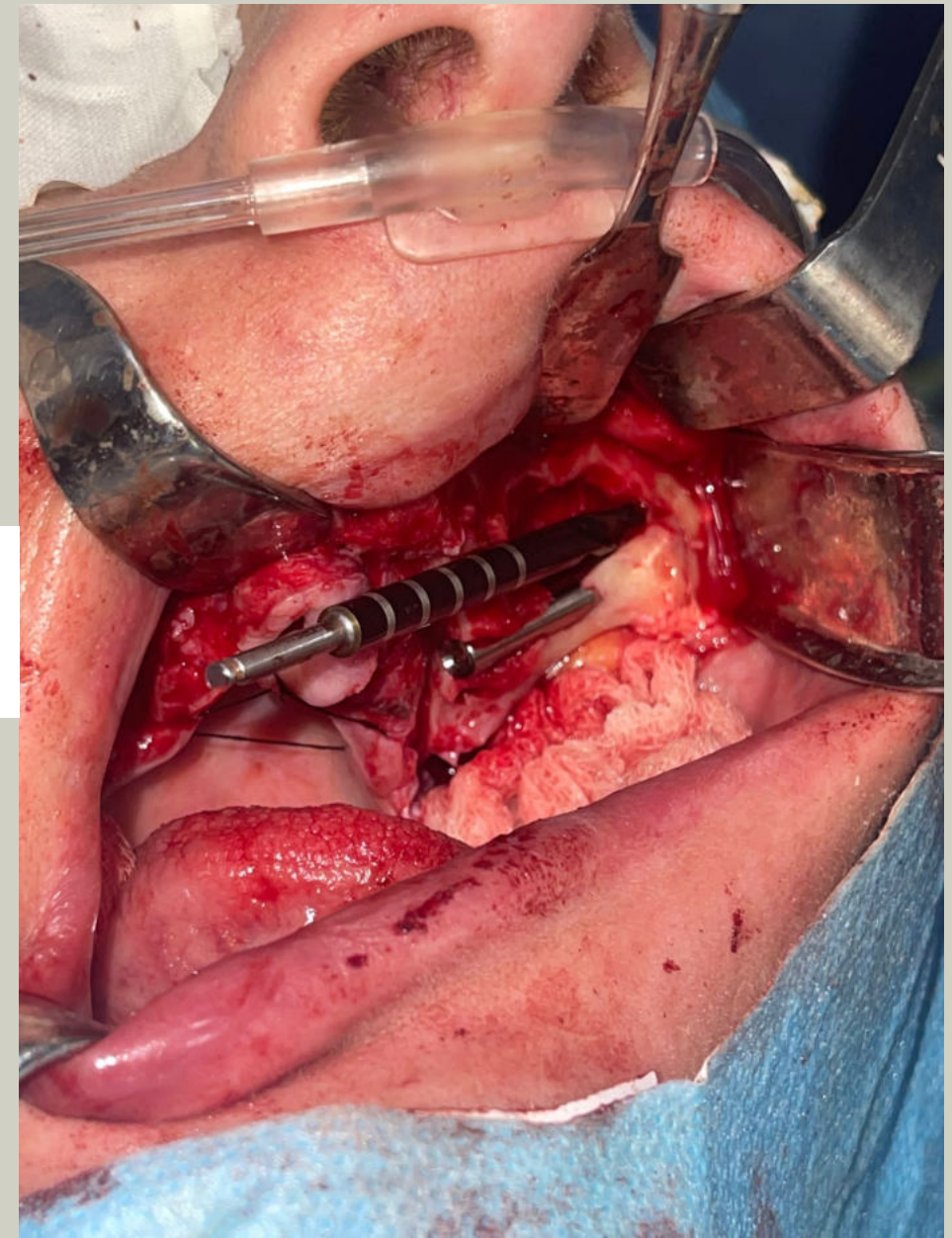Cirugía

Fresado



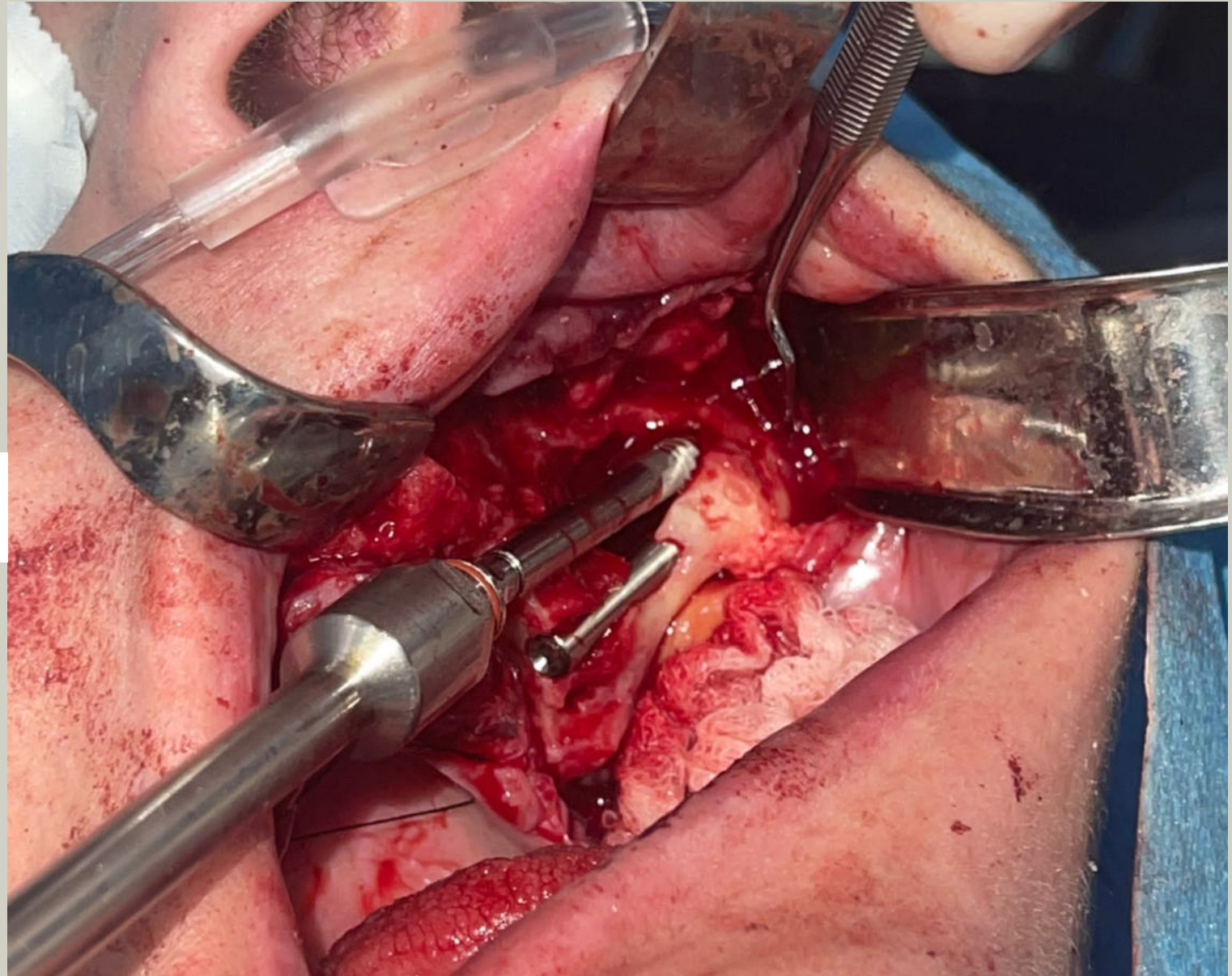
Cirugía

Elección del
implante
cigomático



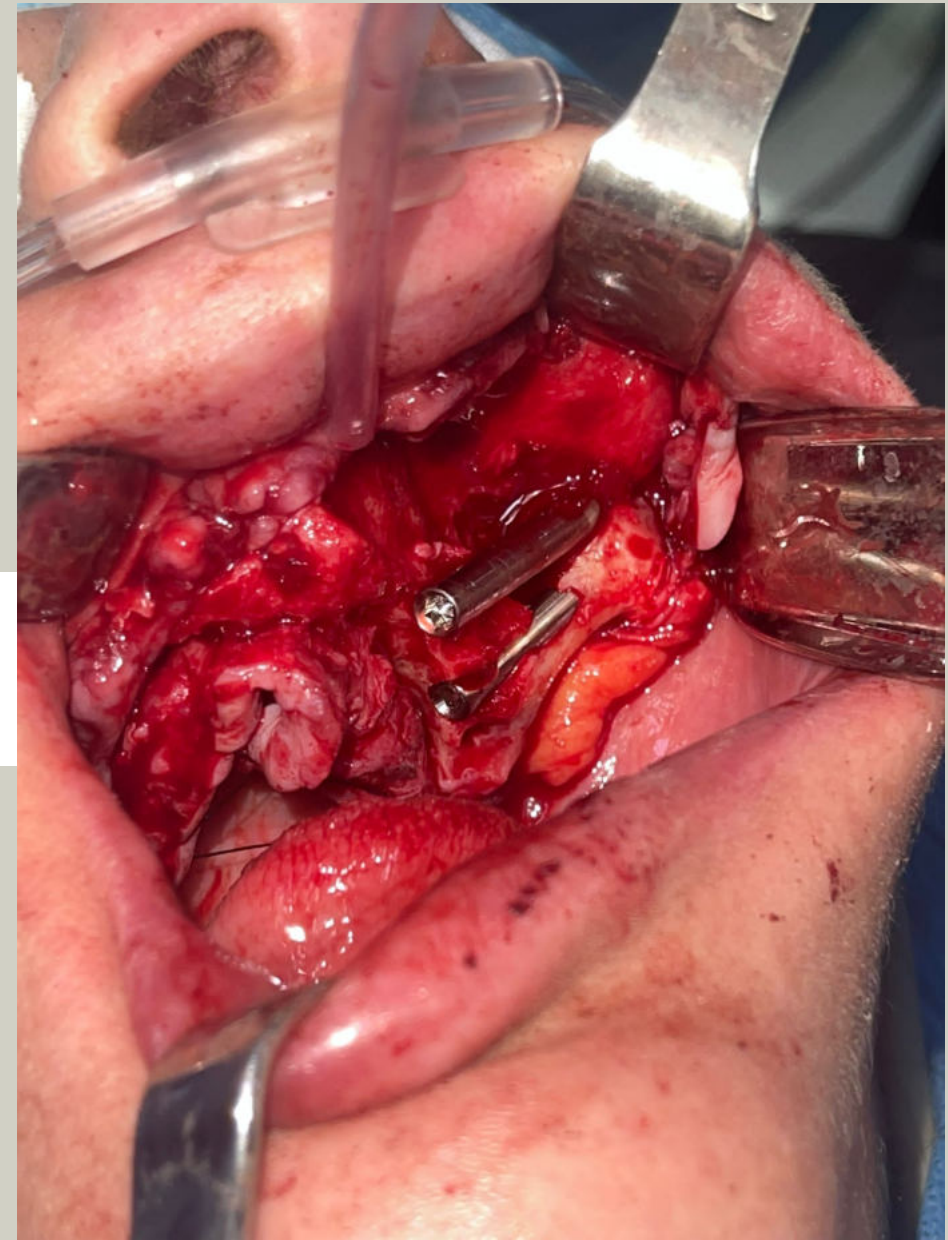Cirugía

Colocación del segundo
implante cigomático



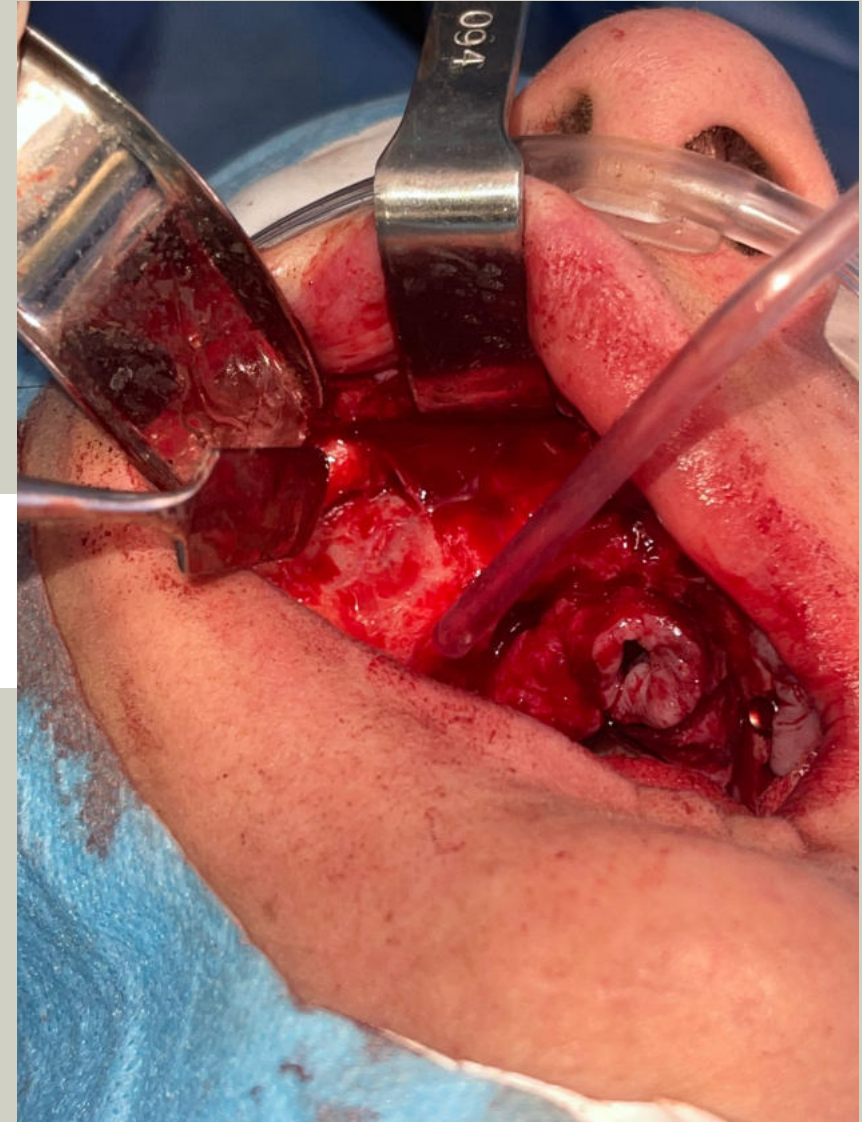Cirugía

Segundo implante
cigomático
colocado



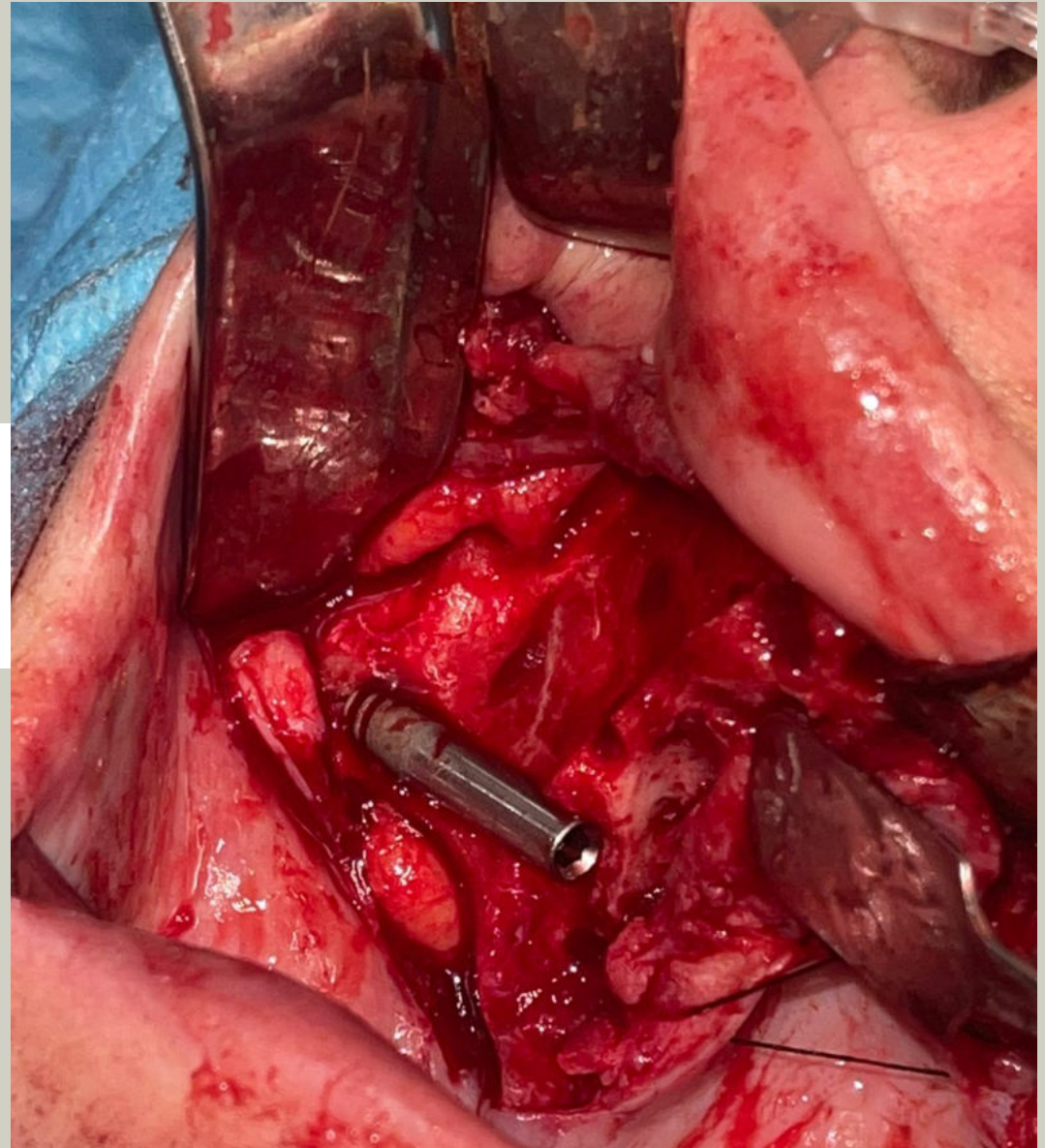
Cirugía

Acceso en el
primer
cuadrante



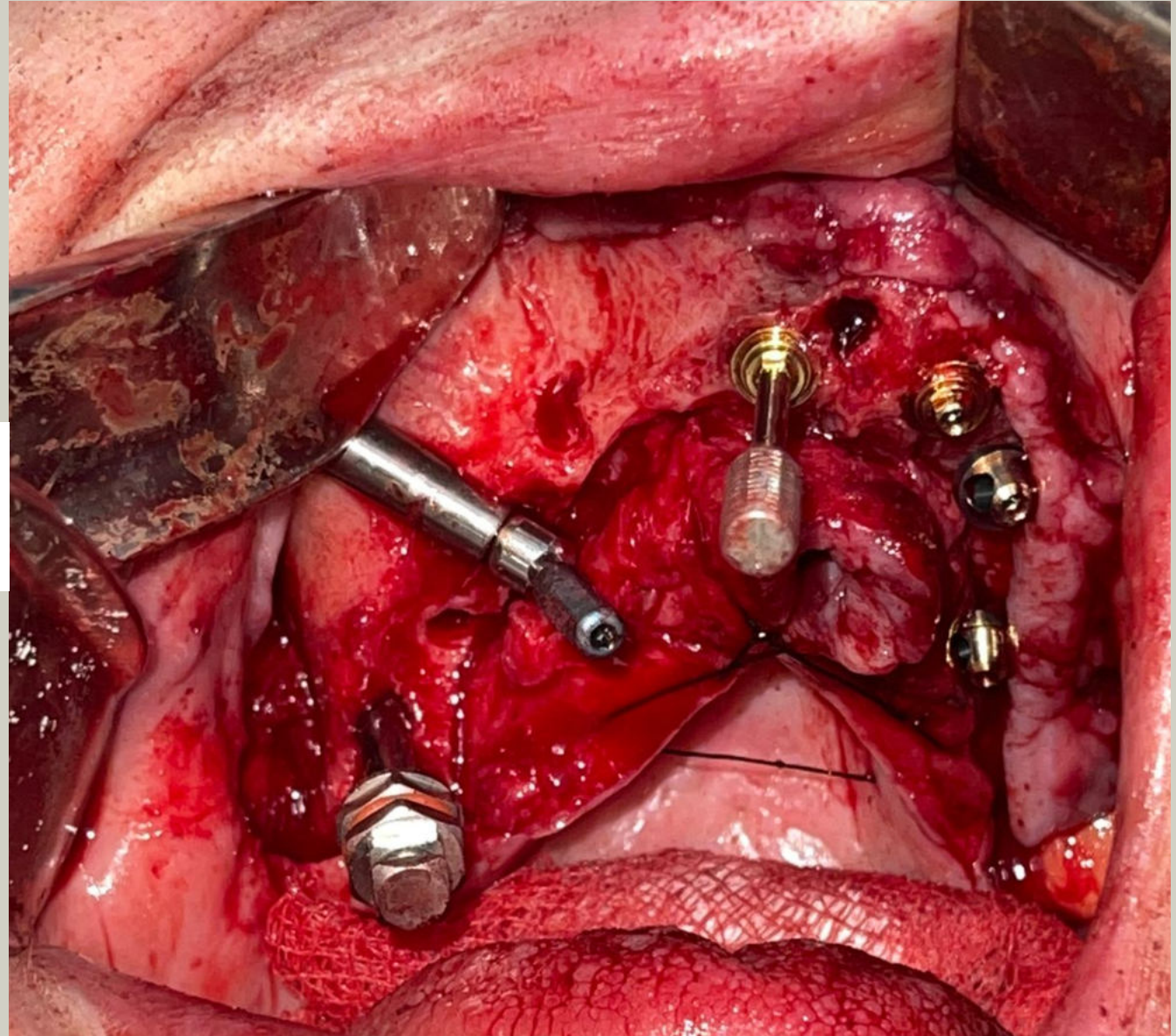
Cirugía

Implante
cigomático en
el primer
cuadrante



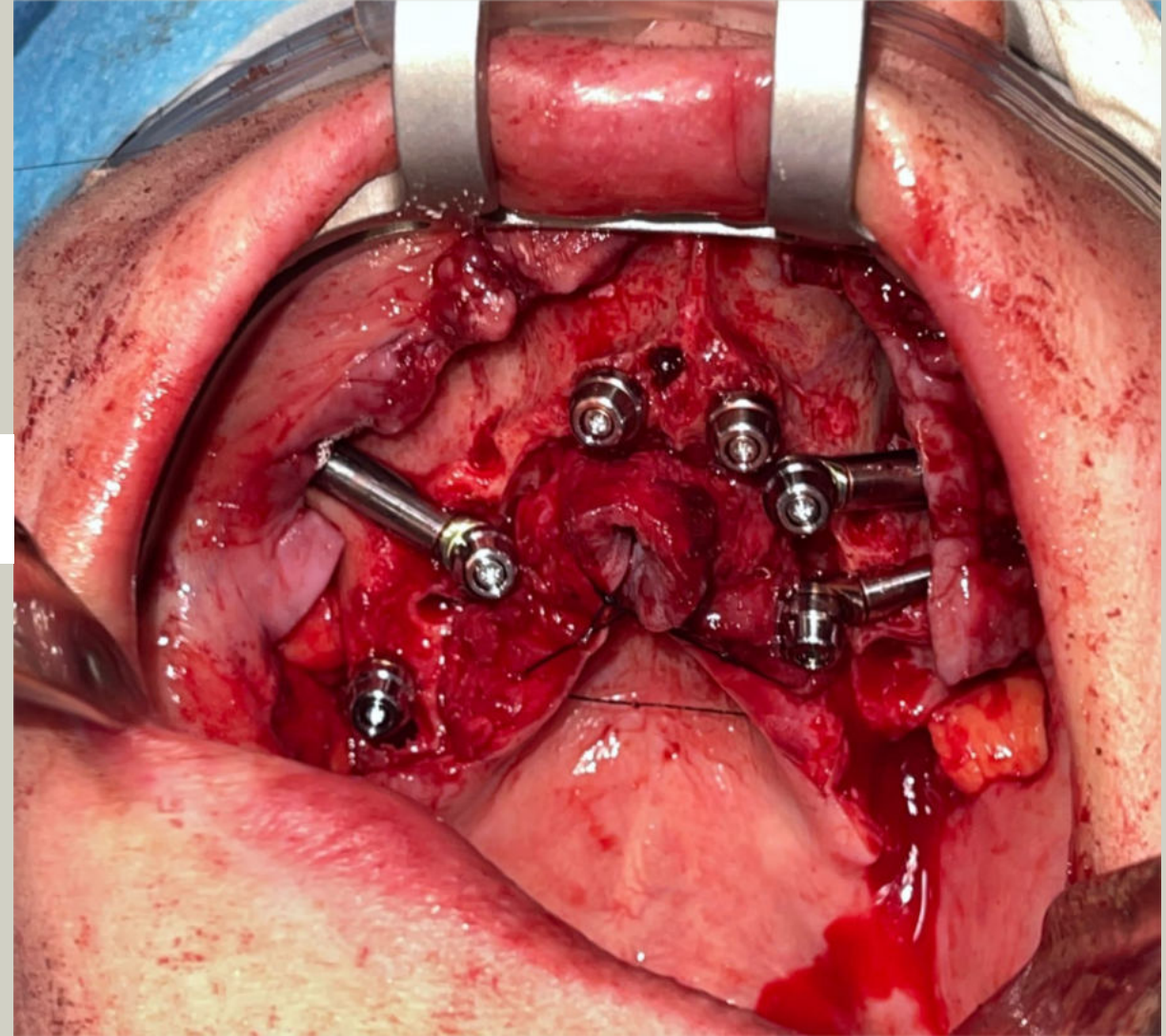
Cirugía

Elección de transepiteliales, one abutment-one time



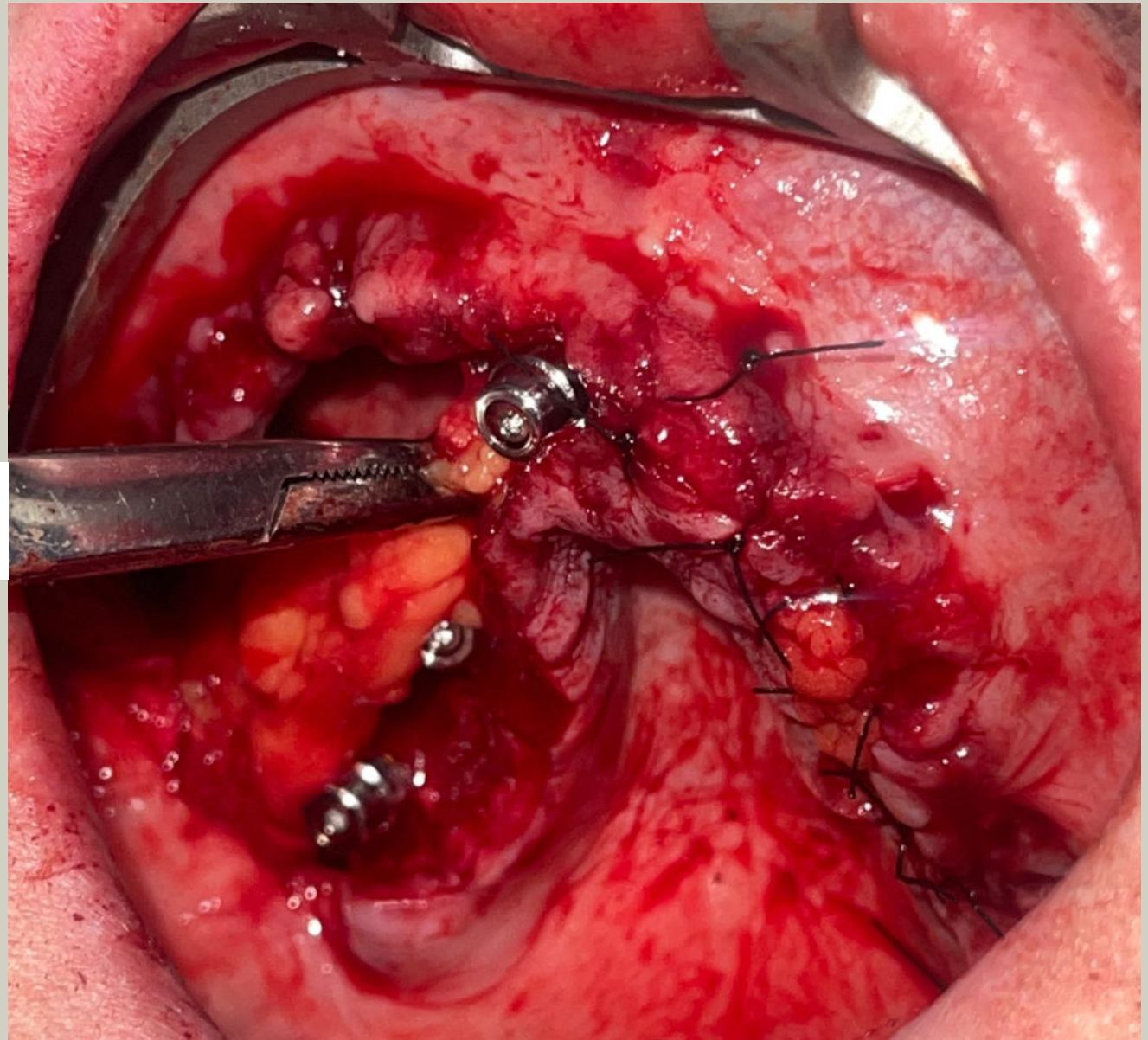
Cirugía

Situación global
antes de suturar



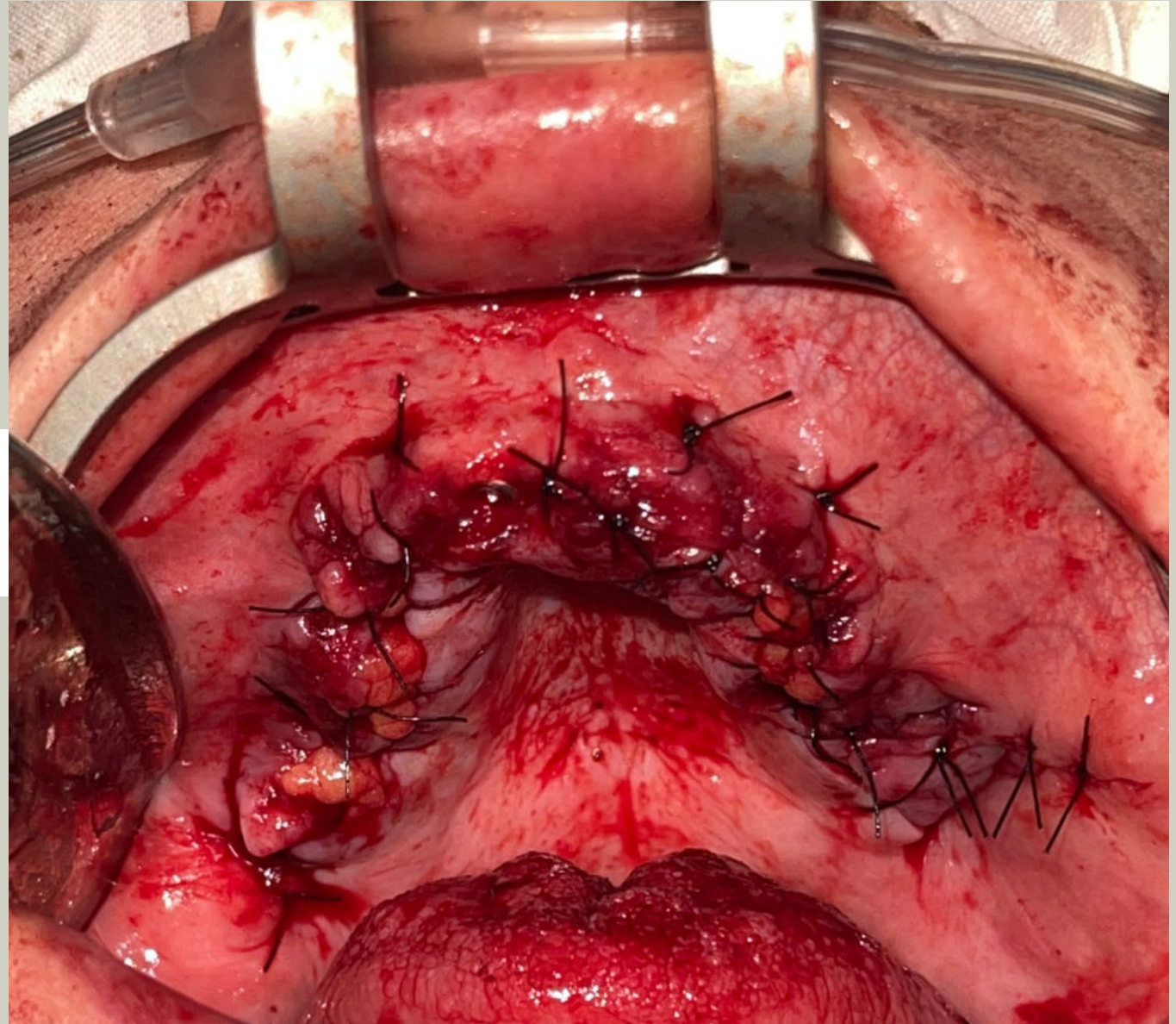Cirugia

Bola de
bichat

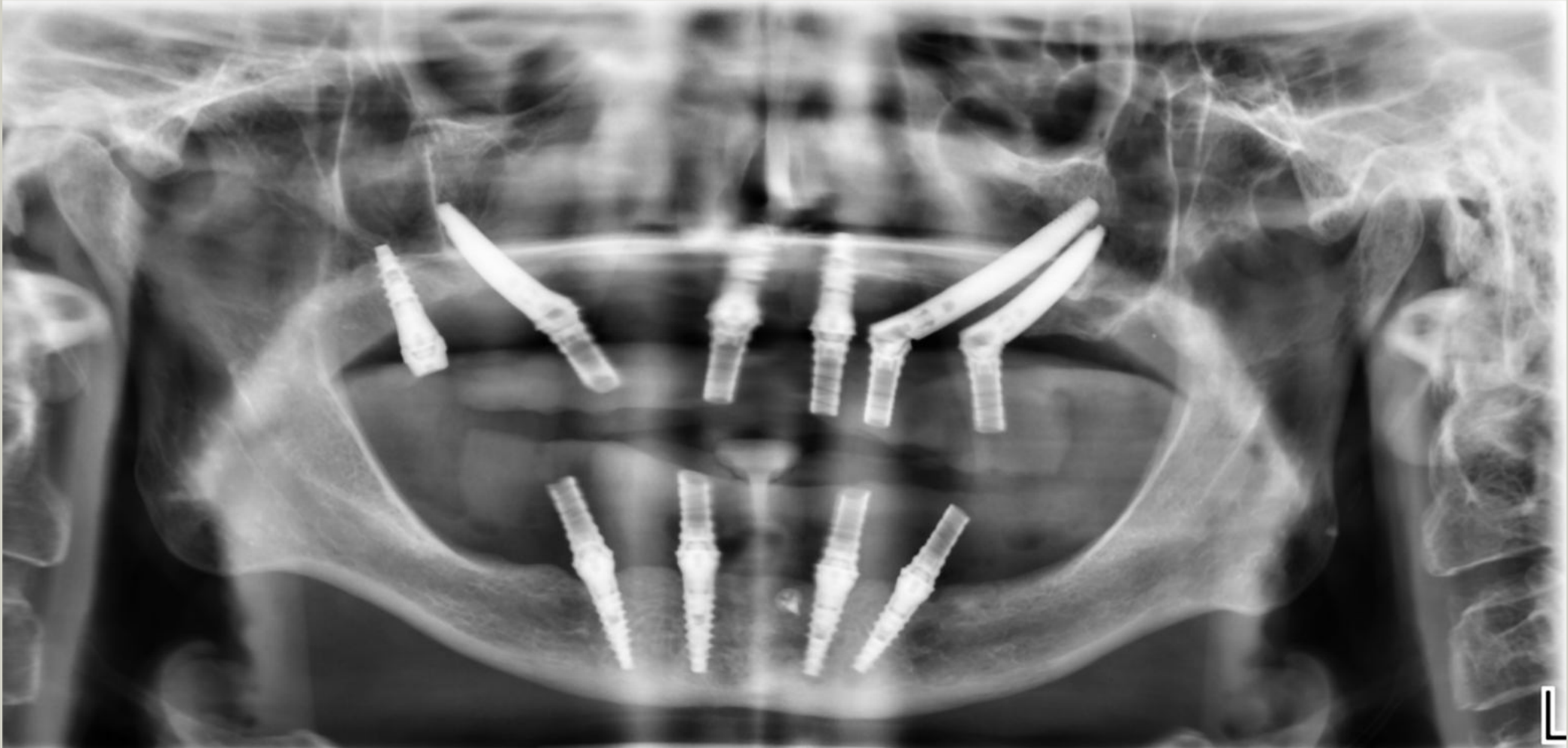


Cirugía

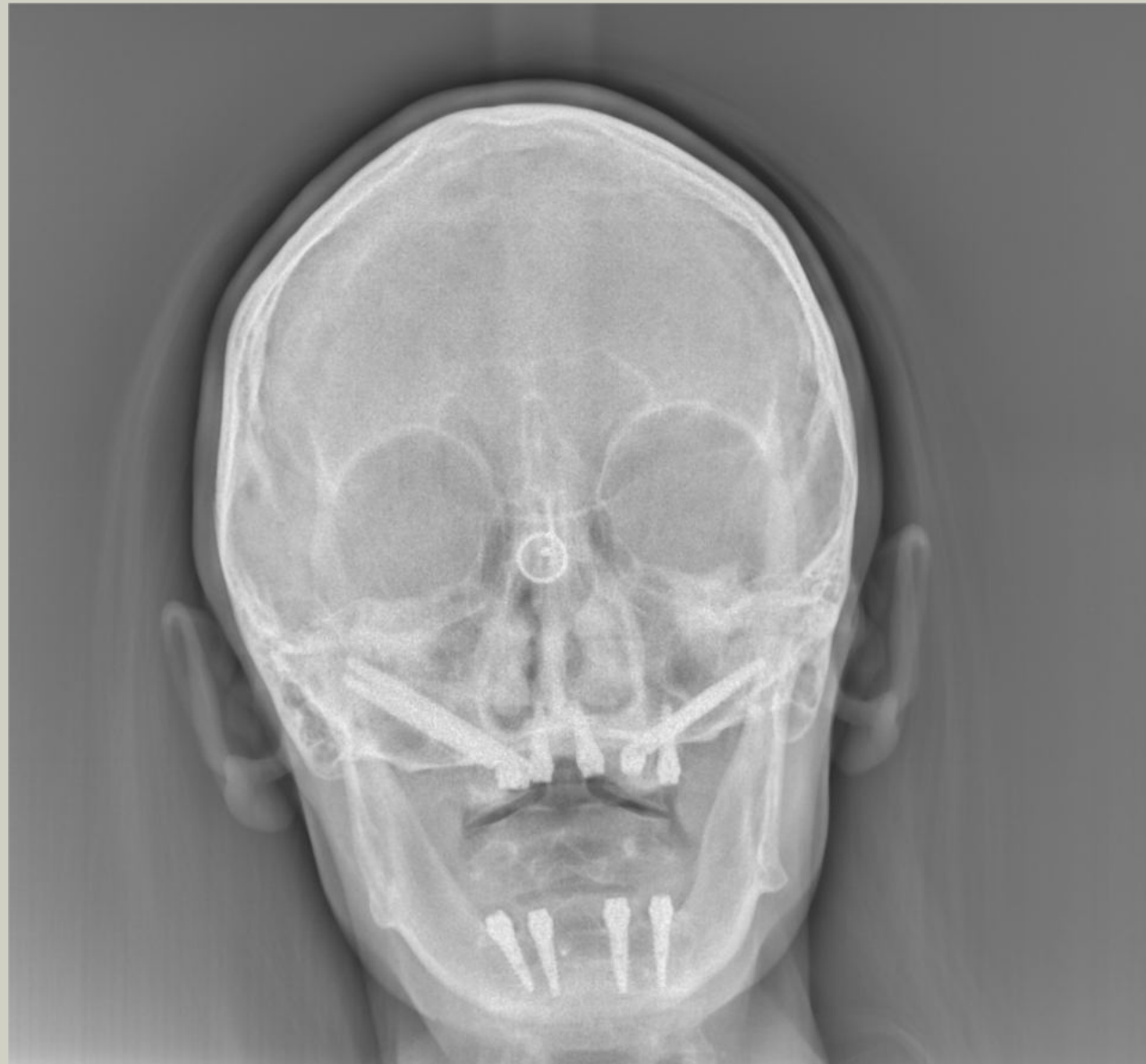Sutura antes de la
colocación de la
carga inmediata



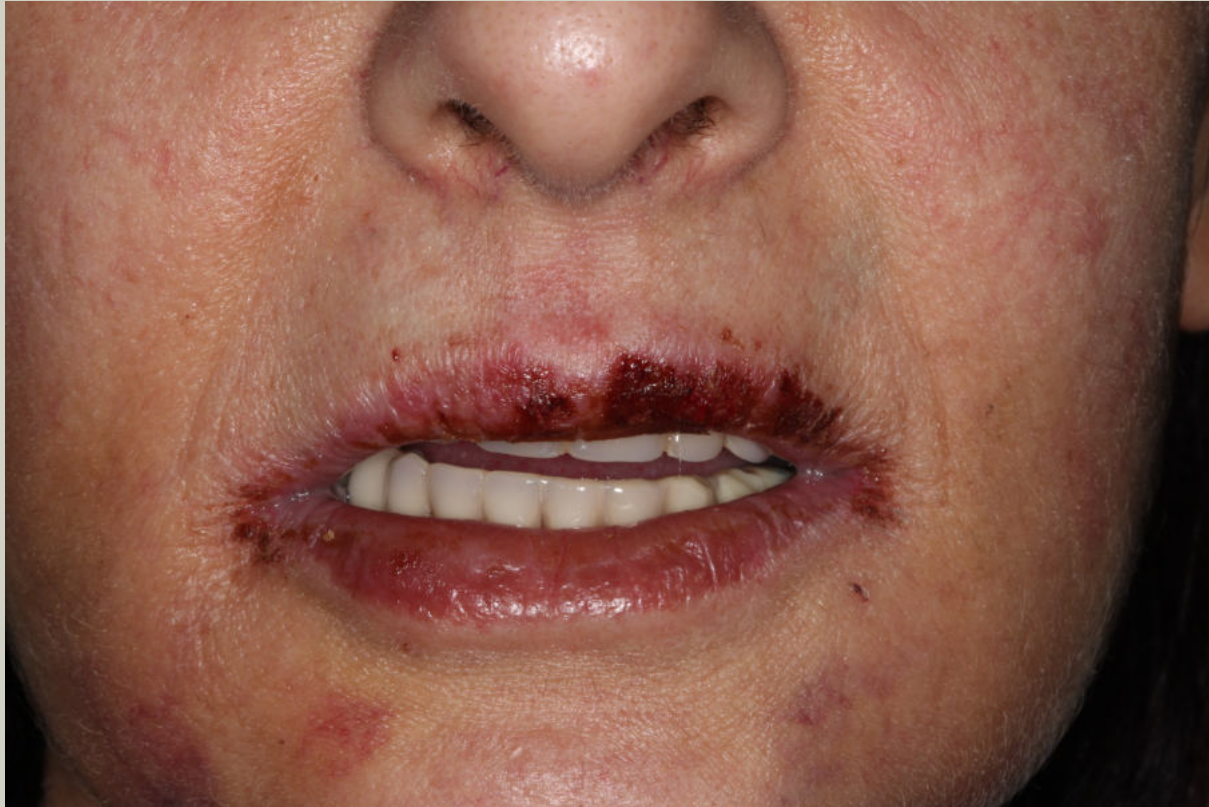Radiografía



Radiografía



Revisión 24 horas



Rosa C. M. M.

Rosa C. M. M.

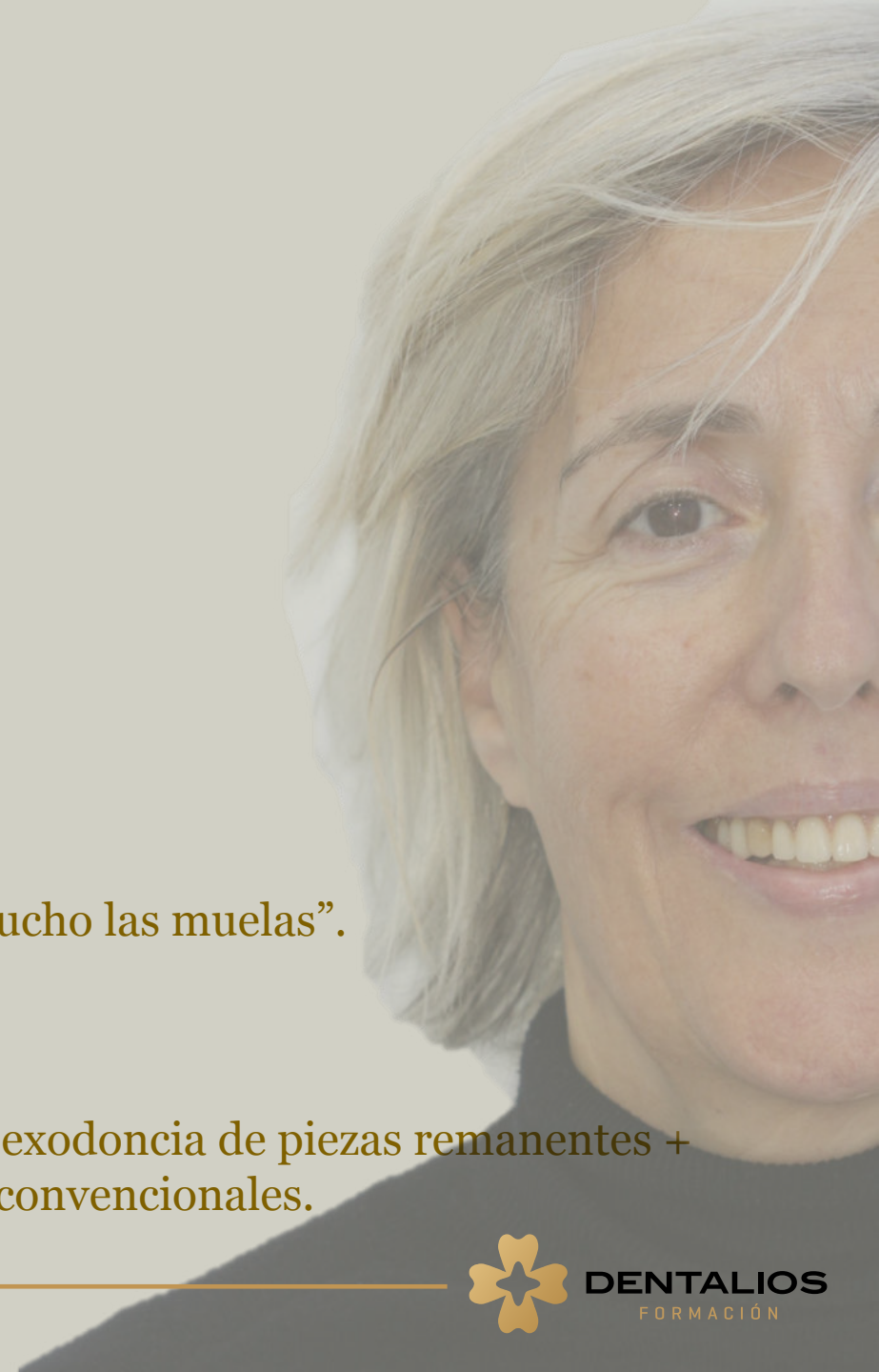Edad: 59 años.

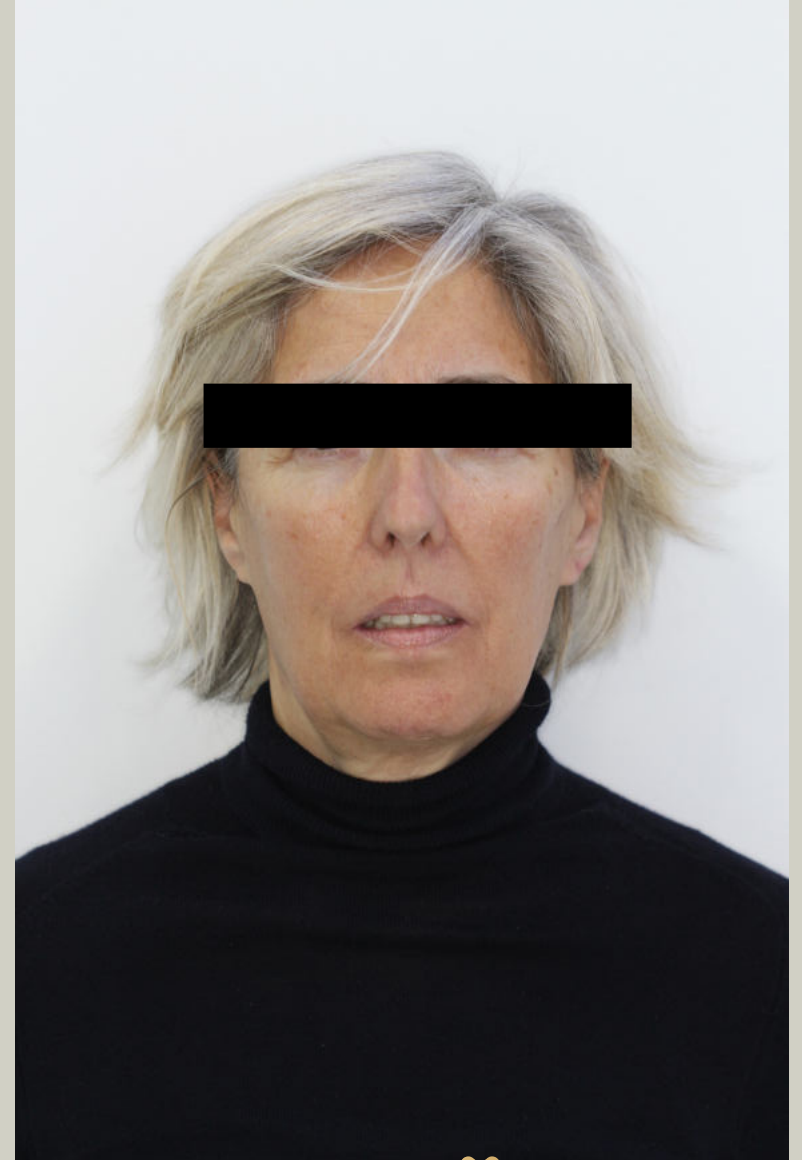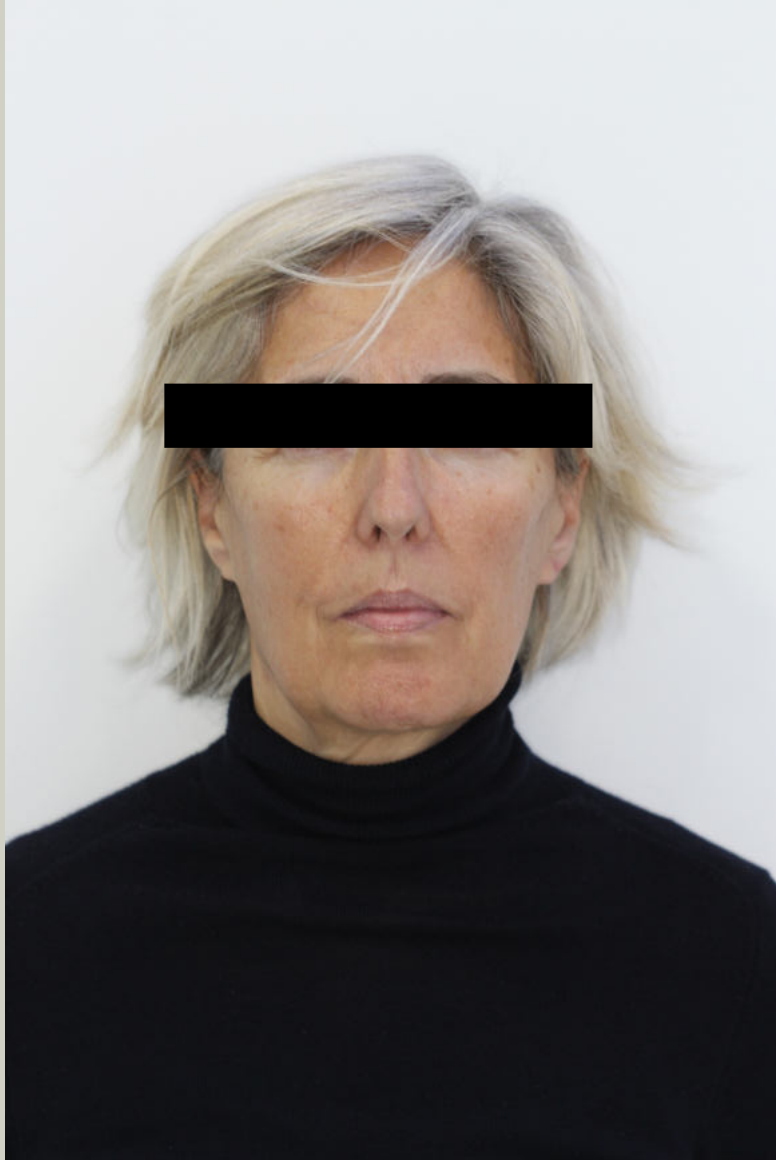Motivo de consulta: “Me han fracasado los implantes y se me mueven mucho las muelas”.

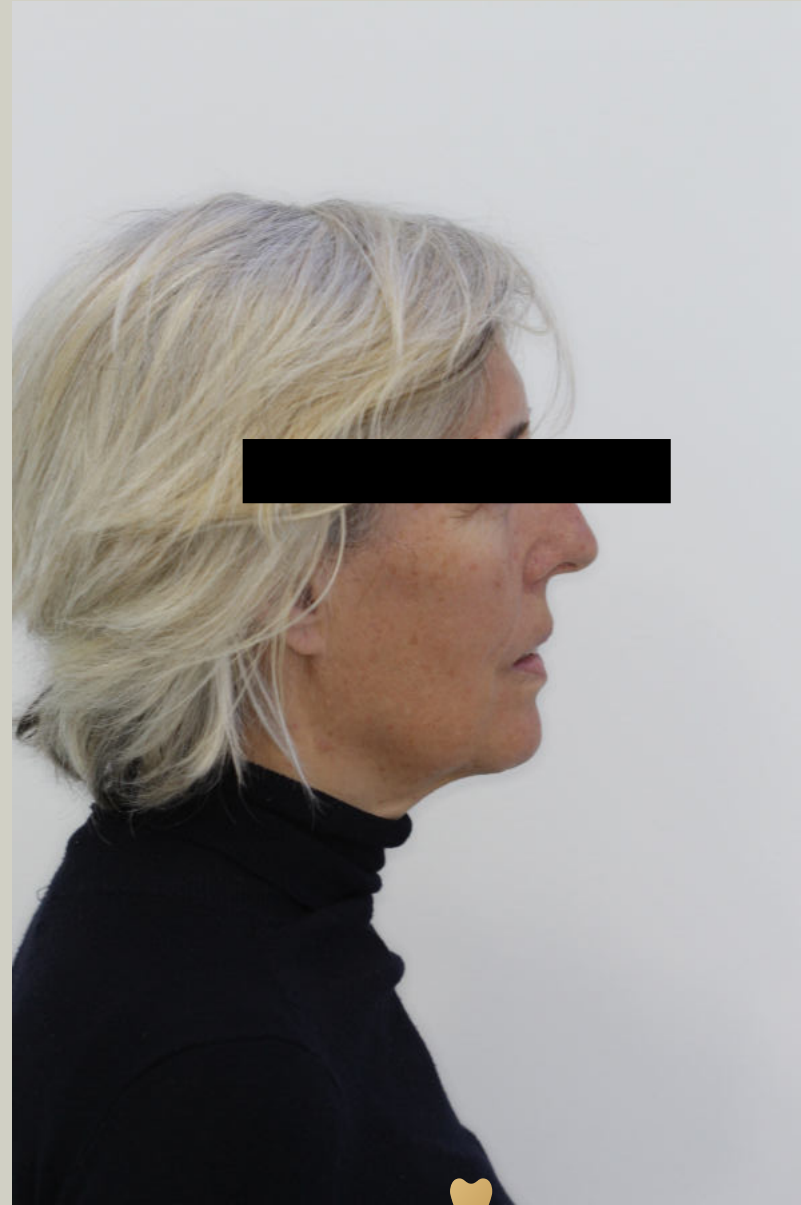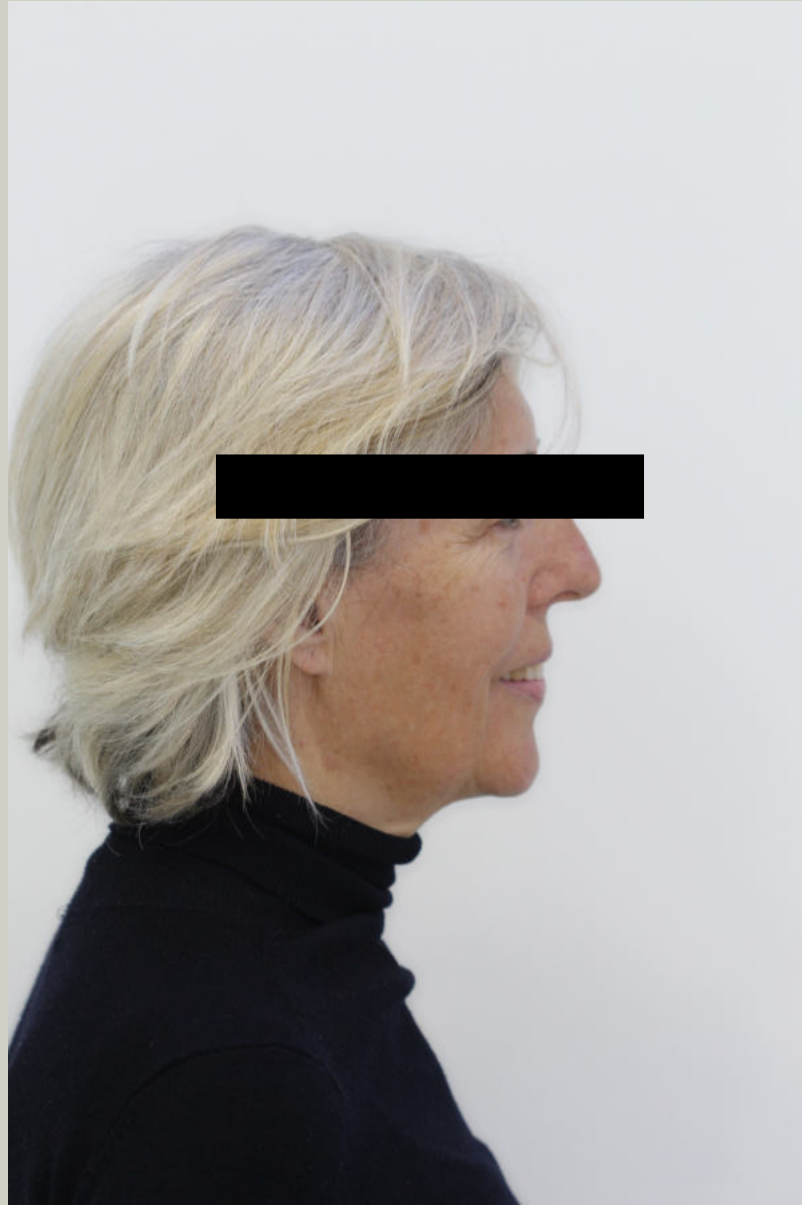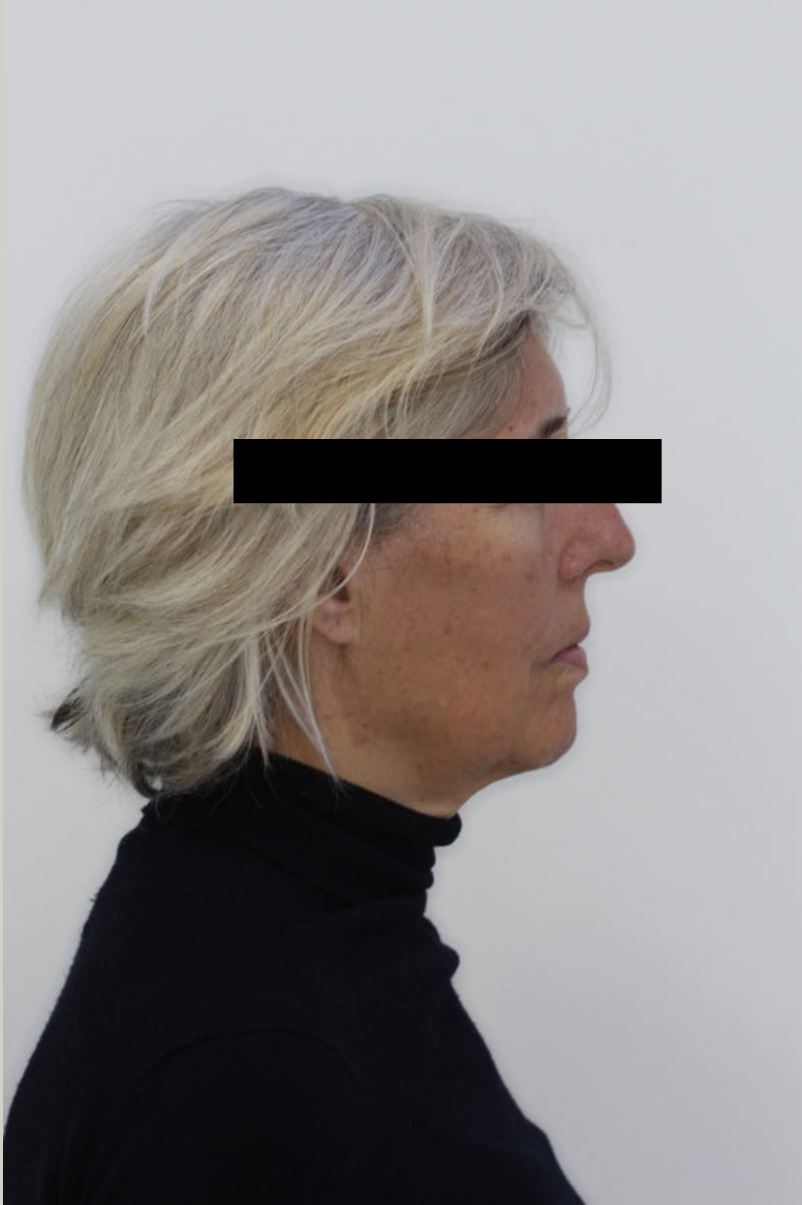Antecedentes médicos de interés:

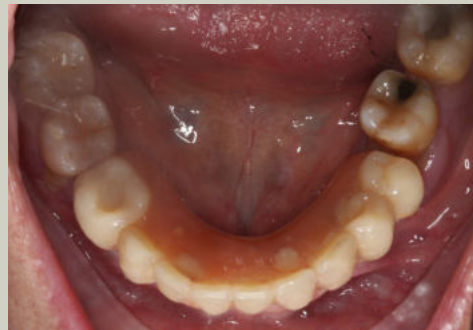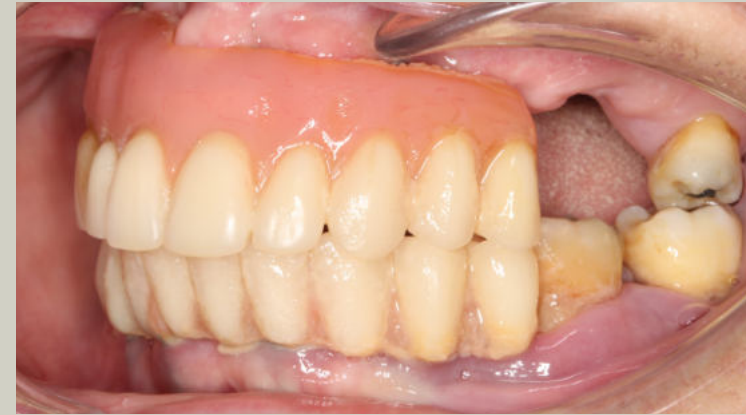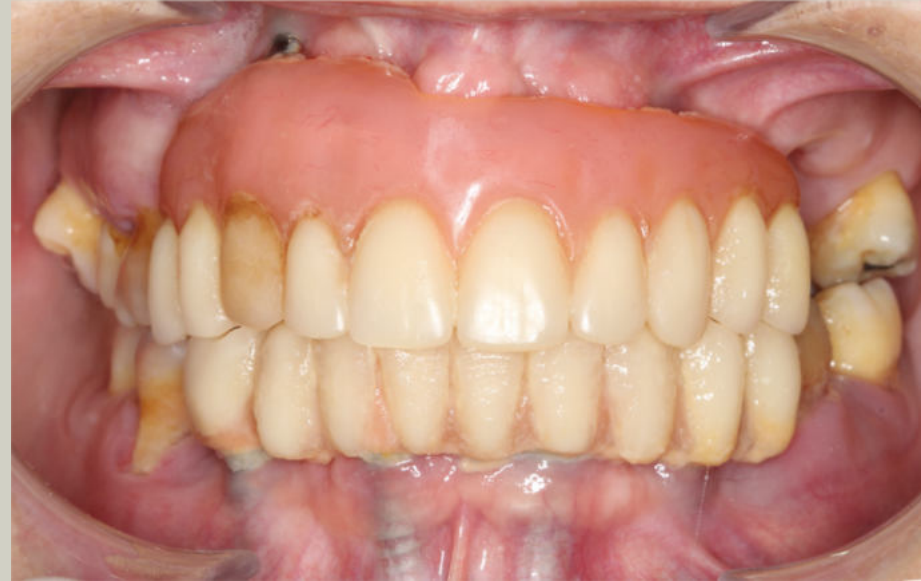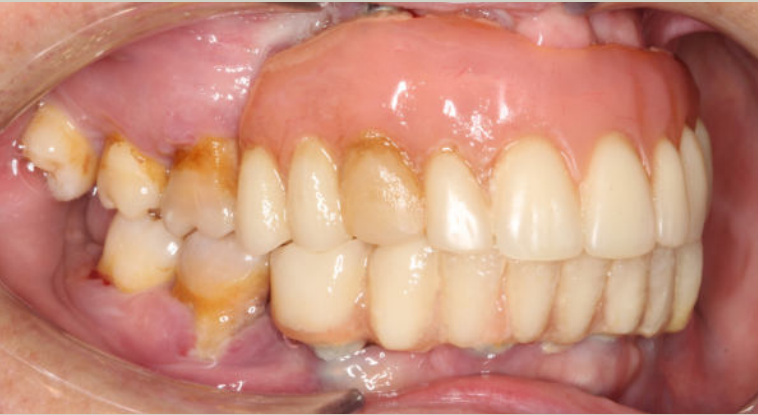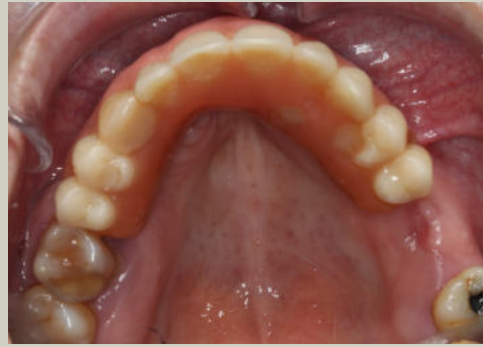- **Medicación:** No.
- **No alergias.**

Diagnóstico: Explantación de implantes superiores e inferiores junto con exodoncia de piezas remanentes + rehabilitación superior con implantes cigomáticos e inferior con implantes convencionales.

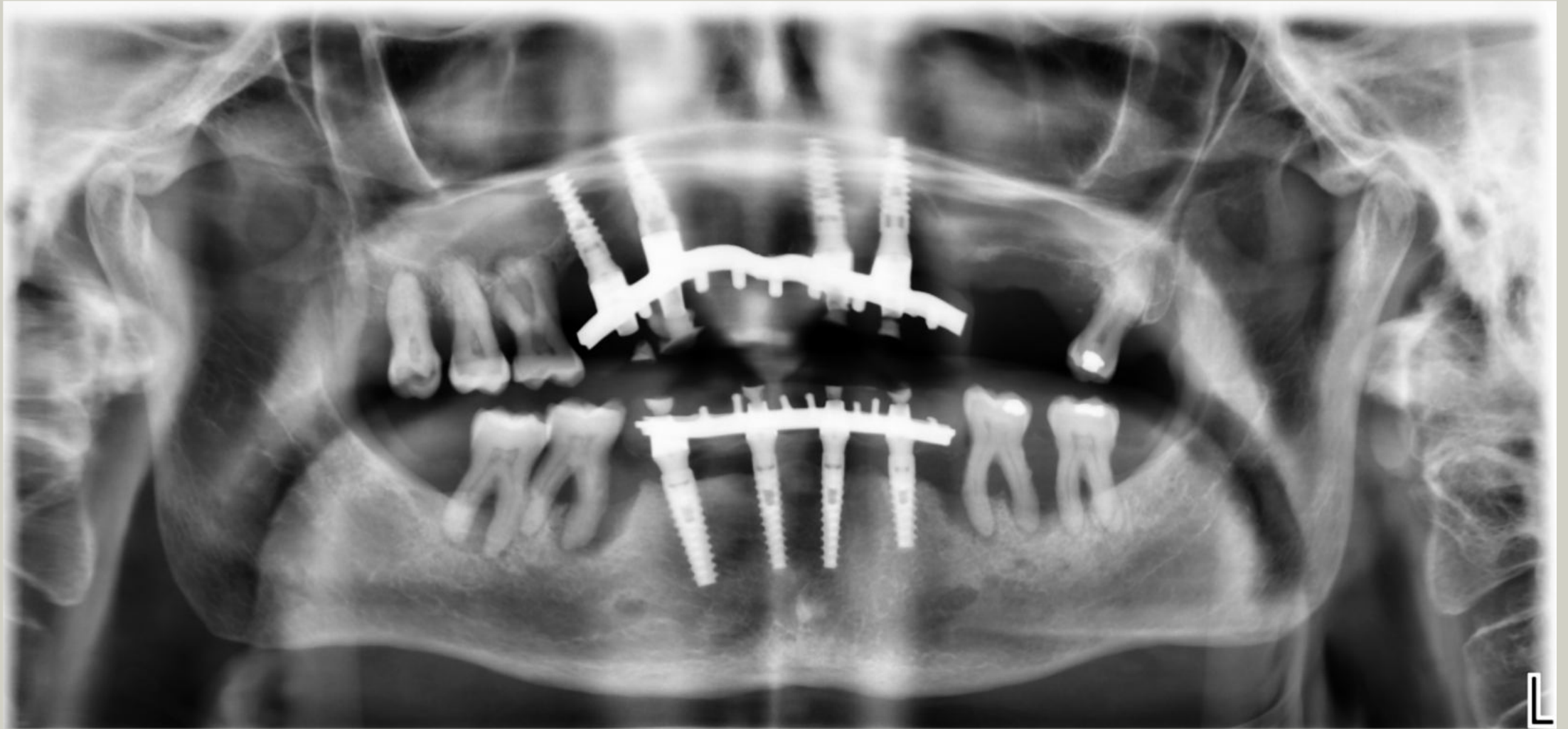




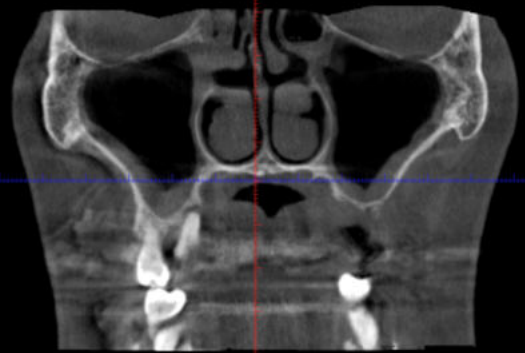




8/3/22



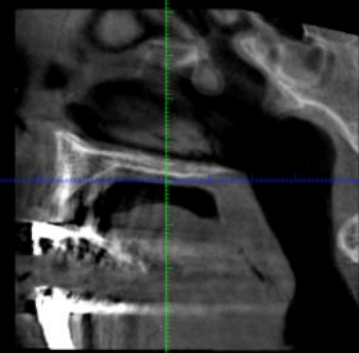
Coronal(Y)



R

L

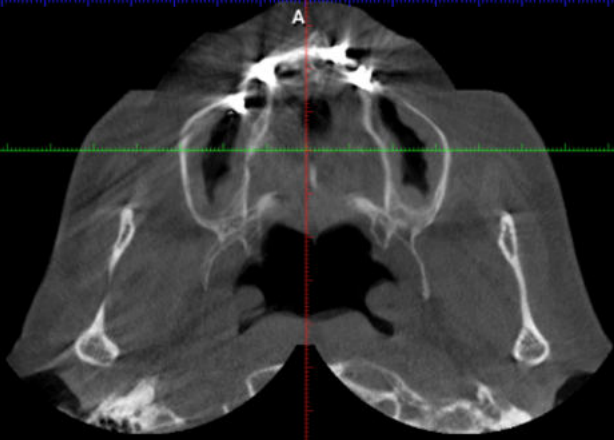
Sagittal(X)



A

P

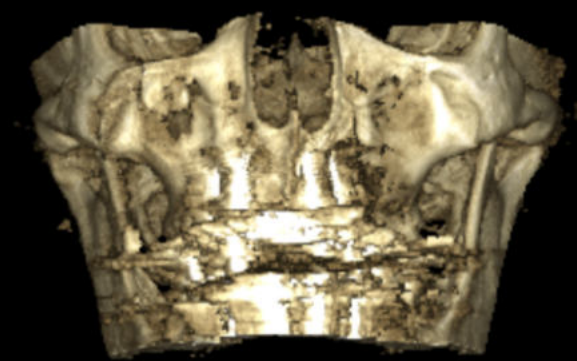
Axial(Z)

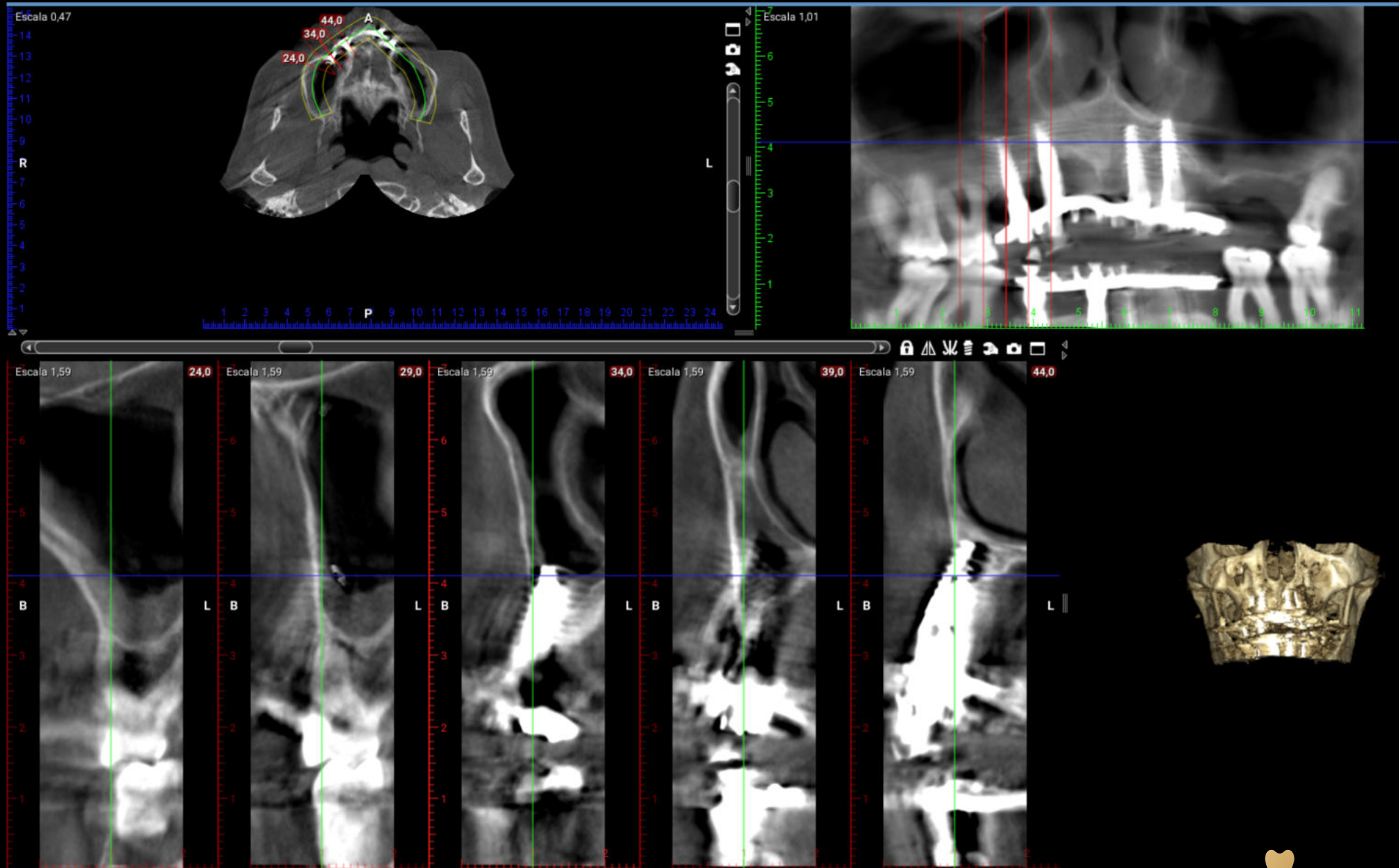


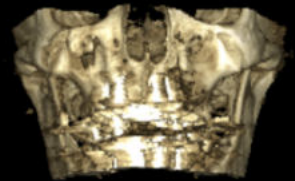
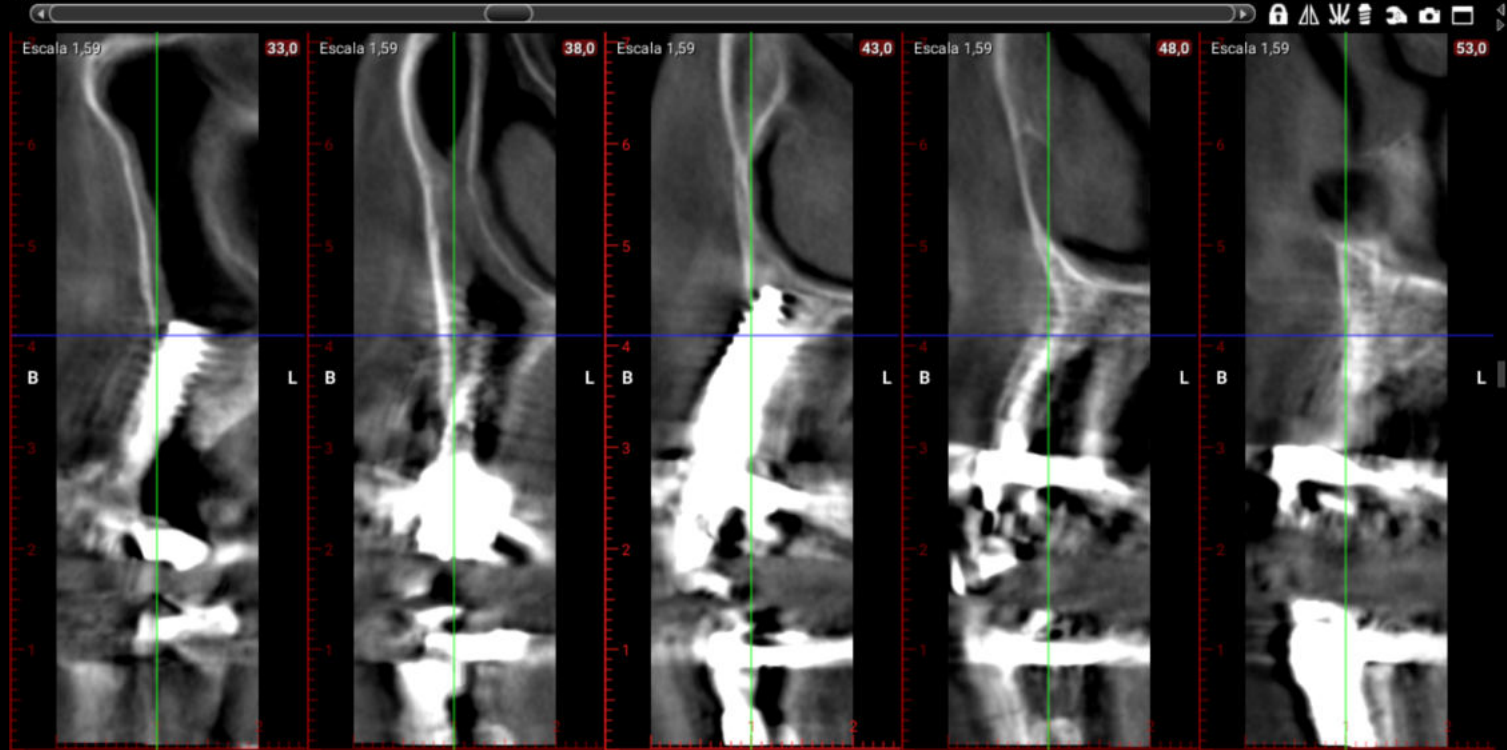
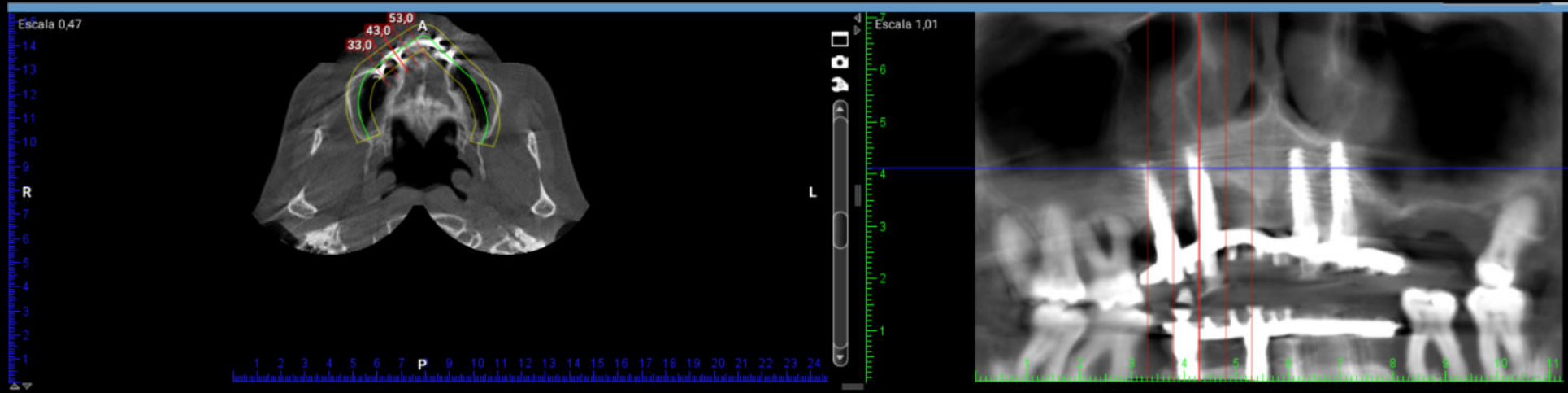
R

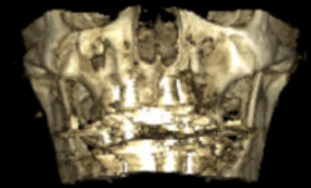
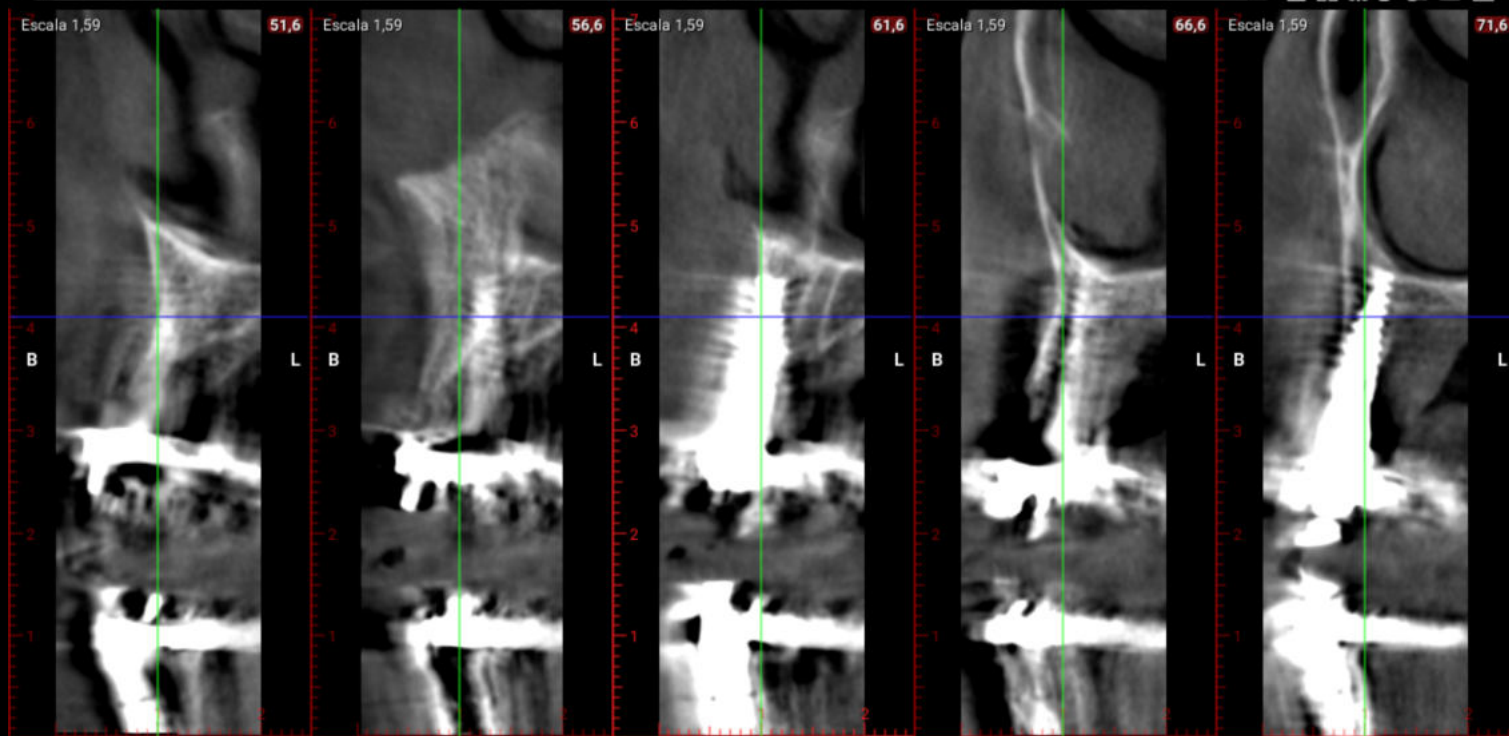
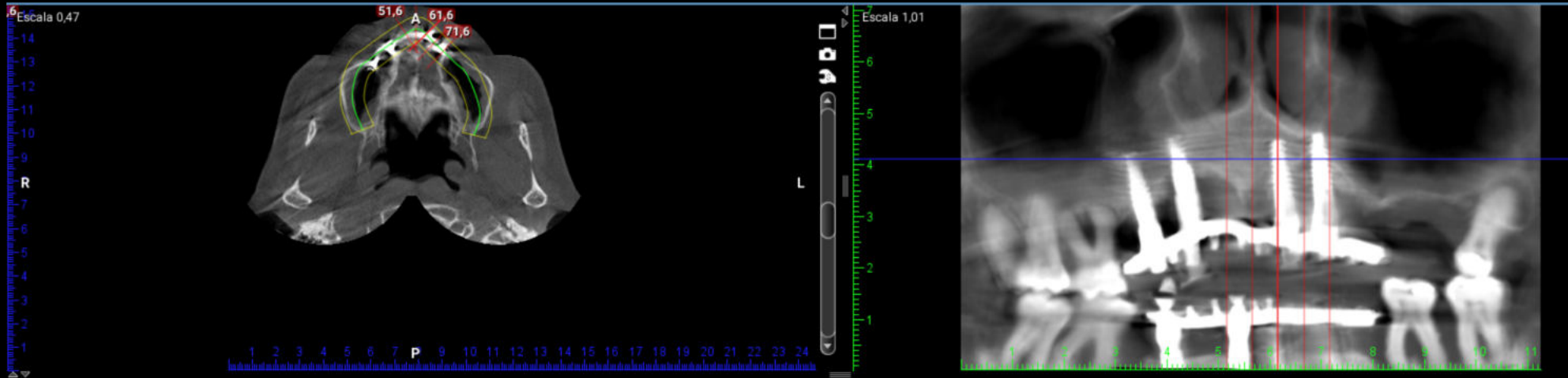
L

P





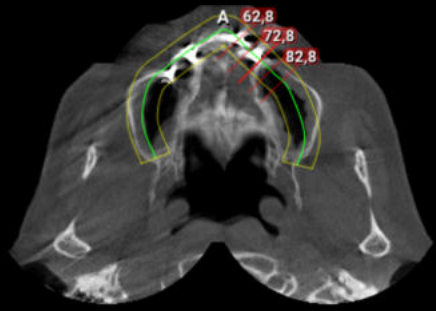




Escala 0,47

14
13
12
11
10
9
8
7
6
5
4
3
2
1

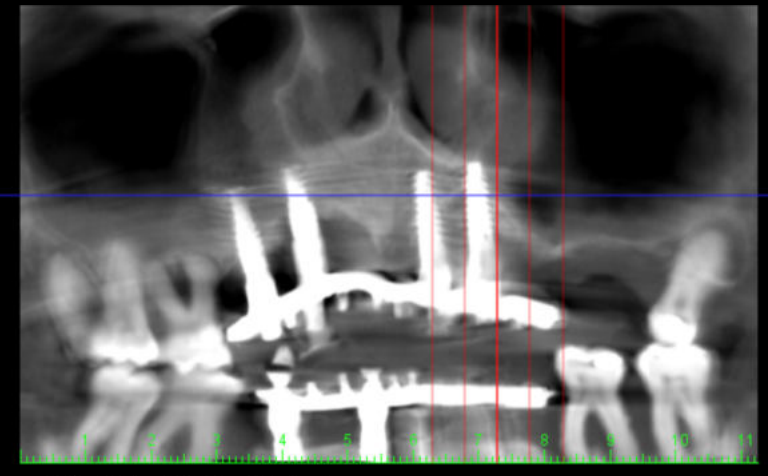
R



L

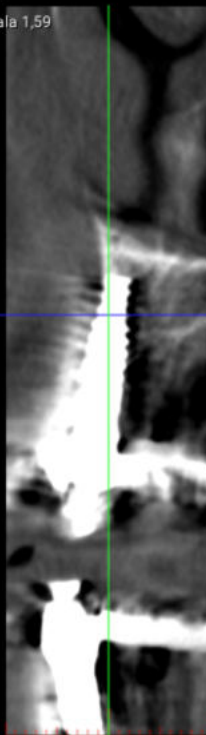
Escala 1,01

6
5
4
3
2
1



Escala 1,59

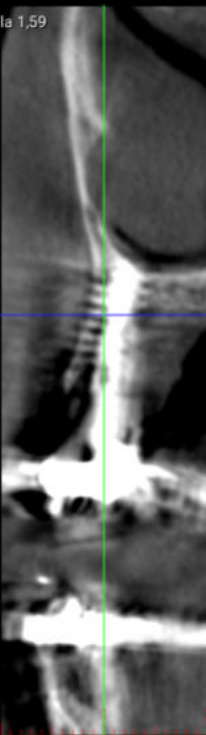
6
5
4
3
2
1



62,8

Escala 1,59

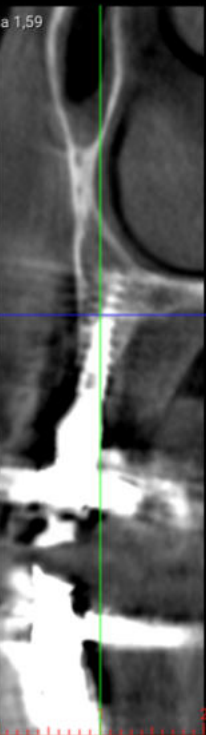
6
5
4
3
2
1



67,8

Escala 1,59

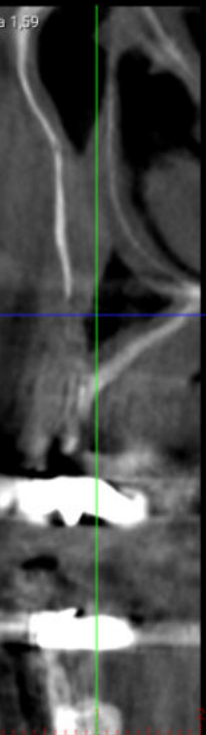
6
5
4
3
2
1



72,8

Escala 1,59

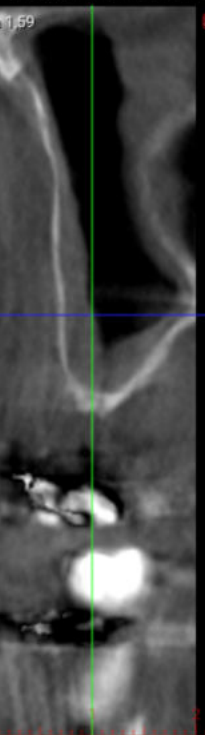
6
5
4
3
2
1



77,8

Escala 1,59

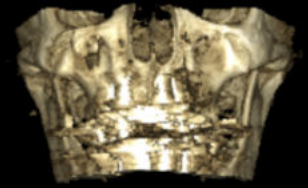
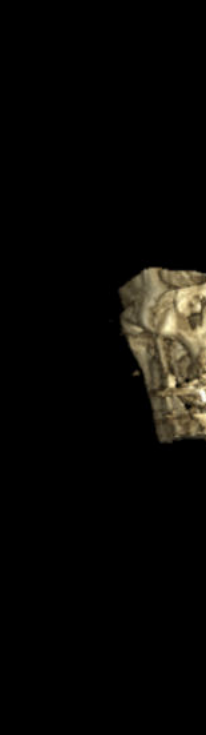
6
5
4
3
2
1

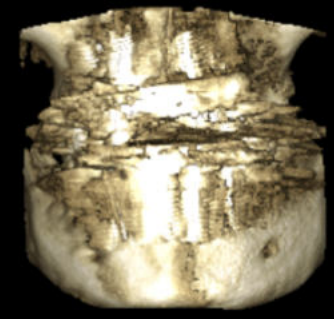
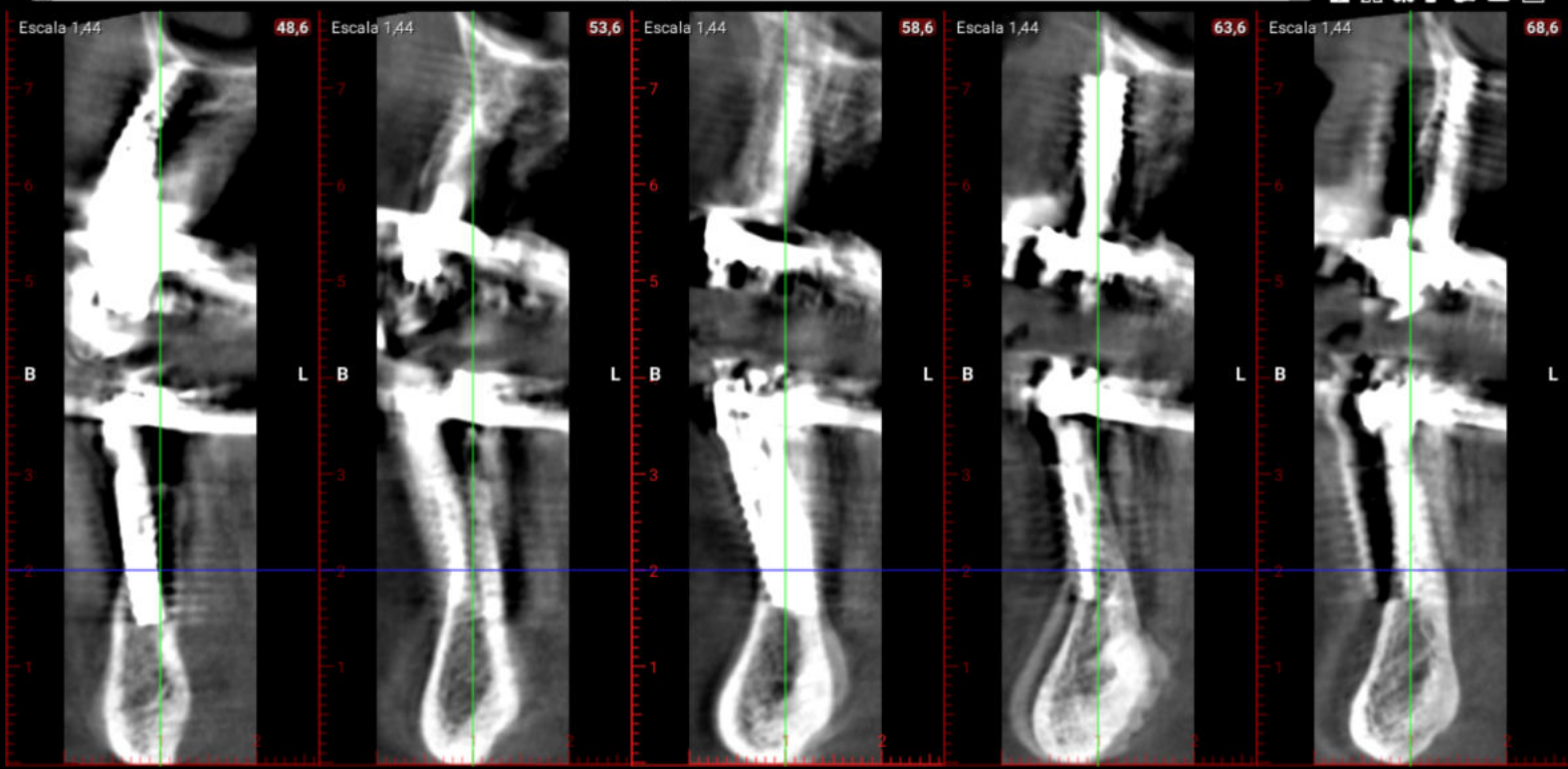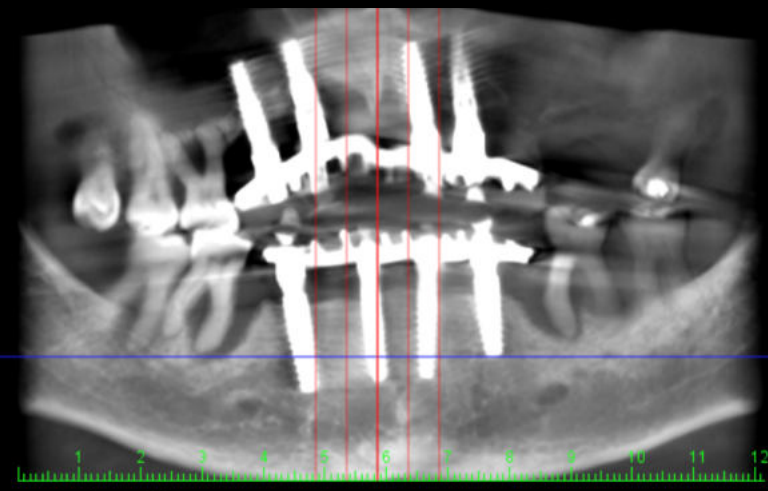
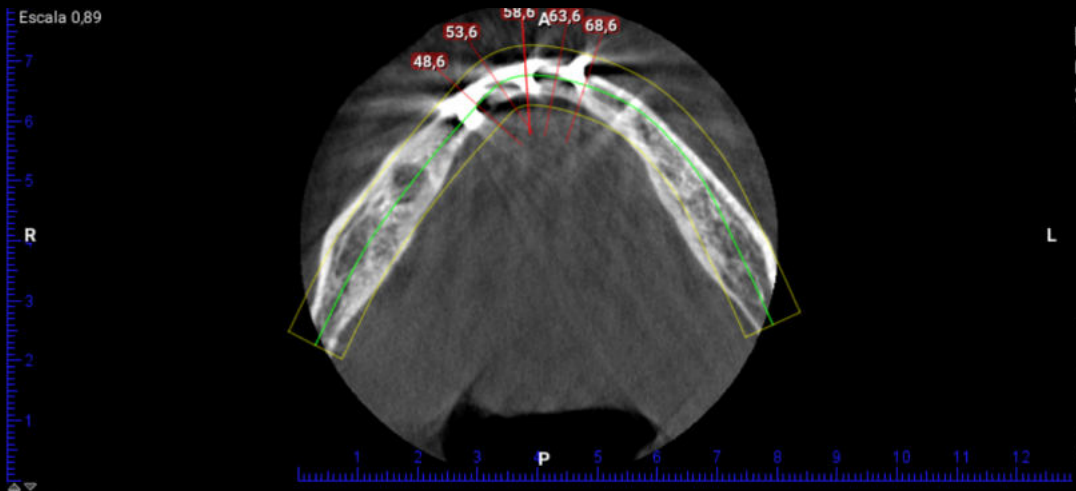


82,8

Escala 1,59

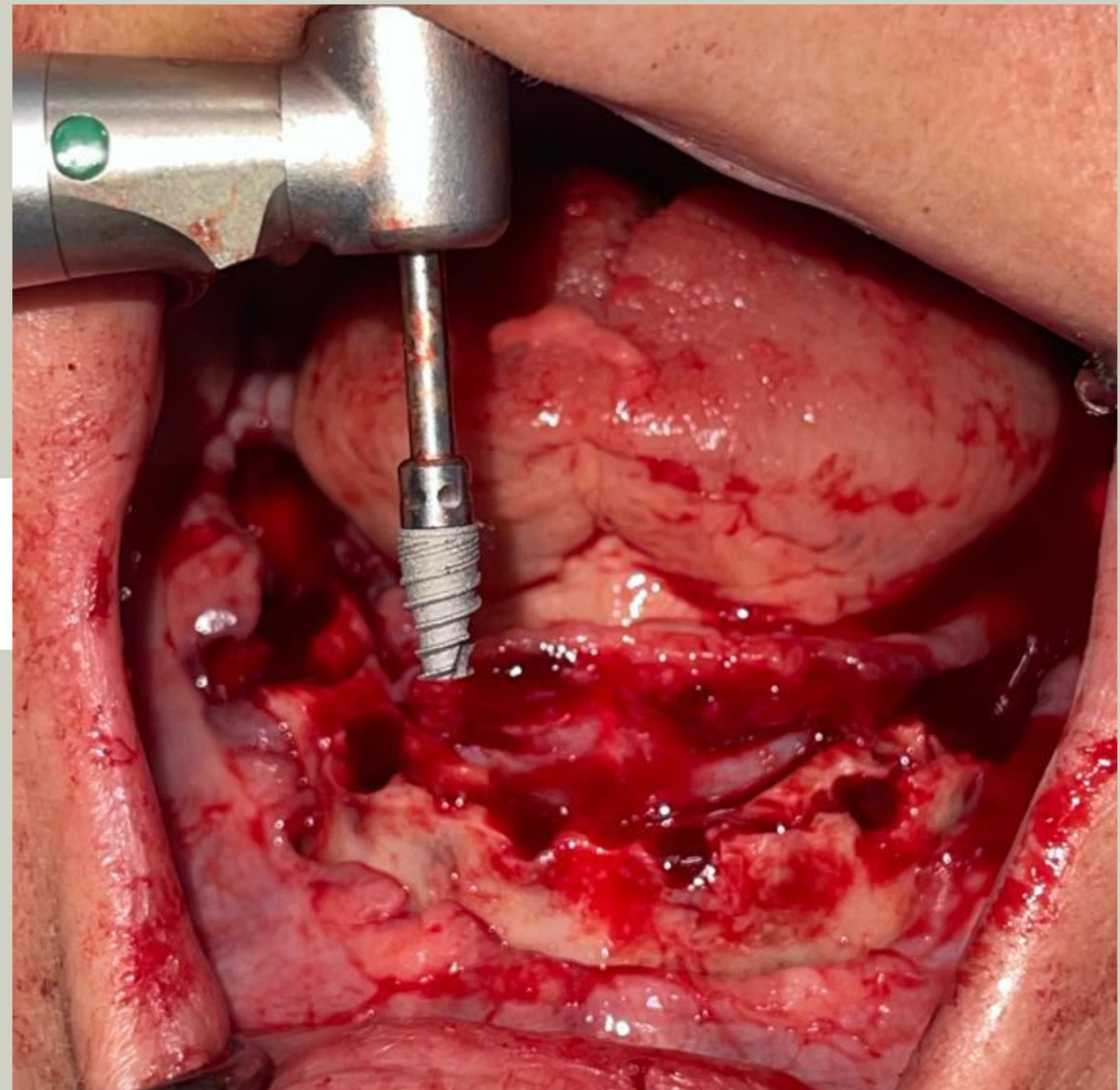
6
5
4
3
2
1





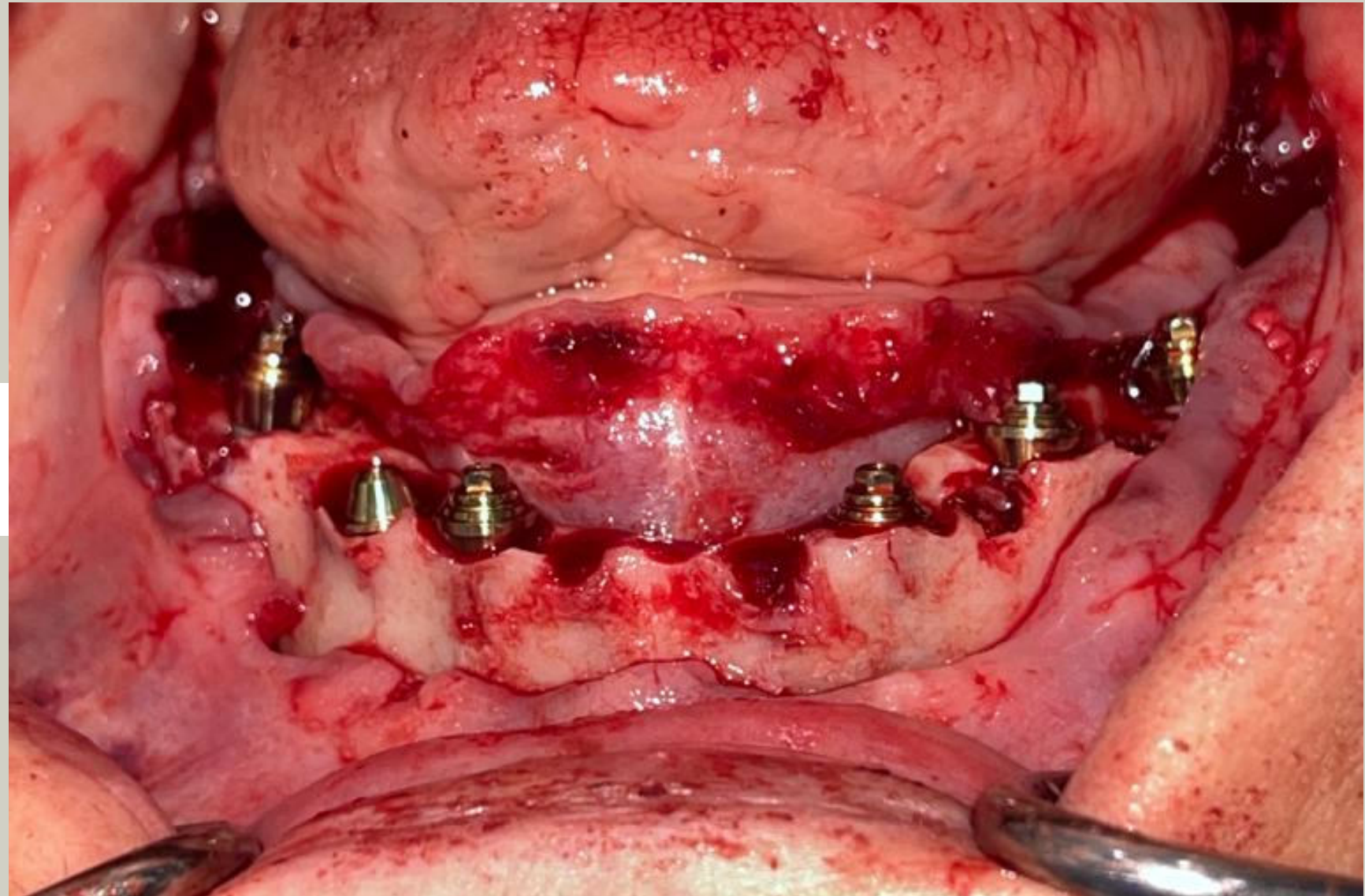
Cirugía

Colocación de
implantes inferiores
tras la explantación



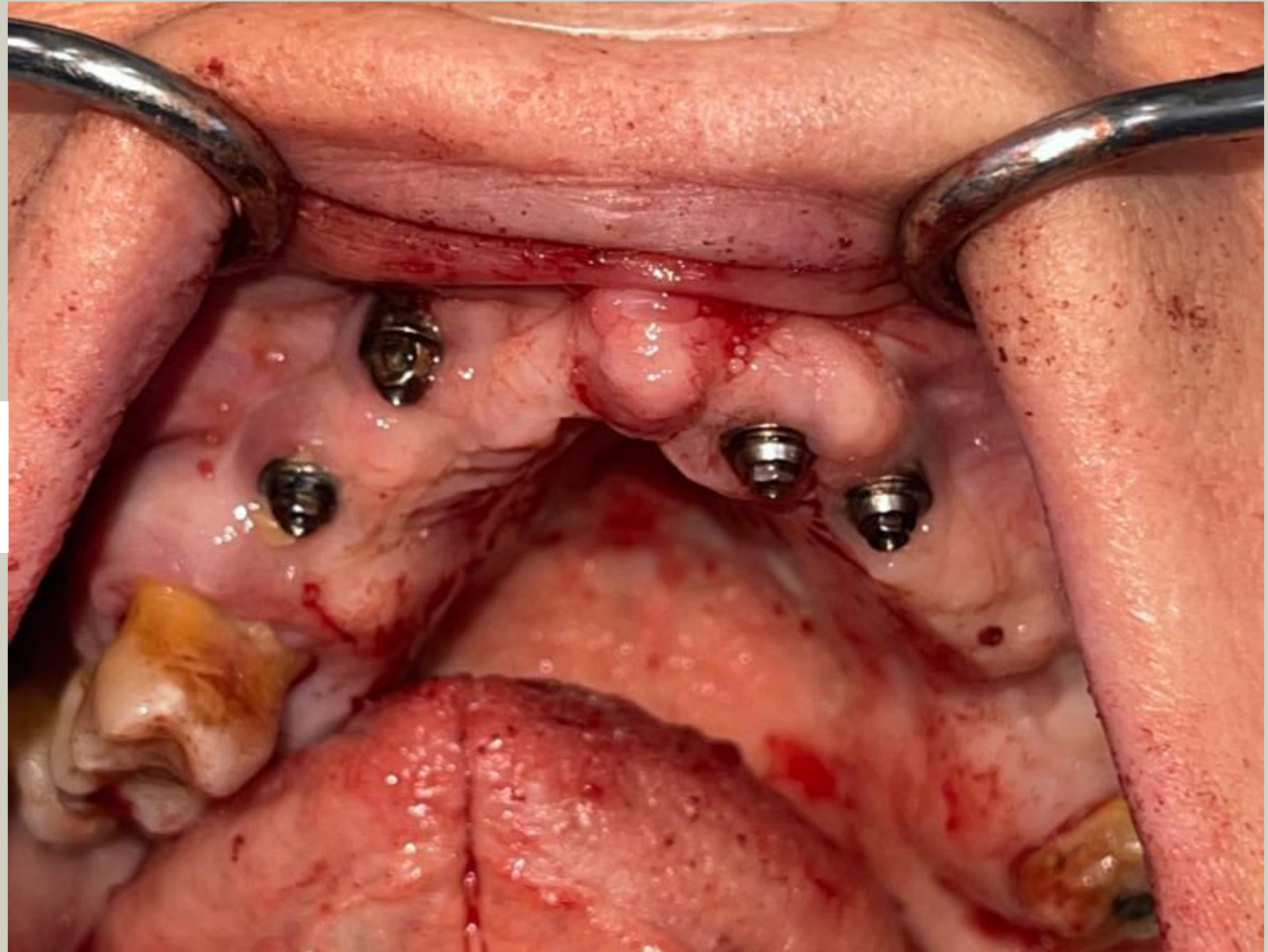
Cirugia

One
abutment-
One time

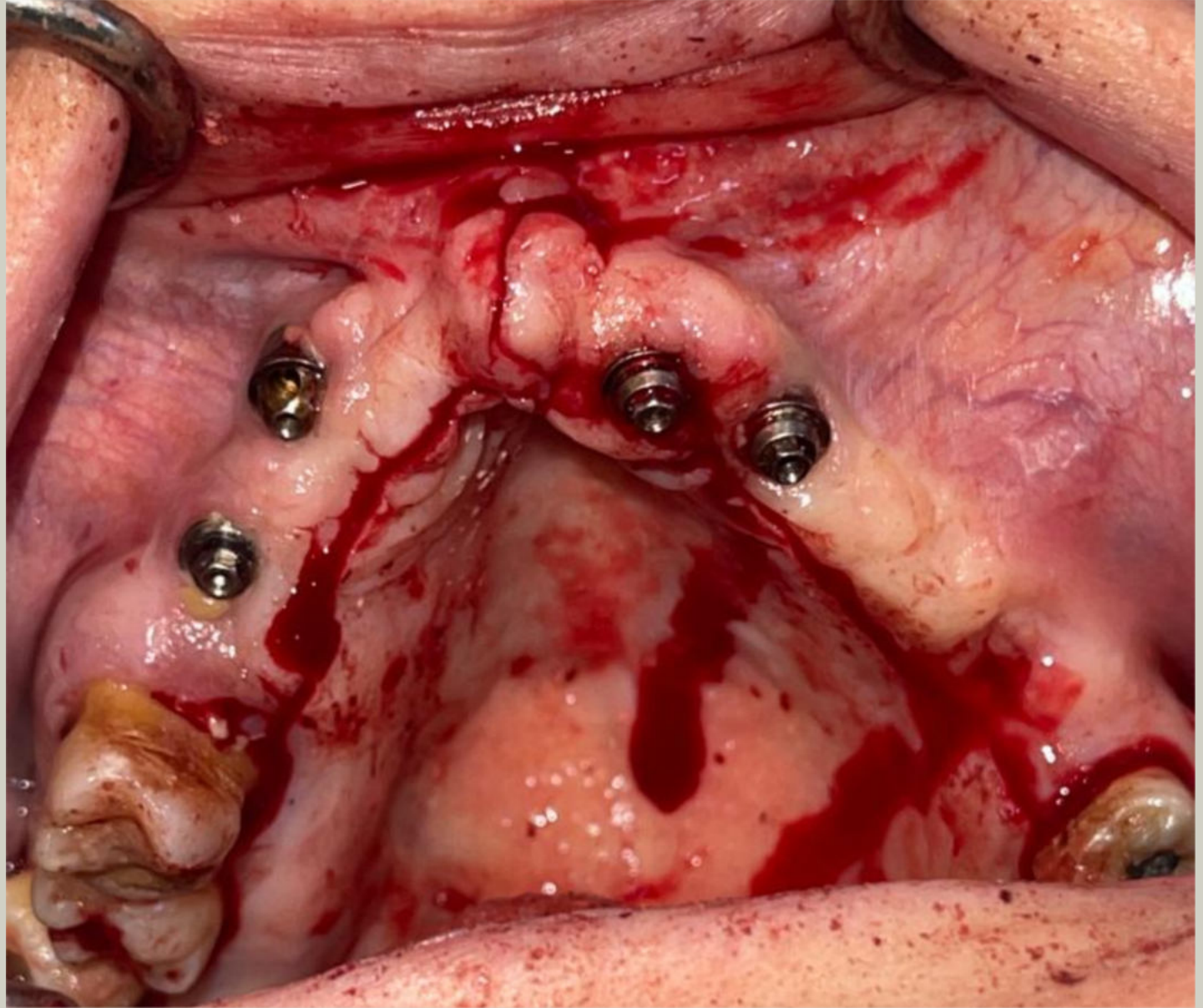


Cirugía

Arcada superior tras
desatornillar la
prótesis

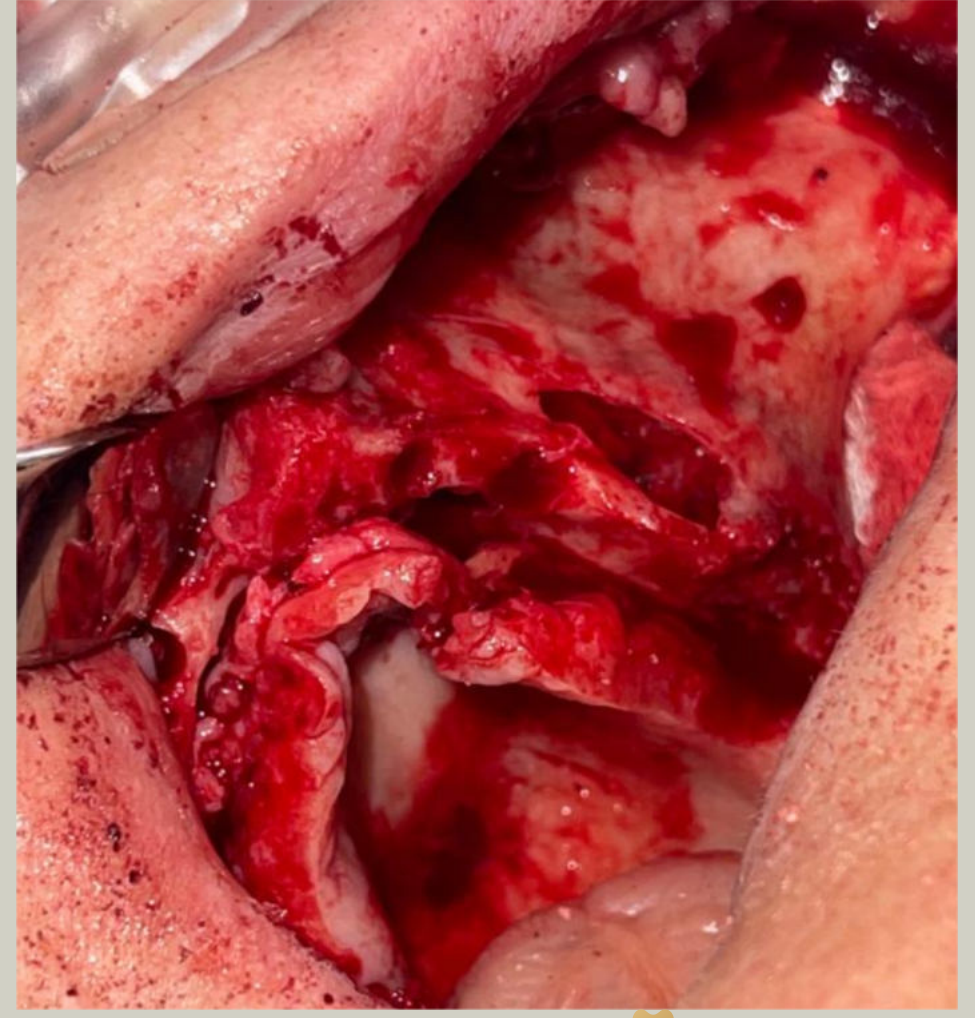
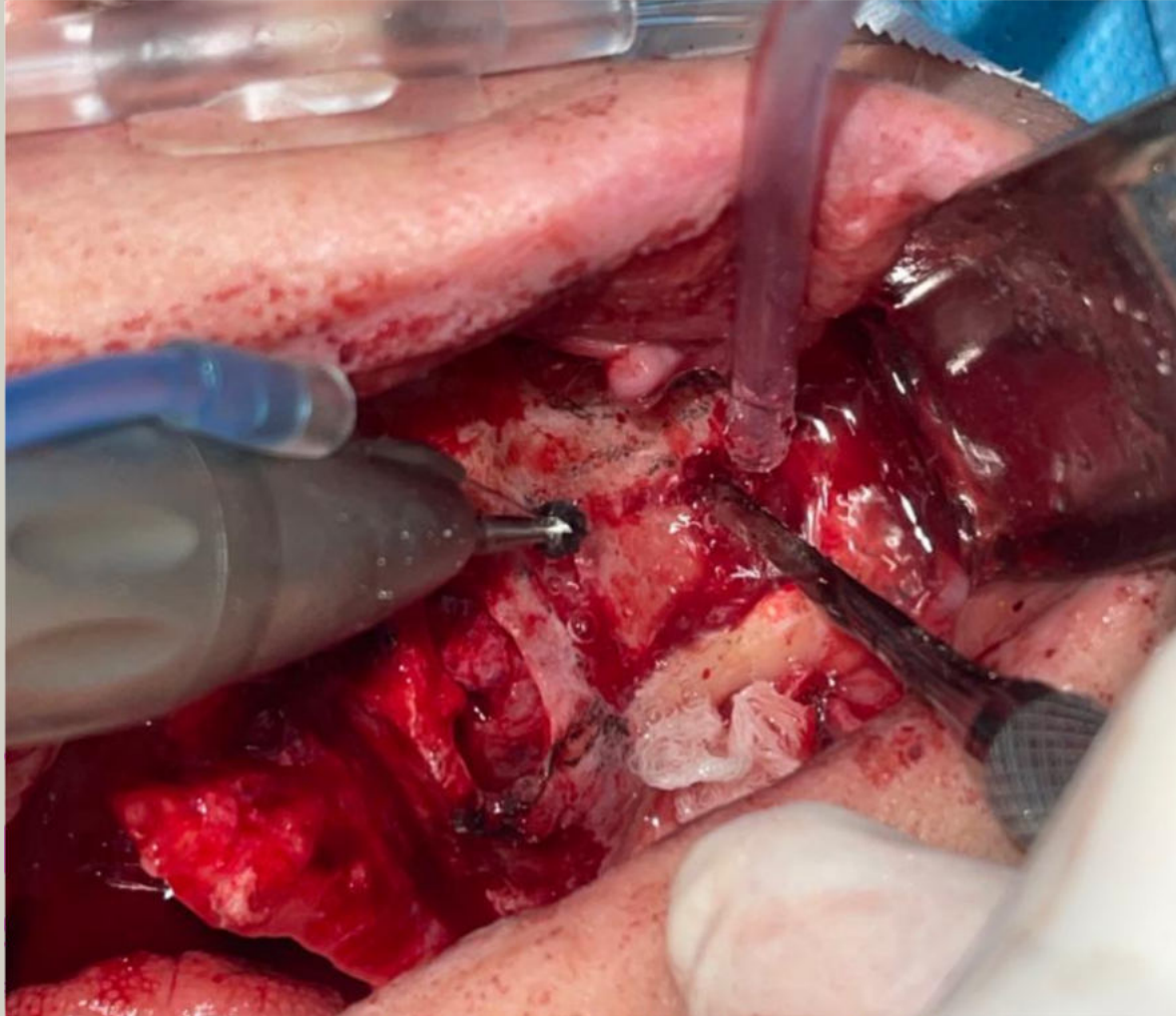


Cirugía



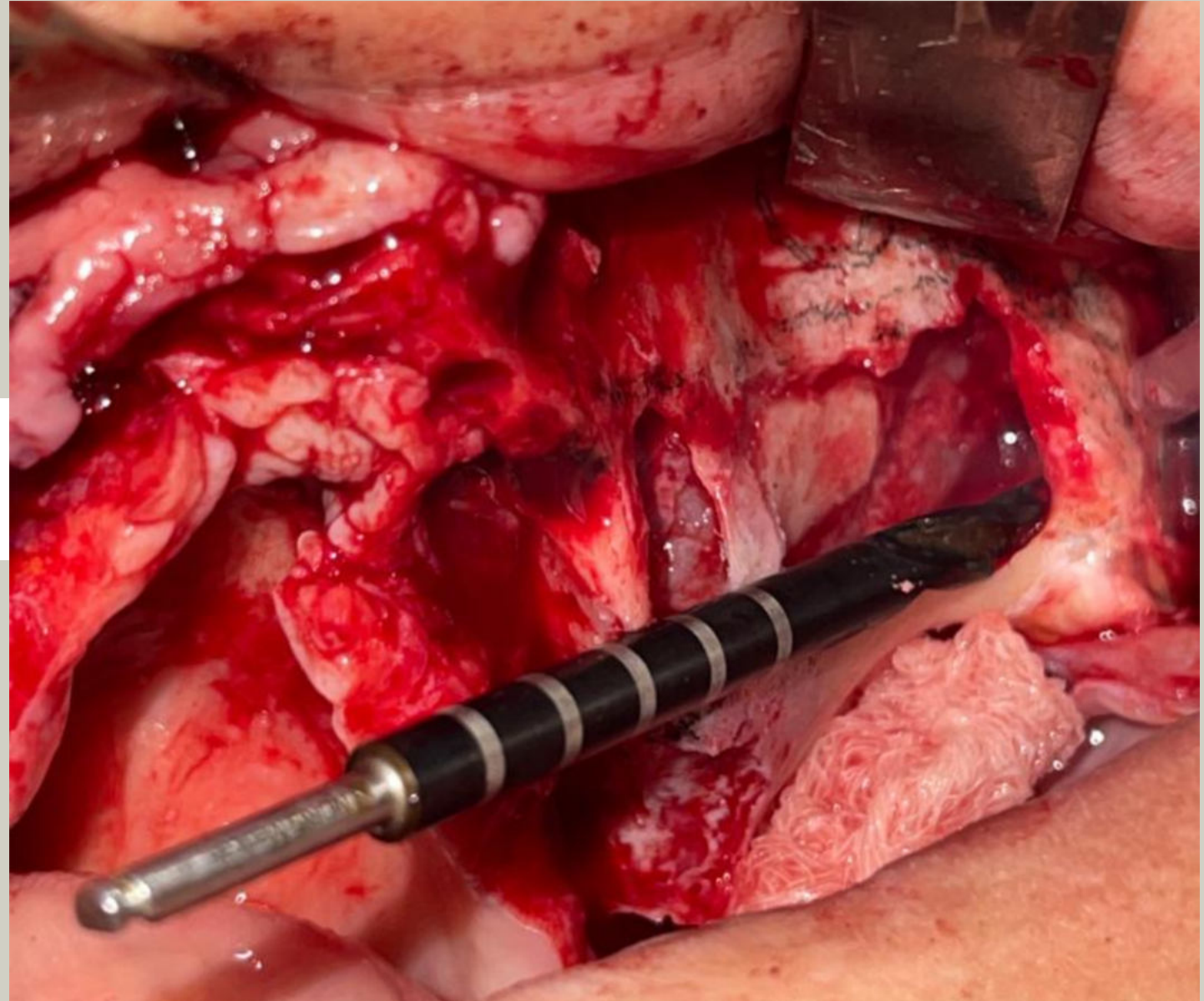
Cirugía

Tras explantar los implantes con periimplantitis se procede a la colocación de los implantes cigomáticos del segundo cuadrante



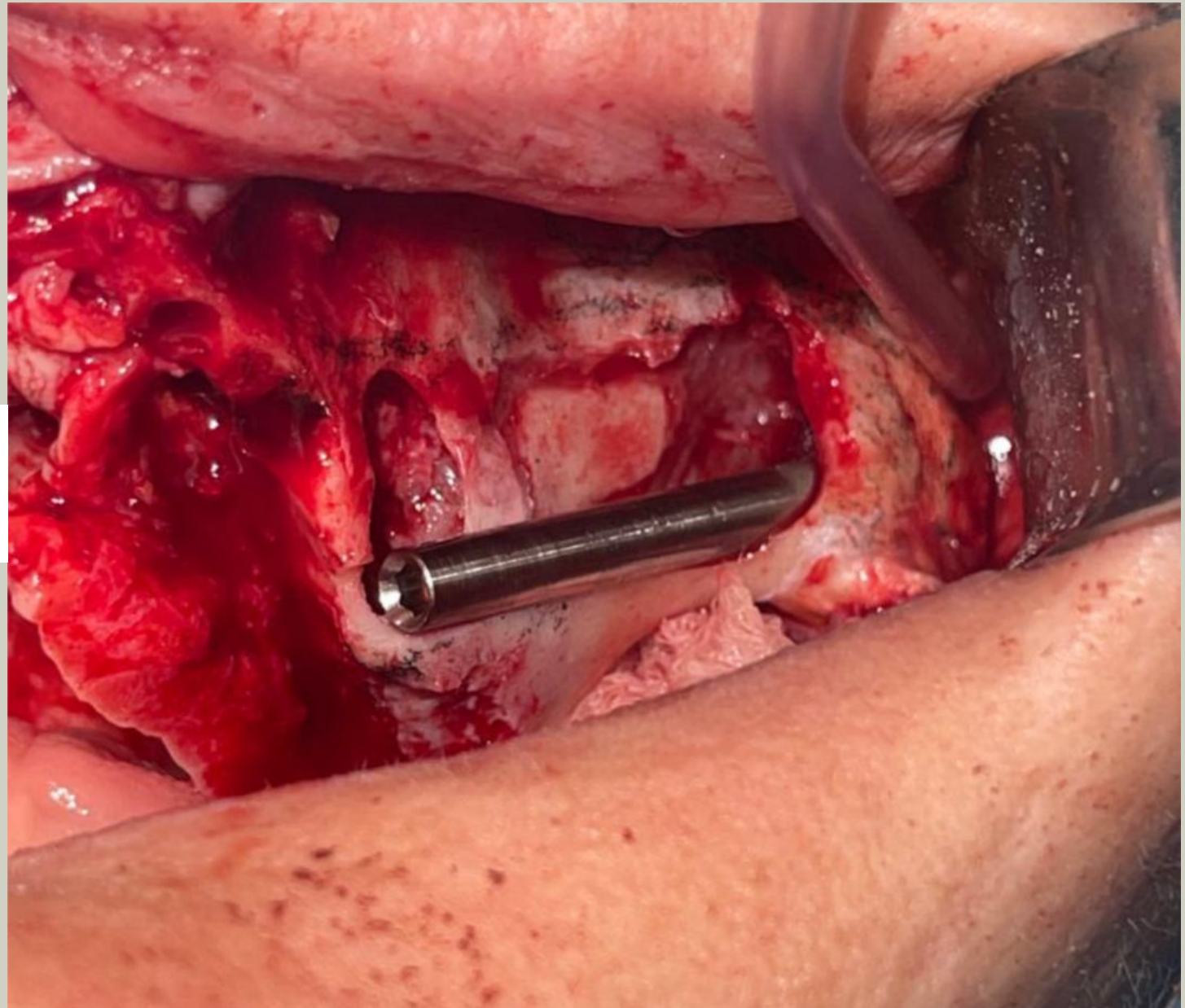
Cirugía

Secuencia de fresado
para implantes
cigomáticos Noris



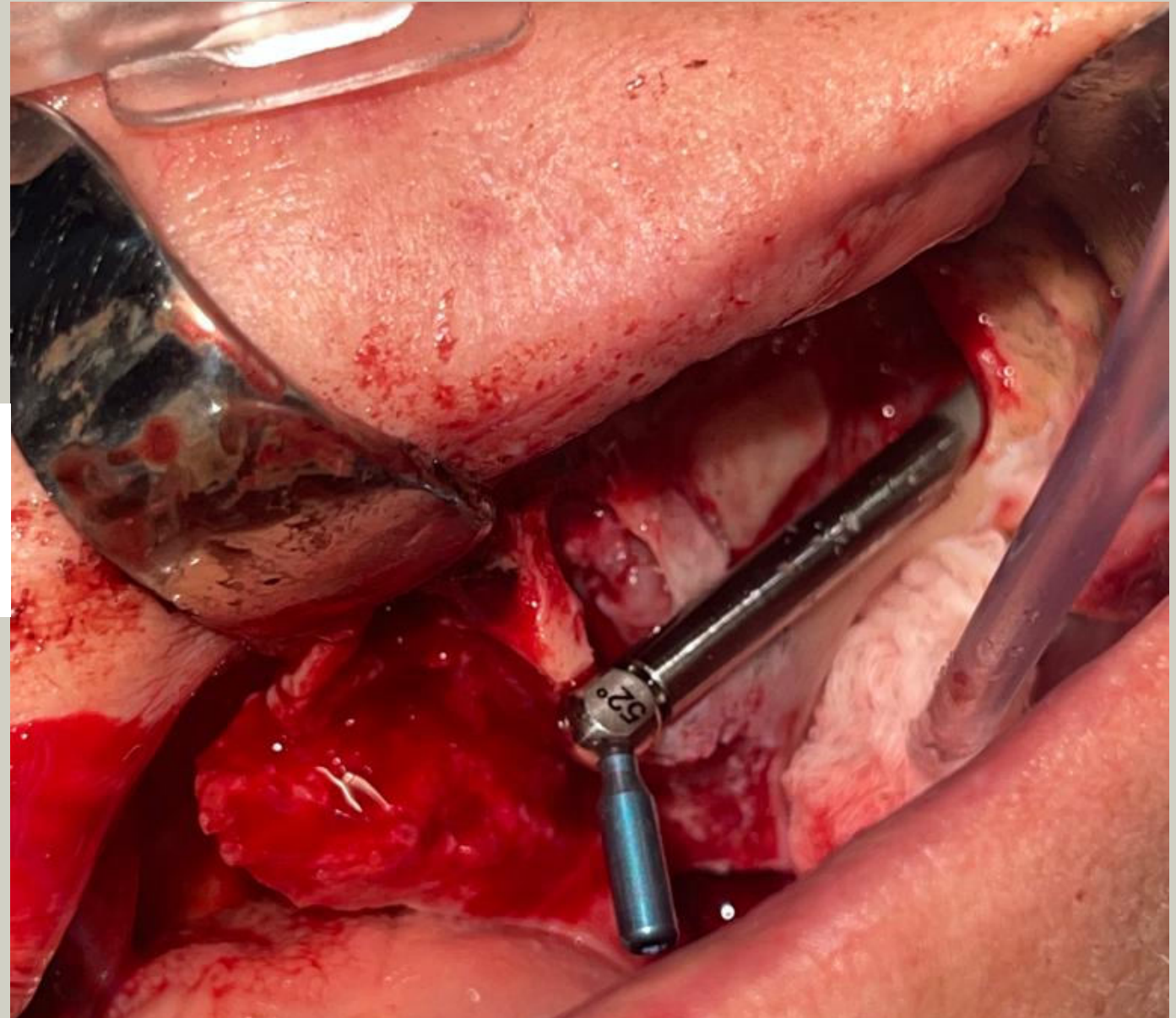
Cirugía

Colocación del
primer implante
cigomático



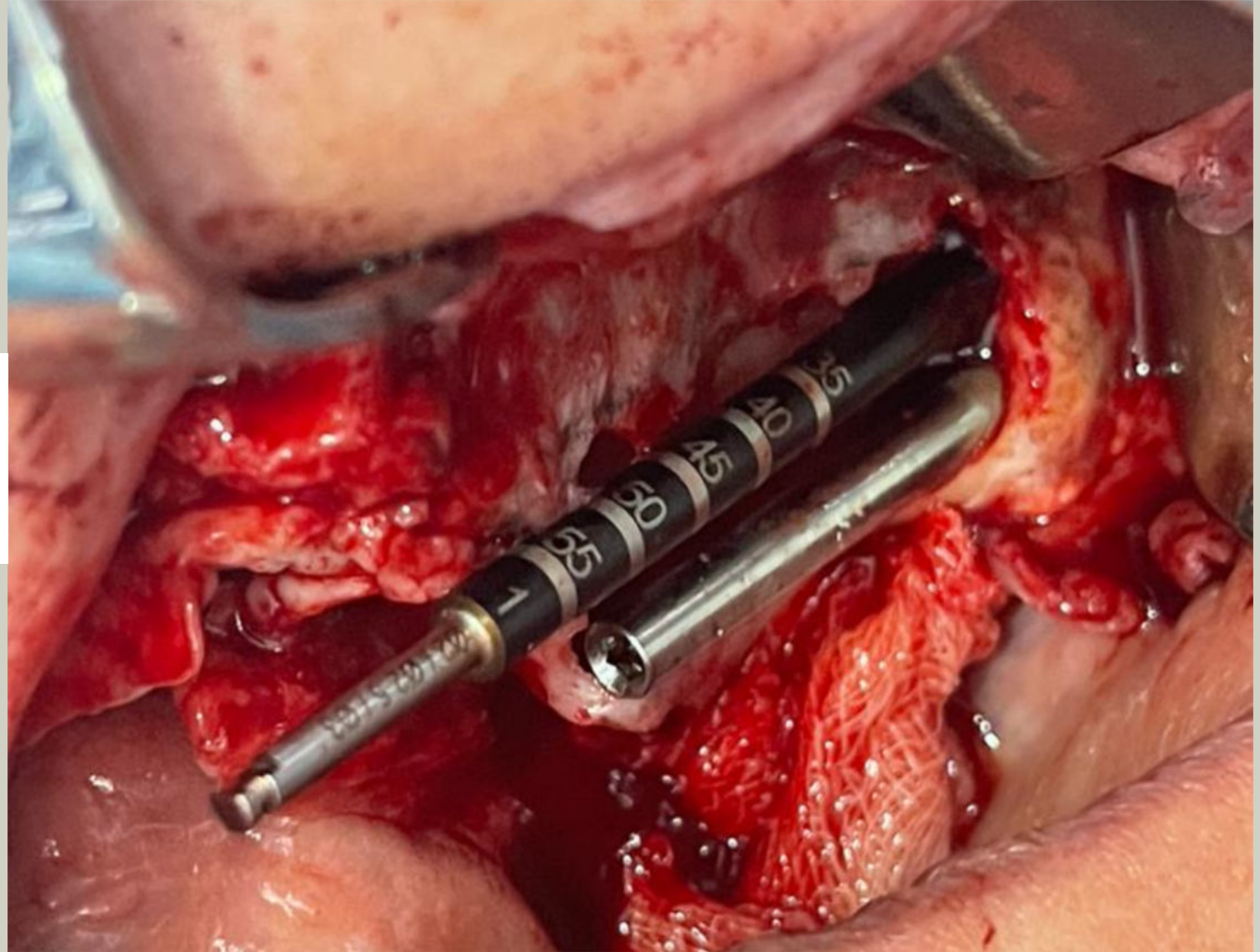
Cirugía

Selección del
pilar en función
de la
emergencia.



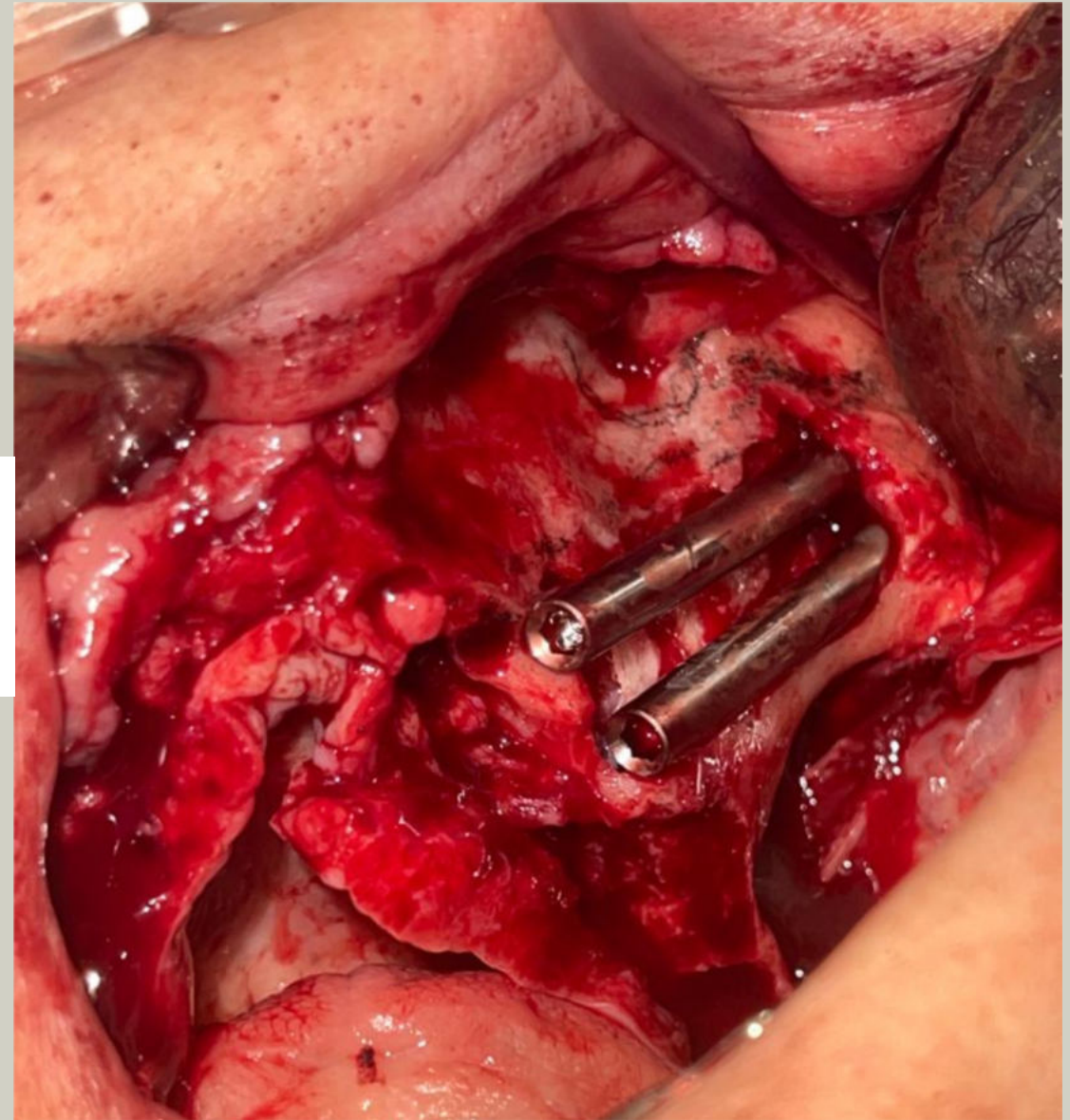
Cirugía

Fresado para el
segundo
implante
cigomático



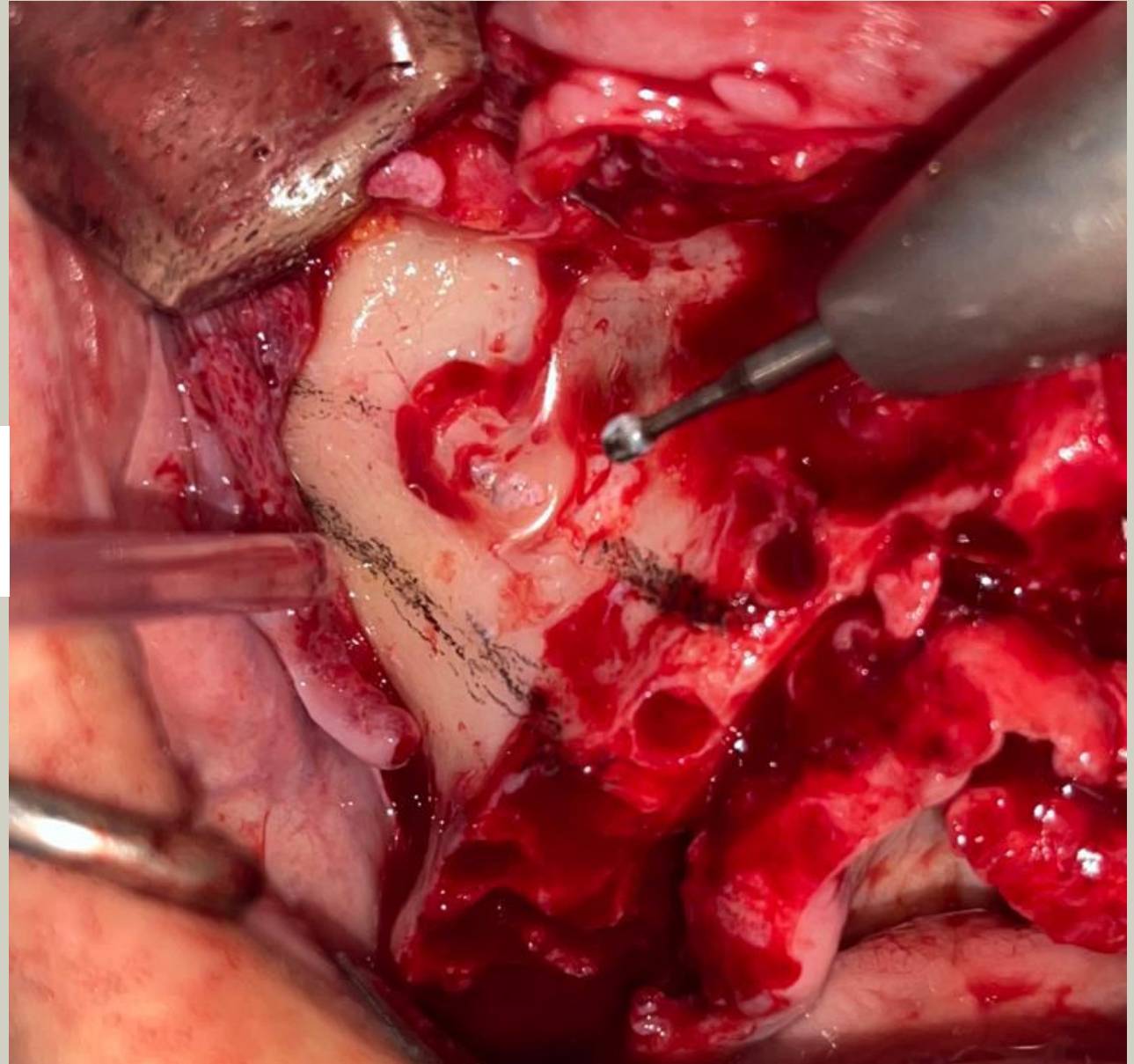
Cirugía

Colocación del
segundo
implante
cigomático



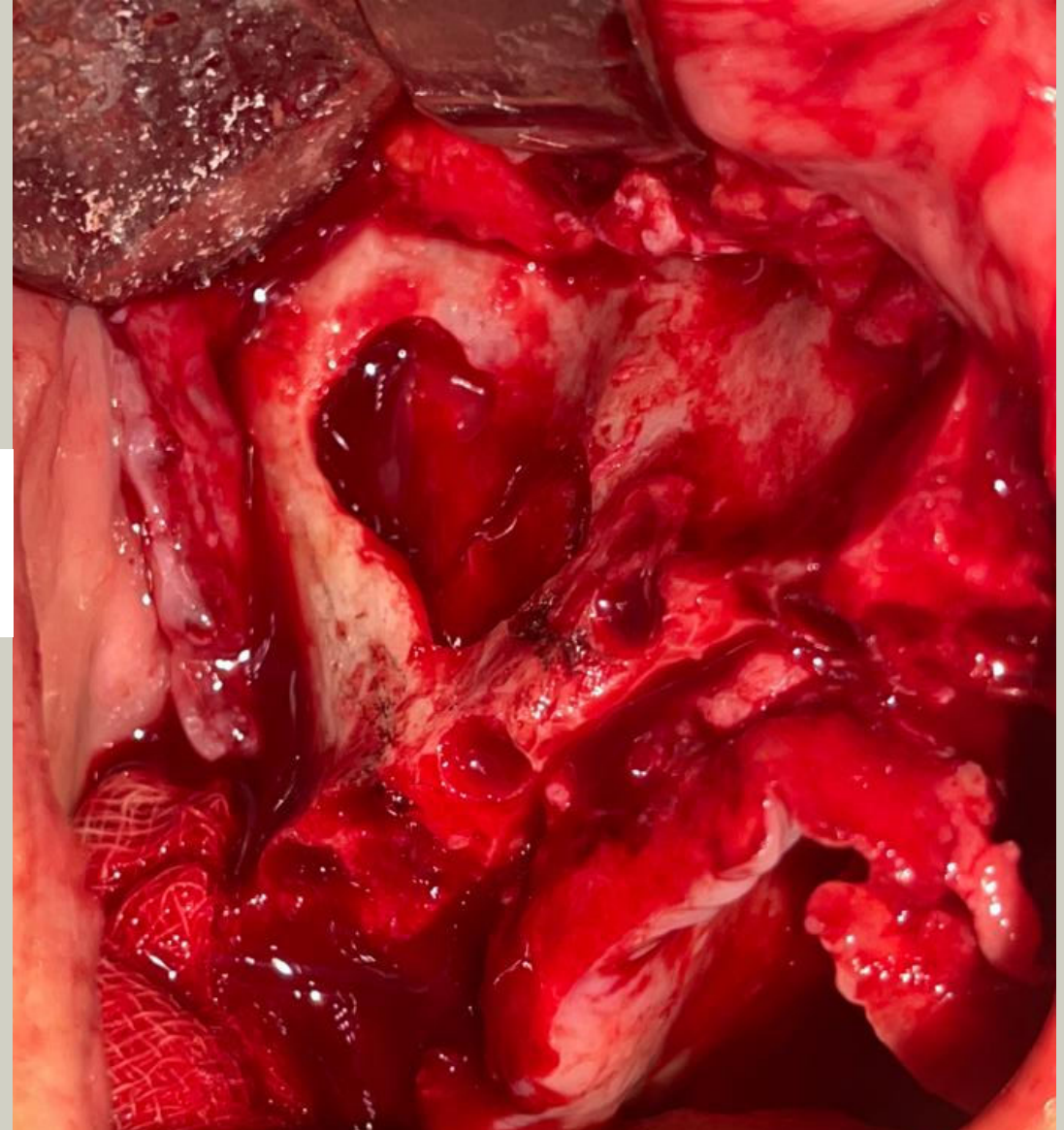
Cirugía

Primer
cuadrante.
Acceso.



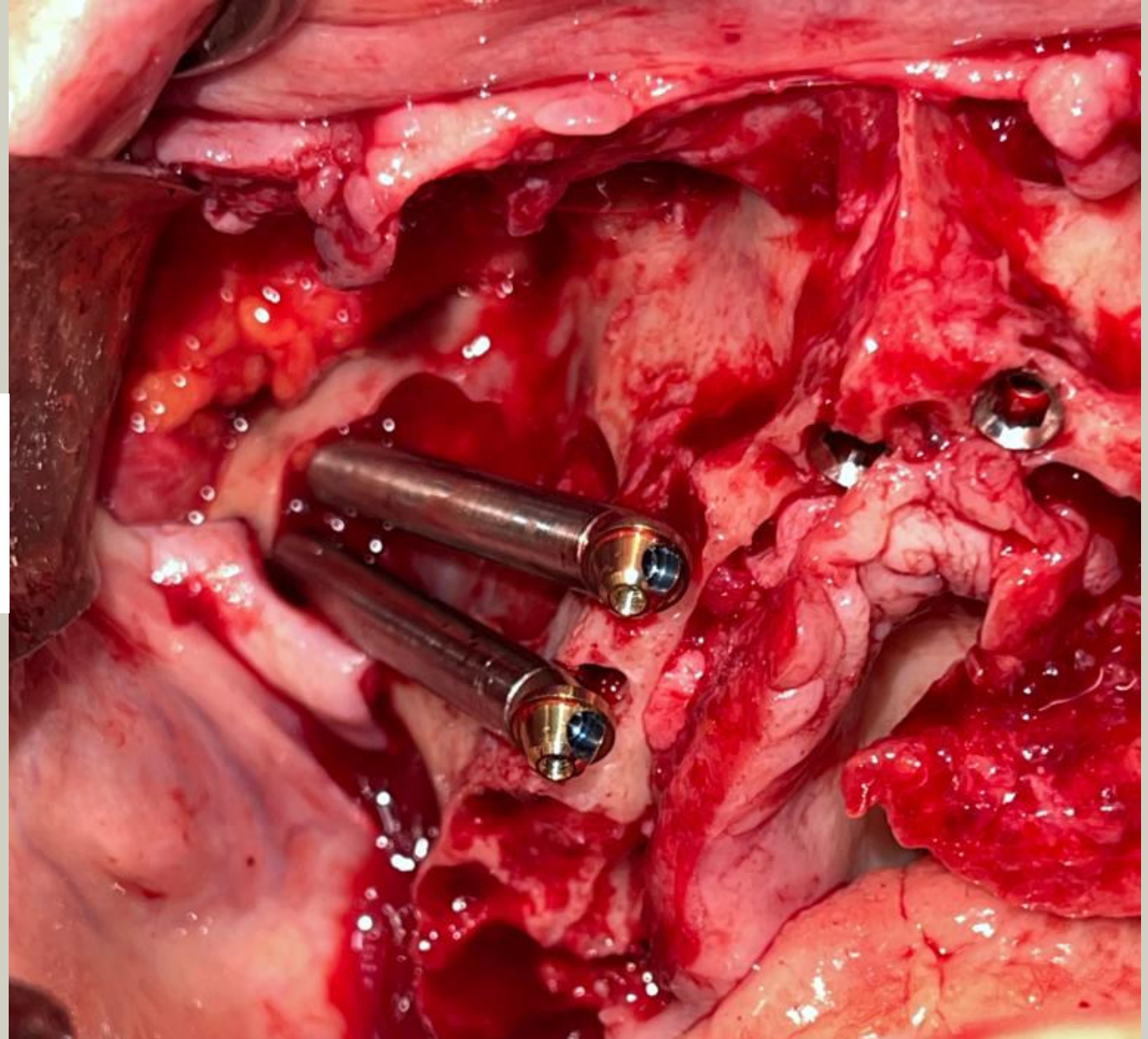
Cirugía

Ventana donde
podemos observar
el seno maxilar



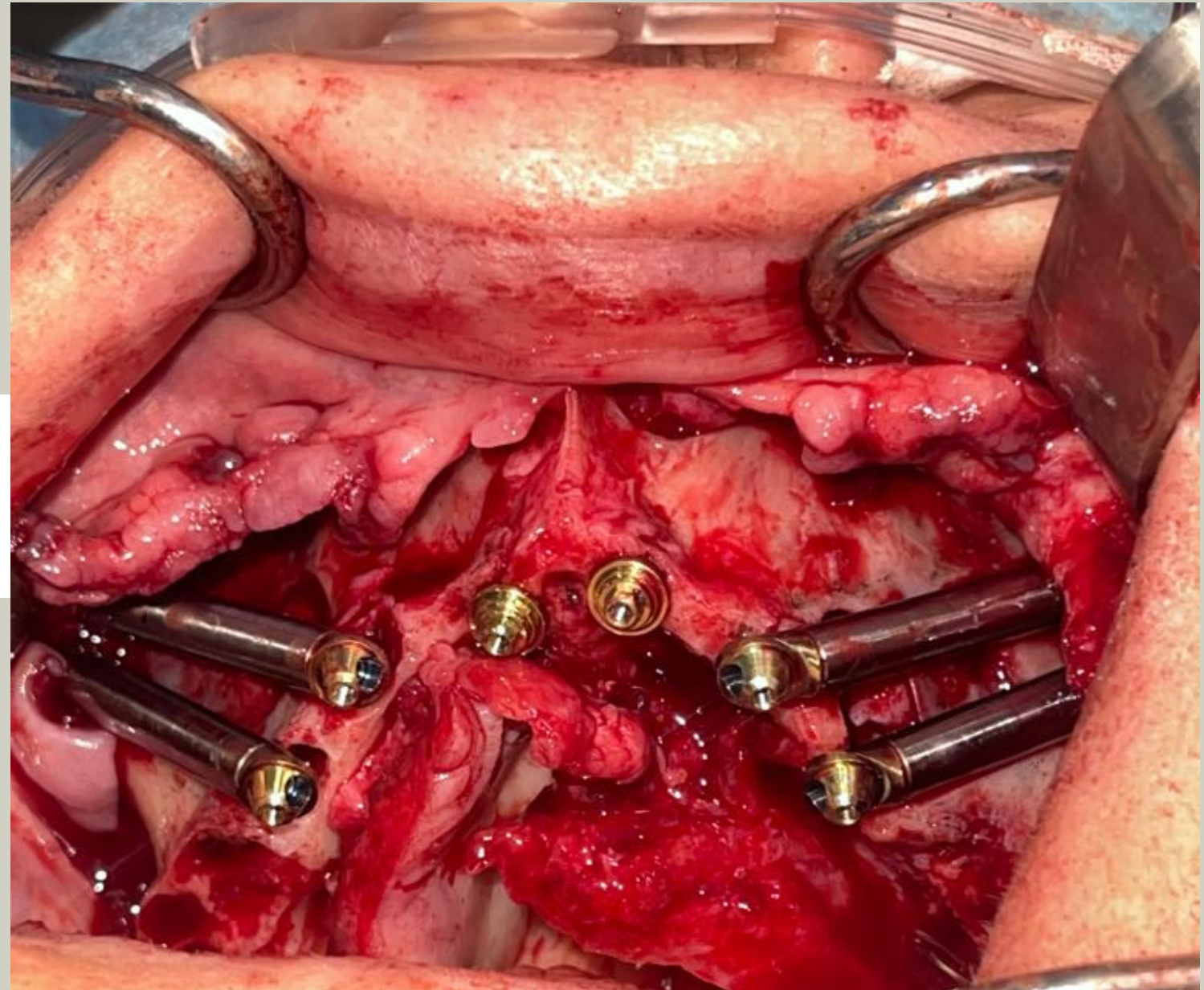
Cirugía

Colocación de los
dos implantes
cigomáticos y sus
pilares angulados

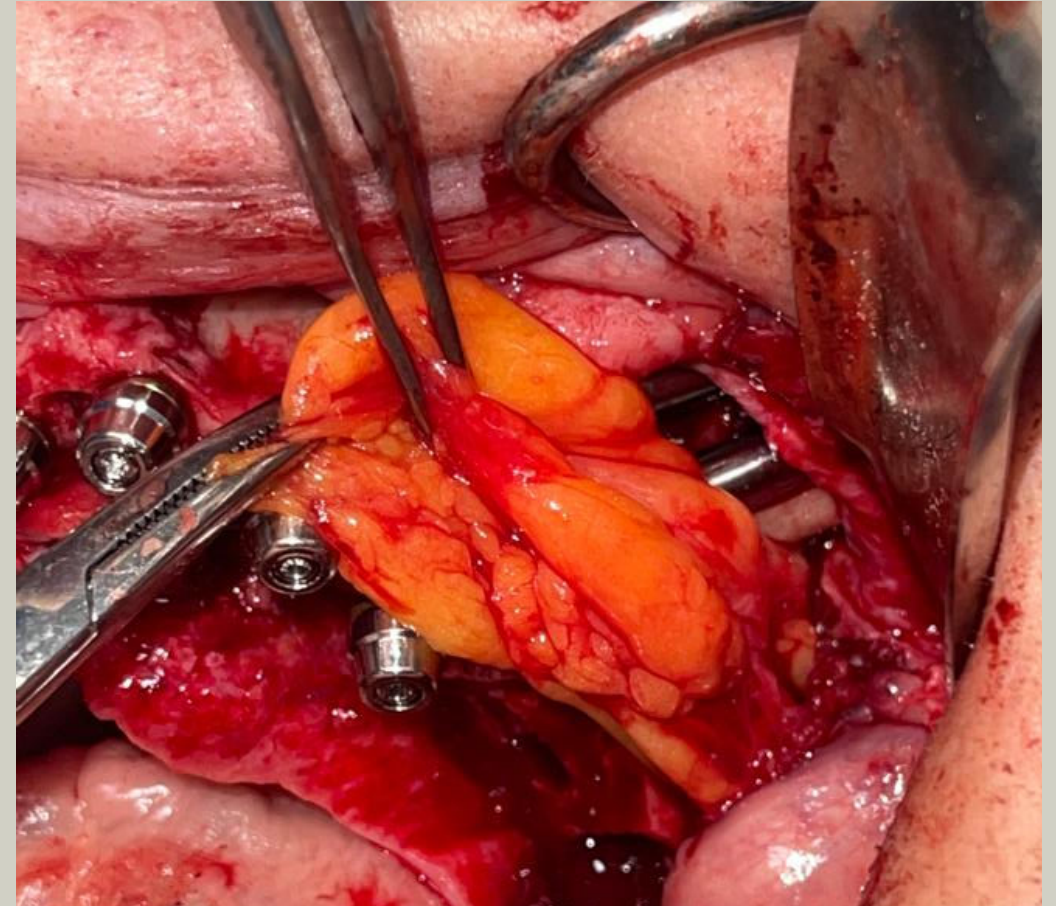
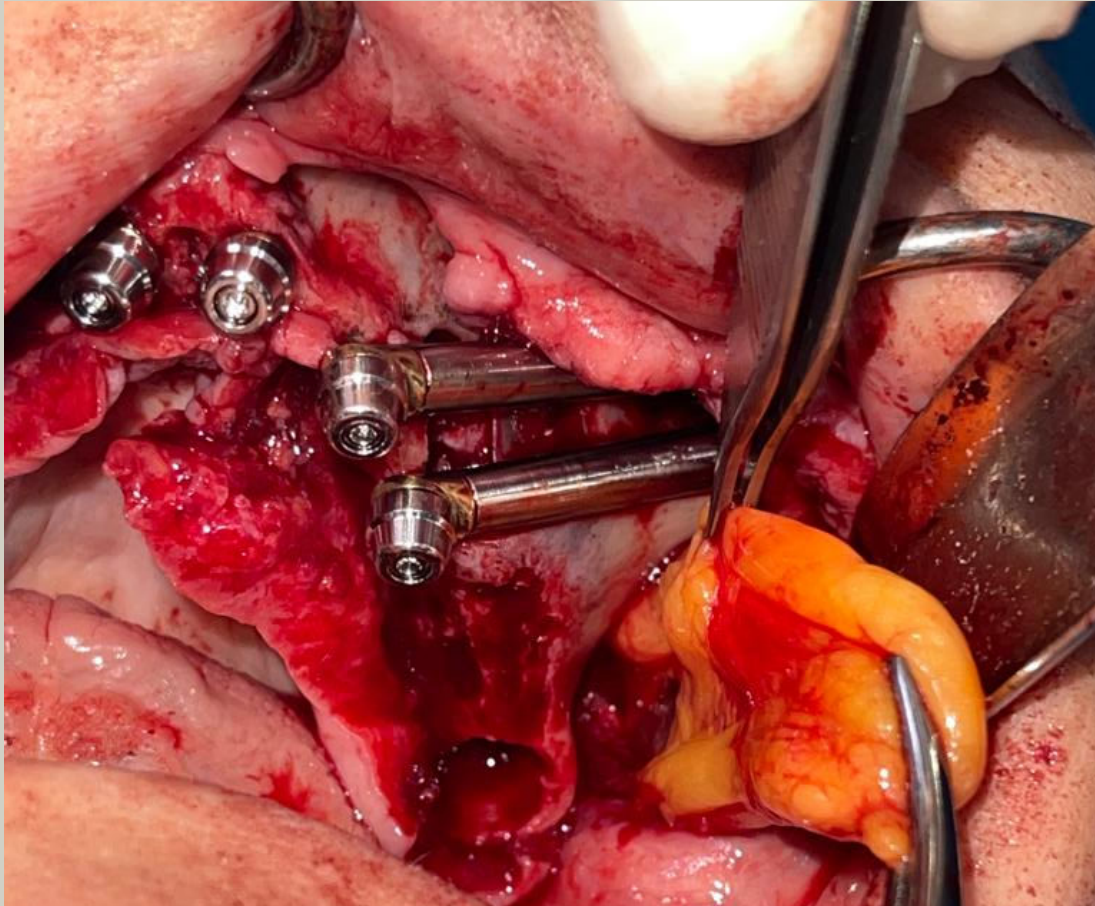


Cirugía

Vista global
quad-zygoma y
dos implantes
transnasales



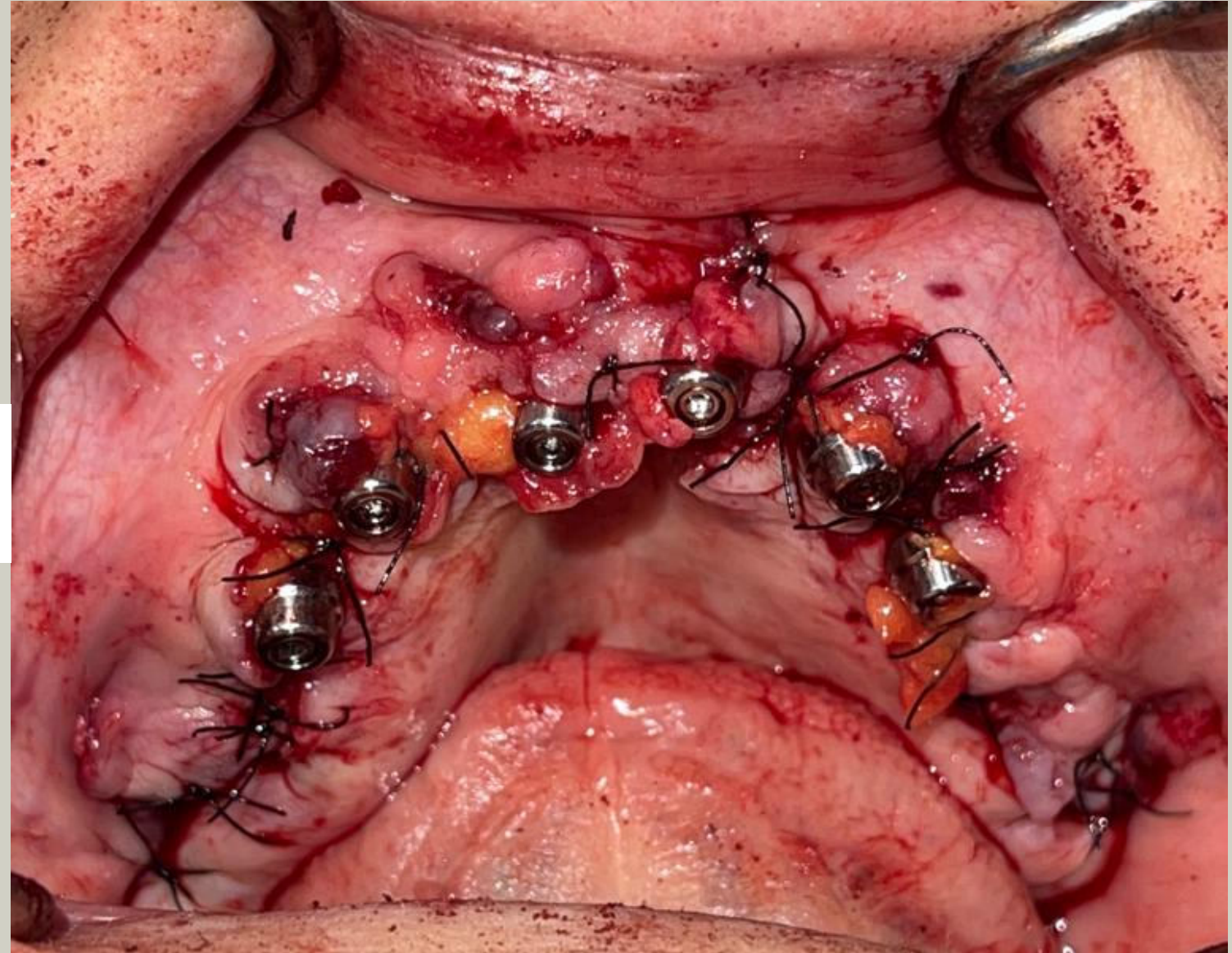
Cirugía



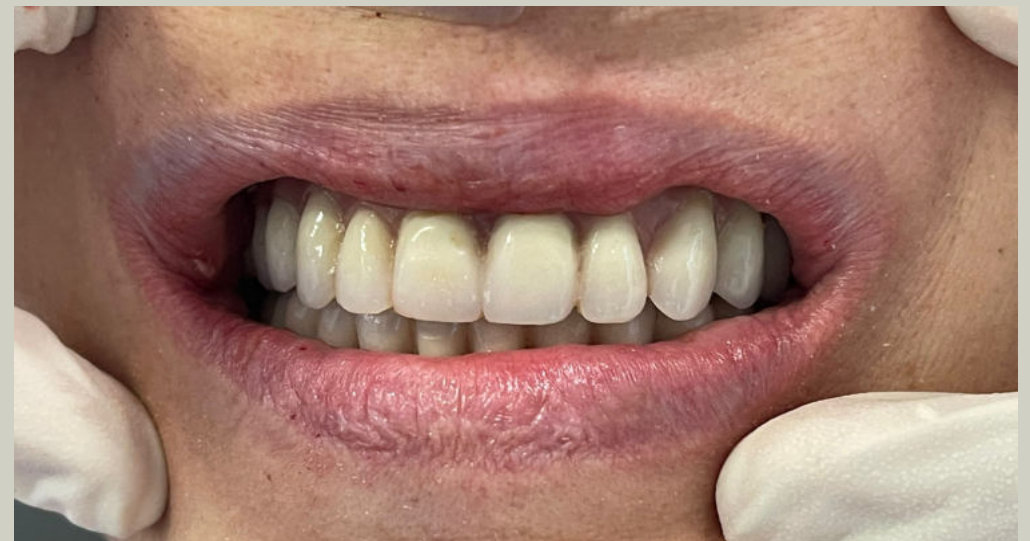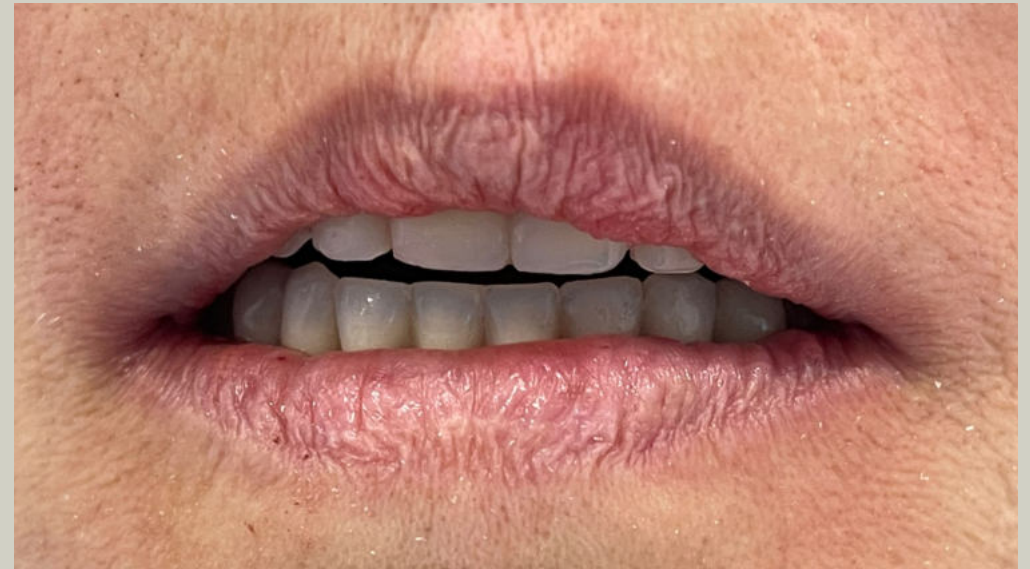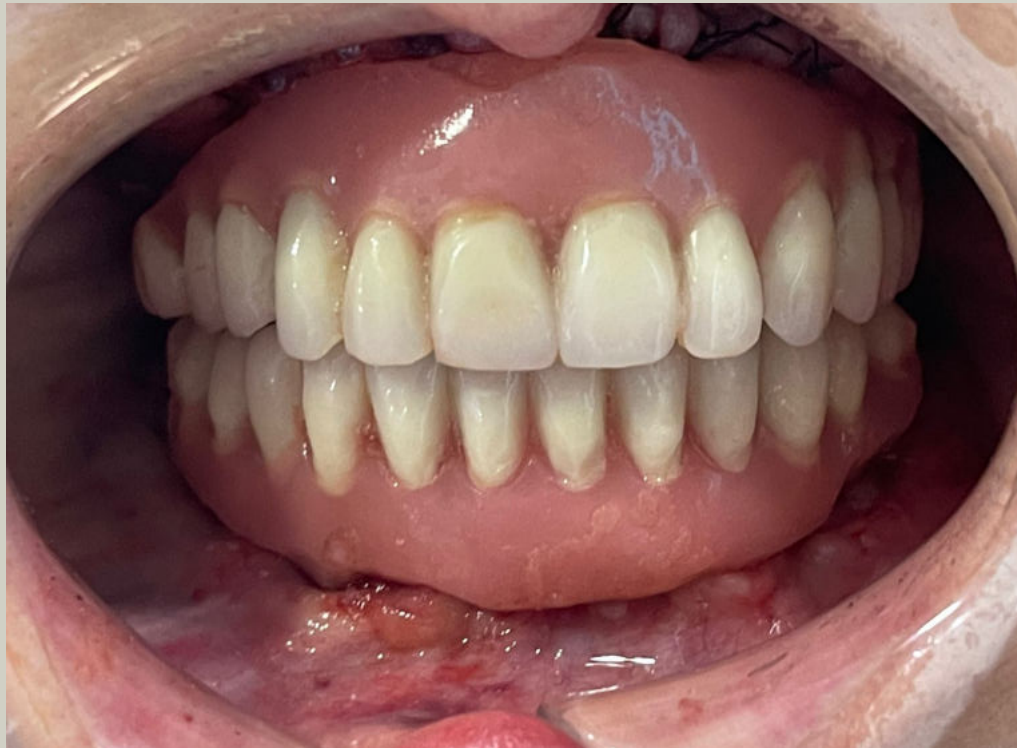Bola de bichat

Cirugía

Sutura antes de la colocación de la carga inmediata

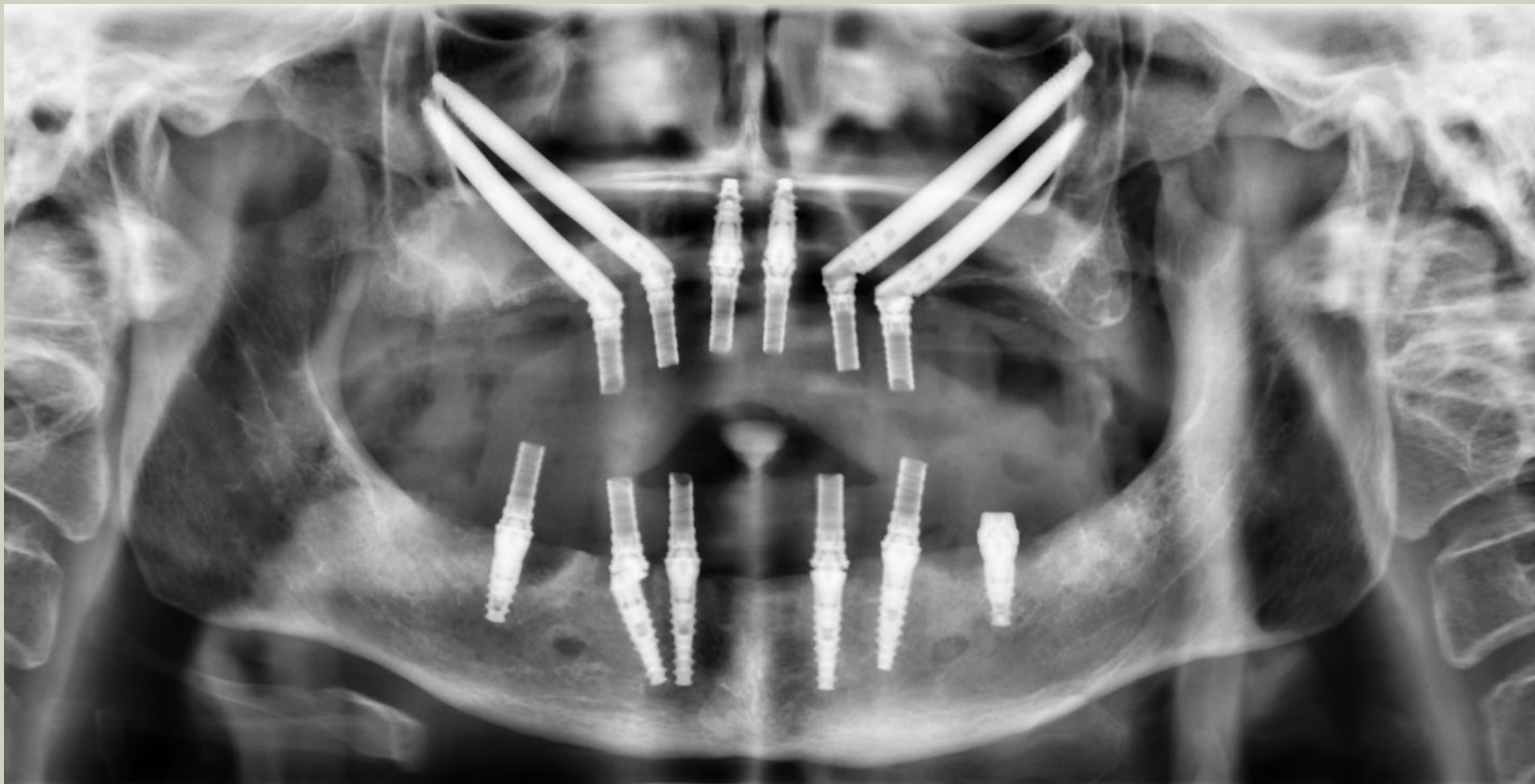


Prótesis provisional fija inmediata



Carga inmediata tras la cirugía

Radiografía



Radiografía

